

## PSOROPTIC MANGE IN A WAPITI

Authors: COLWELL, DAVID A., and DUNLAP, J. S.

Source: Journal of Wildlife Diseases, 11(1) : 66-67

Published By: Wildlife Disease Association

URL: <https://doi.org/10.7589/0090-3558-11.1.66>

---

The BioOne Digital Library (<https://bioone.org/>) provides worldwide distribution for more than 580 journals and eBooks from BioOne's community of over 150 nonprofit societies, research institutions, and university presses in the biological, ecological, and environmental sciences. The BioOne Digital Library encompasses the flagship aggregation BioOne Complete (<https://bioone.org/subscribe>), the BioOne Complete Archive (<https://bioone.org/archive>), and the BioOne eBooks program offerings ESA eBook Collection (<https://bioone.org/esa-ebooks>) and CSIRO Publishing BioSelect Collection (<https://bioone.org/csiro-ebooks>).

Your use of this PDF, the BioOne Digital Library, and all posted and associated content indicates your acceptance of BioOne's Terms of Use, available at [www.bioone.org/terms-of-use](http://www.bioone.org/terms-of-use).

Usage of BioOne Digital Library content is strictly limited to personal, educational, and non-commercial use. Commercial inquiries or rights and permissions requests should be directed to the individual publisher as copyright holder.

---

BioOne is an innovative nonprofit that sees sustainable scholarly publishing as an inherently collaborative enterprise connecting authors, nonprofit publishers, academic institutions, research libraries, and research funders in the common goal of maximizing access to critical research.

## PSOROPTIC MANGE IN A WAPITI

DAVID A. COLWELL and J. S. DUNLAP, Department of Veterinary Pathology,  
College of Veterinary Medicine, Washington State University, Pullman, Washington 99163, USA.

**Abstract:** In northern Idaho, a 10-year old wapiti (*Cervus canadensis nelsoni*) died showing signs of ataxia and alopecia. Examination of dermis revealed infestation with *Psoroptes equi* var. *cervinus*.

### INTRODUCTION

Psoroptic mange has been reported from wapiti on several occasions.<sup>3,4</sup> Young animals and calves apparently rarely show clinical signs of this infestation and in mature animals, bulls are more often affected than cows.<sup>4</sup> Age data for affected wapiti are lacking. To the best of our knowledge, the present paper represents the first report from Idaho.

### Case Report

A mature bull wapiti was observed on March 18, 1973 in the lower Lochsa River drainage in northern Idaho, showing signs of ataxia. When disturbed, he stumbled, fell, was unable to rise and expired within 2 hours.

The bull was extremely emaciated and marked alopecia was apparent over two-thirds of his body. The dorsal and lateral surfaces of the neck, body and upper legs were most severely involved. The integument was dry and crusty with excoriation of the neck and front legs over sites of flexion. Toward the margins of the areas of depilation, the hair was sparse and mixed with a yellowish exudate and detritus. Representative samples from these lesions were removed and examined under a dissecting microscope. Large numbers of adult (Fig. 1) and larval stages of *Psoroptes equi* var. *cervinus*<sup>1</sup> were seen. The parasites were most numerous in areas of active inflammation and along the proximal one-third of the remaining hair shafts.

By sectioning and hematoxylin staining of the first incisor and counting cementum annuli,<sup>2</sup> the animal was determined to be 10 years old. The dentition was excellent. It was impossible to discern whether the parasites were responsible for the debilitation or if their presence was secondary to some other condition. No histopathology was done. Epizootics of psoroptic mange have not been well documented and, therefore, it is difficult to assess the importance of this condition in the population dynamics of elk.

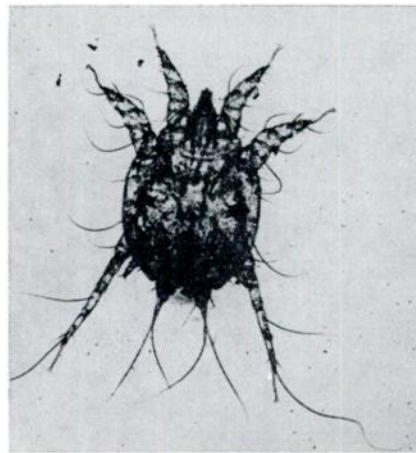


FIGURE 1. Adult *Psoroptes equi* var. *cervinus* from wapiti.

#### Acknowledgements

The authors wish to thank Mr. Mike Schlegel of the Idaho Fish and Game Department [Idaho Federal Aid Project W-160 (04-38-935)] for his assistance in collection and preparation of this material.

#### LITERATURE CITED

1. BAKER, E. W., T. M. EVANS, D. J. GOULD, W. B. HULL and H. L. KEEGAN. 1967. *A Manual of Parasitic Mites of Medical or Economic Importance*. Henry Tripp, Woodhaven, N.Y.
2. GILBERT, F. F. 1966. Aging white-tailed deer by annuli in the cementum of the first incisor. *J. Wildl. Mgmt* 30: 200-202.
3. HONESS, R. F. and K. B. WINTER. 1956. *Diseases of Wildlife in Wyoming*. Wyoming Game and Fish Commission.
4. MURIE, O. J. 1951. *The Elk of North America*. Harrisburg, PA, Stackpole Co., and Wildlife Management Inst.

*Received for publication 12 June 1974*