

CONGENITAL ANOMALIES IN A NEONATAL WHITE-TAILED DEER IN ALBERTA

Author: BARRETT, MORLEY W.

Source: Journal of Wildlife Diseases, 11(4) : 497-501

Published By: Wildlife Disease Association

URL: <https://doi.org/10.7589/0090-3558-11.4.497>

BioOne Complete (complete.BioOne.org) is a full-text database of 200 subscribed and open-access titles in the biological, ecological, and environmental sciences published by nonprofit societies, associations, museums, institutions, and presses.

Your use of this PDF, the BioOne Complete website, and all posted and associated content indicates your acceptance of BioOne's Terms of Use, available at www.bioone.org/terms-of-use.

Usage of BioOne Complete content is strictly limited to personal, educational, and non - commercial use. Commercial inquiries or rights and permissions requests should be directed to the individual publisher as copyright holder.

BioOne sees sustainable scholarly publishing as an inherently collaborative enterprise connecting authors, nonprofit publishers, academic institutions, research libraries, and research funders in the common goal of maximizing access to critical research.

CONGENITAL ANOMALIES IN A NEONATAL WHITE-TAILED DEER IN ALBERTA

MORLEY W. BARRETT,¹ Alberta Department of Lands and Forests, Fish and Wildlife Division, Lethbridge, Alberta T1H 0H5, Canada

GORDON A. CHALMERS, Alberta Department of Agriculture, Veterinary Services Division, Lethbridge, Alberta T1J 3Y5, Canada

Abstract: In September, 1973, a live male 2-3 day old white-tailed deer (*Odocoileus virginianus*) with multiple anomalies of the head and forelimbs was found near Lethbridge, Alberta. Notable gross findings included brachygnathia inferior, atypical incisor tooth alignment, medially folded ears, humero-radial arthrogryposis and bowing of the radius and ulna. Hematologic determinations indicated increased erythrocyte, hemoglobin and hematocrit levels. Histopathologic examination revealed mineralized spherites in the cerebellum and midbrain.

INTRODUCTION AND HISTORY

Reports of congenital defects in deer are uncommon and probably reflect the rapid disappearance of such animals from wild populations. Shave² described a 3 month old white-tailed deer fawn with hydrocephalus and Verme¹⁰ reported deformities of the hind limbs of two neonatal white-tailed deer. Wobeser and Runge¹² reported multiple anomalies in a fetal white-tailed deer but no similar description of live fawns has been reported.

On 12 September 1973, a live male white-tailed deer fawn, found in lateral recumbency approximately 40 km north of Lethbridge, Alberta was submitted for examination. This report describes multiple anomalies of the head and forelimbs.

MATERIALS AND METHODS

Standard measurements, heart and respiration rates and behavioral data were collected immediately. Blood was drawn

by jugular venipuncture into Vacutainer³ vials containing EDTA-K; all hematologic determinations were made within 24 h. Slides for differential white cell counts were prepared immediately and stained with Wright's Blood stain; 100 leukocytes were counted. Erythrocyte (RBC) and leukocyte (WBC) determinations were made on an electronic cell counter. Hemoglobin (Hb) was measured using the cyanmet spectrophotometric method. Hematocrit (Hct) was determined by the microhematocrit method. Mean corpuscular volume (MCV), mean corpuscular hemoglobin (MCH) and mean corpuscular hemoglobin concentration (MCHC) were calculated.

Tissues for histopathology were trimmed to 3 mm thickness, fixed in 10% neutral buffered formalin, processed routinely, cut at 6 μ m and stained with hematoxylin and eosin (H & E). Brain, spinal cord, heart, lung, liver, pancreas, kidney and adrenal gland were examined. Special stains included the Von Kossa and Perl's methods for calcium

¹ Presently, faculty of Graduate Studies and Research, Dept. of Zoology, Univ. of Alberta, Edmonton, Canada.

² SHAVE, H., M. E. BERGLAND and D. E. REED. 1974. Hydrocephalus in a white-tailed fawn. Presented 1974 Ann. Wildl. Dis. Conf., Pacific Grove, California. Manuscript.

³ Becton, Dickinson and Co., Canada Ltd., Mississauga, Ontario.

and iron, respectively. The fawn was euthanatized with an intravenous injection of Letal[®] and necropsied immediately. Radiographs of the skeleton were obtained. The right femur was sectioned longitudinally to inspect the marrow cavity.

RESULTS

Size and Behavior

The fawn remained in lateral recumbency but was able to maintain sternal recumbency if placed in that position; it could not stand. When stimulated, the animal could elicit only weak vocalizations which were seldom over 1 second in duration but were repeated every 6-8 seconds. The crown rump, hind foot, chest and total length measurements were 381, 210, 241, and 533 mm, respectively; the fawn weighed 1550 g. The umbilical stump was dry and severed near the abdomen. Age was estimated at 2-3 days.

Gross Pathology

The fawn had notably abnormal conformations of skull, ears, jaw, teeth, and front limbs (Fig. 1). The snout was foreshortened and there was a 1.6 cm brachygnathia inferior. Incisiform teeth had erupted but were misaligned; the I_2 teeth were located immediately posterior to the I_1 teeth. There was no evidence of cleft palate. Ears were permanently folded medially against the head and overlapped at the tips. Eyes were covered by a heavy film of gray mucus.

The forelimbs had bimelic humero-radial arthrogryposis and vertical projection of the metacarpi and digits. Carpal joints were readily flexed. Radiographs demonstrated a 180° sagittal bowing of the radius and ulna (Fig 2); there was no evidence of rotation. Dissection revealed two partially fused metacarpal bones, the medial of which appeared hypoplastic. In each limb only the lateral digit, with its three phalanges, hoof and

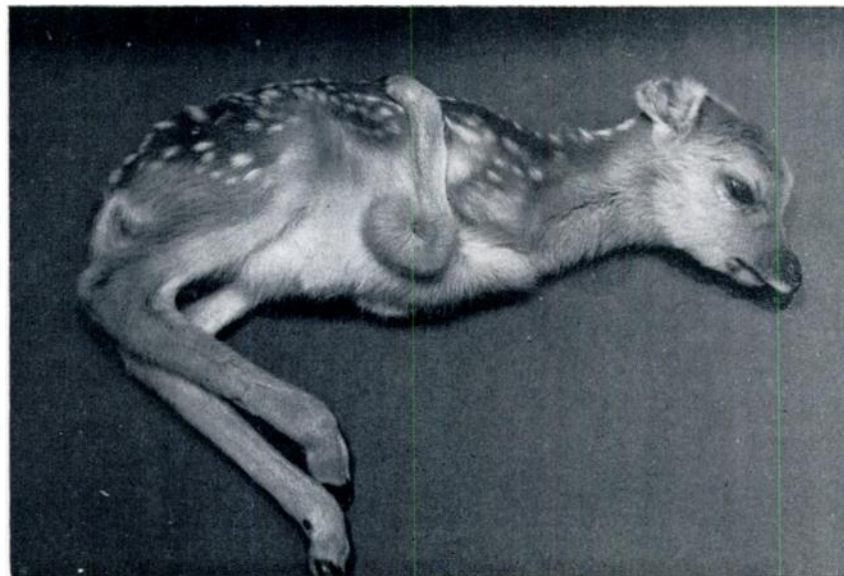


FIGURE 1. Lateral view of live, neonatal white-tailed deer fawn showing deformities of the head and forelimbs.

[[®]] Haver-Lockhart Laboratories, Calgary, Alberta.

associated dew claw, was complete. Only the first phalanx of the right medial digit was present; the left medial digit was absent.

Internal examination revealed no obvious abnormalities. There was adequate perirenal fat, but virtually no visible mesenteric or omental fat. Except for

hypostatic congestion of the left lung there were no grossly observable thoracic lesions. The forestomachs contained only a small volume of watery pale green fluid and the intestines, a small amount of mucus. There was no evidence the animal had suckled. Gross lesions of the brain and spinal cord were not observed. The sectioned right femur was unremarkable.

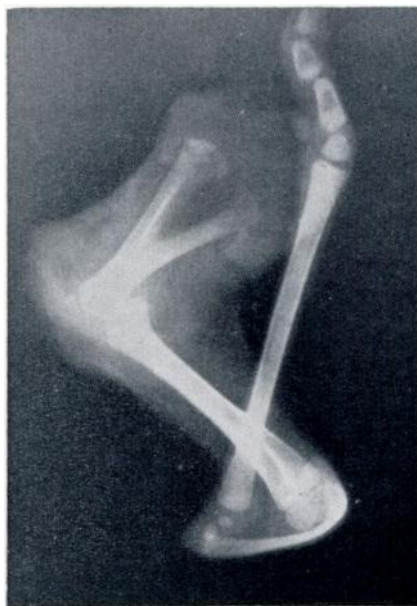

FIGURE 2. Radiograph of left forelimb showing 180° sagittal bowing of the radius and ulna, white-tailed deer fawn.

Physiologic Data

Respiration and pulse rates of the fawn were 62 and 180 per min., respectively; rectal temperature was 37.3 C. Differential WBC counts expressed as a percentage, revealed 50 lymphocytes, 36 segmented neutrophils, 1 monocyte, 12 eosinophils, and 1 basophil. Other hematologic parameters for which comparative data could be found are presented in Table 1.

Histopathology

Lesions were found only in the brain. Circular lakes of basophilic mineralized spherites measuring 25-90 μ m in diameter were observed in H & E stained sections of the cerebellum and occasionally in the mid-brain (Fig. 3). The morphology of some of the larger, less regular spherites suggested that two or more smaller structures had coalesced during formation. Many spherites had a distinct laminar appearance; special stains demonstrated heavy accumulations of iron and

TABLE 1. Some hematologic values comparing the deformed and normal neonatal white-tailed deer.

	Hct (%)	Hb (g/100 ml)	RBC ($10^6/\text{mm}^3$)	WBC ($10^3/\text{mm}^3$)	MCV (μ^3)	MCH ($\mu\mu\text{g}$)	MCHC (%)
Deformed Fawn	39	13.5	10.2	3.4	38.9	12.97	34.62
Michigan [†]	30.9	8.4	7.81	—	40.0	12.4	27.4
Missouri ^{*8}	29	8	7	3.8	40.2	12.3	28
Texas ¹¹	28	10.2	6.79	3.7	—	—	—

* Values derived from graphs.

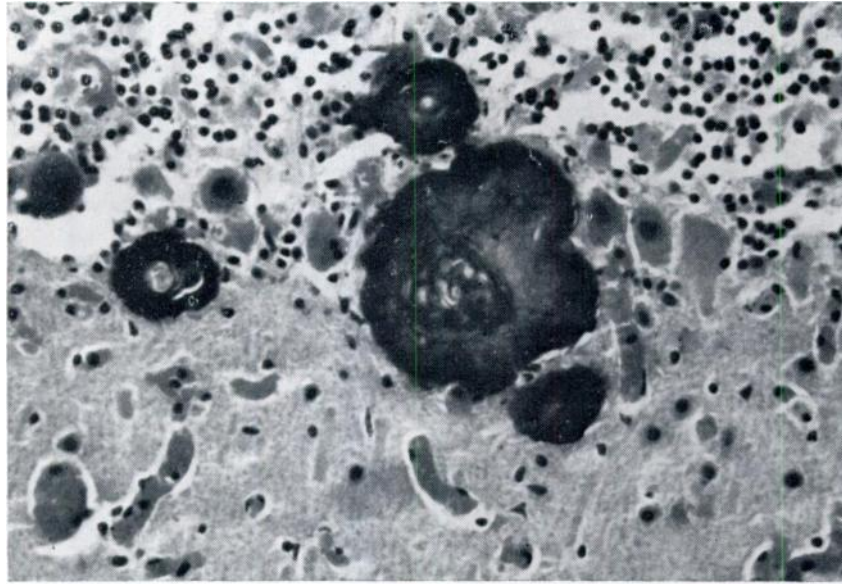


FIGURE 3. Mineralized spherites associated with the Purkinje cell layer of the cerebellum, white-tailed deer fawn, H & E X 314.

lesser concentrations of calcium. Occasionally, mineralized deposits were present in Purkinje cells in a ring or C form. Spherites in the cerebellum were located primarily in or closely adjacent to the Purkinje cell layer but were also seen in the granular and molecular layers. No vascular mineralization was observed.

DISCUSSION

The cause of the approximate 3 month delay in parturition is unknown. Verme⁹ reported that malnutrition in pregnant does can lengthen the gestation period by 4-6 days. Hall² has indicated that the breeding period for Alberta white-tailed deer fawns is usually 1 month later than for adults. However, neither explanation accounts satisfactorily for the September delivery date. The weight and measurements further complicate the problem by suggesting that the fawn was premature, as its size was comparable

to that of a 150 day white-tailed deer fetus.¹

The increased hematocrit, hemoglobin and erythrocyte values probably reflected dehydration resulting from the animal's inability to suckle. Because dehydration should similarly elevate the observed leukocyte total, the apparently normal value reported in Table 1 is probably exaggerated and suggested the animal was actually leukopenic. The remainder of the hematologic values appeared relatively normal with the exception of the elevated MCHC. Total and differential leukocyte counts did not suggest current infection.

Rectal temperature was 2.6 C lower than that reported for neonatal white-tailed deer fawns in Texas¹¹ and presumably reflected lack of nourishment, inactivity, and continued recumbency.

Many of the spherites observed in the cerebellum were suggestive of encrusted neurons, based on their consistent presence in or near the Purkinje cell layer.

It has been suggested that Purkinje cells are more sensitive than others to siderosis and may be replaced by lakes of such deposits.⁵ Lesions observed in the central nervous system of this fawn ap-

pear to be unique and bear only superficial resemblance to the mineralizations described in the brains of human infants⁶ and horses.^{3,7}

Acknowledgements

We wish to thank Dr. R. Bide, Canada Department of Agriculture, Health of Animals Branch, Lethbridge, Alberta for his assistance in conducting hematologic determinations and Mr. S. Pompu of the Alberta Department of Lands and Forests for bringing the fawn for examination.

LITERATURE CITED

1. ARMSTRONG, R. A. 1950. Fetal development of the northern white-tailed deer (*Odocoileus virginianus borealis* Miller). Am. Midl. Naturalist. 43: 650-666.
2. HALL, W. K. 1973. Natalty and mortality of white-tailed deer, (*Odocoileus virginianus dacotensis* Goldman and Kellogg) in Camp Wainwright, Alberta. M.Sc. thesis. Univ. of Calgary, Calgary, 117 pp.
3. HURST, E. W. 1934. Calcification in the brains of equidae and bovidae. Am. J. Path. 10: 795-798.
4. JOHNSON, H. E., W. G. YOUATT, L. D. FAY, H. D. HARTE and D. E. ULLREY. 1968. Hematological values of Michigan white-tailed deer. J. Mammal. 49: 749-754.
5. JUBB, K. V. F. and P. C. KENNEDY. 1970. Page 360 in *Pathology of Domestic Animals*. Vol. 1, 2nd ed. Academic Press, New York. 593 pp.
6. NORMAN, R. M. 1971. Malformations of the nervous system, birth injury and diseases of early life I. Prenatal malformations. Page 350 in *Greenfield's Neuropathology*, 2nd ed. Edward Arnold Ltd., London. 679 pp.
7. SAUNDERS, L. Z. 1953. Cerebrovascular siderosis in horses. Arch. Path. 56: 637-642.
8. TUMBLESON, M. R., J. D. CUNEIO and D. A. MURPHY. 1970. Serum biochemical and hematological parameters of captive white-tailed fawns. Can. J. Comp. Med. 34: 66-71.
9. VERME, L. J. 1965. Reproduction studies on penned white-tailed deer. J. Wildl. Manage. 29: 74-79.
10. ———. 1968. Possible hereditary defects in Michigan white-tailed deer. J. Mammal. 49: 148.
11. WHITE, M. and R. S. COOK. 1974. Blood characteristics of free-ranging white-tailed deer in southern Texas. J. Wildl. Dis. 10: 18-24.
12. WOBESER, G. and W. RUNGE. 1973. Multiple anomalies in a white-tailed deer fetus. J. Wildl. Dis. 9: 356-358.

Received for publication 10 September 1974