

CHOLELITHIASIS IN THE COTTONRAT, *Sigmodon hispidus*, FROM THE HIGH PLAINS OF TEXAS

Authors: PENCE, D. B., MOLLHAGEN, T., and SWINDLE, B.

Source: Journal of Wildlife Diseases, 14(2) : 208-211

Published By: Wildlife Disease Association

URL: <https://doi.org/10.7589/0090-3558-14.2.208>

The BioOne Digital Library (<https://bioone.org/>) provides worldwide distribution for more than 580 journals and eBooks from BioOne's community of over 150 nonprofit societies, research institutions, and university presses in the biological, ecological, and environmental sciences. The BioOne Digital Library encompasses the flagship aggregation BioOne Complete (<https://bioone.org/subscribe>), the BioOne Complete Archive (<https://bioone.org/archive>), and the BioOne eBooks program offerings ESA eBook Collection (<https://bioone.org/esa-ebooks>) and CSIRO Publishing BioSelect Collection (<https://bioone.org/csiro-ebooks>).

Your use of this PDF, the BioOne Digital Library, and all posted and associated content indicates your acceptance of BioOne's Terms of Use, available at www.bioone.org/terms-of-use.

Usage of BioOne Digital Library content is strictly limited to personal, educational, and non-commercial use. Commercial inquiries or rights and permissions requests should be directed to the individual publisher as copyright holder.

BioOne is an innovative nonprofit that sees sustainable scholarly publishing as an inherently collaborative enterprise connecting authors, nonprofit publishers, academic institutions, research libraries, and research funders in the common goal of maximizing access to critical research.

CHOLELITHIASIS IN THE COTTONRAT, *Sigmodon hispidus*, FROM THE HIGH PLAINS OF TEXAS

D. B. PENCE, T. MOLLHAGEN and B. SWINDLE, Department of Pathology, Divisions of Comparative and Clinical Pathology, Texas Tech University Health Sciences Centers, Lubbock, Texas 79409, USA.

Abstract: A high prevalence (71%) of gallstones was noted in free-ranging cottonrats, *Sigmodon hispidus*, collected from one site in Lubbock County, Texas. The gallbladder of affected animals was distended and filled with white, soft, friable, cholesterol gallstones of variable sizes. Focal hyperplasia of the epithelium and connective tissue layer of the gallbladder was evident in affected cottonrats. As the forage available to affected animals was different from that available to gallstone-free animals collected from other areas, this may be the cause of the higher prevalence of cholelithiasis in this population. The significance of this disease and possible use of the cottonrat as an experimental model are discussed.

INTRODUCTION

During a study of helminth parasitism of the hispid cottonrat, *Sigmodon hispidus*, gallstones were found in cottonrats collected from two xeric localities in Lubbock County, Texas. Animals examined from three other localities were unaffected. The following case report is a study of the prevalence and pathologic changes associated with cholelithiasis in these populations.

MATERIALS AND METHODS

One hundred and twenty-eight cottonrats were collected from 4 localities (2 xeric and 2 mesic areas) in Lubbock County, Texas and another xeric locality in the Davis Mountains, Brewster County, Texas. Specimens were snap-trapped or live-trapped and later killed. All animals were in fair to good condition and were aged by weight as either subadult or adult. Male and female weights were 68.8 to 132.5g (\bar{X} = 102.2) and 54.4 to

108.5g (\bar{X} = 79.1), respectively. The gallbladders and portions of liver, aorta kidney and pancreas were fixed in buffered 10% formalin. Paraffin embedded tissue sections were cut at 4-6 μ m and stained with hematoxylin and eosin. Gallstones removed from 3 animals were washed and dissolved in methanol. These were analyzed for cholesterol with Lieberman-Burkhart reagent.^[1] Magnesium and calcium were analyzed by atomic absorption^[2] and sodium and potassium were quantified by flame emission,^[3] respectively. Analysis for bilirubin was with the diazo reaction.^[4] Sulfates were examined by barium precipitation.^[5]

RESULTS

Gallstones were observed in 1 of 25 (4%) specimens collected in January, 1977 from the Texas Tech University farm within the city limits of Lubbock, Texas and in 25 of 35 (71%) cottonrats, collected approximately 4 km S, 4 km E from

[1] Hycel Inc., Houston, Texas

[2] IL 453 atomic absorber. Instrumentation Laboratory Inc., Lexington, Massachusetts

[3] IL 343 flame photometer. Instrumentation Laboratory Inc., Lexington, Massachusetts

[4] Dow Chemical Co., Indianapolis, Indiana

Shallowater, Lubbock County, from February through April, 1977. Gallstones were not observed in 68 animals from the remaining 3 collecting sites. These included 29 collected in February, 1977 near Slaton (4 km N, 1 km E of Lubbock), 15 trapped in February, 1977 from the V-8 Ranch (5 km S, 10 km E of Lubbock) and 21 collected in March, 1977 near Alpine, Brewster County (10 km N, 3 km W of Alpine).

Animals with gallstones from the Shallowater population ranged in weight from 54.4 to 132.5 g (\bar{X} = 90.4). Unaffected animals weighed 62.9 to 129.5 g (\bar{X} = 95.4). Thus, both subadults and adults were affected. Chi-square analysis⁶ indicated no significant difference ($P > 0.05$, 1df) between adults and subadults in prevalence of gallstones. Eleven of 18 (61%) males and 14 of 17 (82%) females had cholelithiasis. Chi-square analysis indicated no significant difference ($P > 0.05$, 1df) between male and female cottonrats in prevalence of gallstones.

The gallbladder of affected animals was distended with bile and usually filled with white gallstones (Fig. 1). These ranged in number from 2 to more than 20, and in size from almost too small to see to over 1 mm in diameter. The bile was of similar color and consistency to that in unaffected animals. Gallstones were smooth or had an eggshell-like surface. They were friable and on transection had a radial crystalline pattern. The center of larger stones was yellow in color and often had a gelatinous consistency. Enzymatic assay with Lieberman-Burkhart reagent of a pooled sample of gallstones from 3 animals revealed 78% cholesterol. There was no evidence of magnesium, calcium, sodium, potassium, sulfates, or bilirubin according to methods used in this study. Since the remainder of the material appeared to be cellular in origin when examined microscopically, these stones consisted largely of cholesterol.

Histologically, the wall of the gallbladder was considerably thickened in

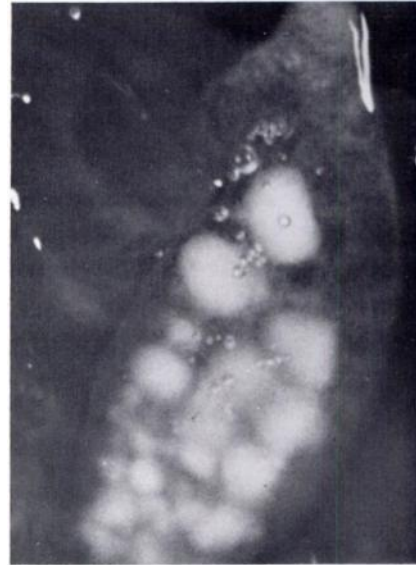


FIGURE 1. Cottonrat gallbladder with cholesterol gallstones.

cottonrats with gallstones. There was hyperplasia of connective tissue and increased vascularization of the lamina propria and connective tissue layer of the bladder wall. Small foci of hyperplasia of the cuboidal epithelium of the mucosa often extended as polypoid infoldings into the lumen (Fig. 2). Occasionally, cuboidal epithelial cells had undergone metaplasia to columnar epithelium within these foci of hyperplasia. Similar areas of hyperplasia of columnar epithelial cells were noted in the common bile duct. In unaffected animals the entire gallbladder mucosa consisted of a single sheet of cuboidal epithelium with a thin layer of submucosal connective tissue. Pathologic changes due to cholelithiasis were not observed in tissue sections of liver, kidney, pancreas or aorta.

DISCUSSION

Gallstones were noted only in cottonrats from 2 of 5 collecting sites. The

three areas where cottonrats were free of gallstones, as well as the site where only a single cottonrat was affected, were rangelands dominated by perennial grasses. The collecting site where animals had the highest prevalence of cholelithiasis was a railroad cut bordering cultivated fields. Vegetation at this locality was sparse and consisted largely of annual forbs and grasses. The stomach of animals snap-trapped at this site usually was distended with coarse dried plant material (stems, roots, leaves). The stomach of animals collected elsewhere usually was partially filled with green forbs and other living plant material.

Gallstones have been induced experimentally in several rodents, including laboratory mice, guinea pigs, hamsters, ground squirrels and prairie dogs.^{1,5} In hamsters, cholesterol gallstones can be produced in 80 to 100% of animals maintained on a fat-free diet containing an easily absorbable sugar such as glucose.¹ Cholelithiasis has been produced in prairie dogs fed a diet high in cholesterol.² Confirmation that the diet is responsible for gallstone production in cottonrats must await analysis of the plant material on which these animals were feeding and experimental dietary studies.

Cholesterol gallstones experimentally induced in hamsters are more common in males than in females and in younger animals.¹ Although the prevalence of gallstones was not significantly different between sexes in the present study, the sample size was limited. Likewise, there was no correlation between age and gallstone formation.

The significance of cholelithiasis for cottonrats from this area appears to be minimal. While histologic changes were evident in the mucosa and connective

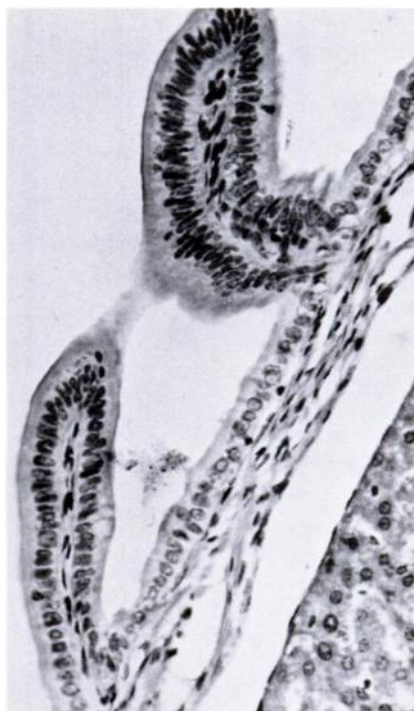


FIGURE 2. Section of gallbladder wall with polypoid areas of focal hyperplasia of mucosa. H & E. $\times 160$.

tissue layer of the gallbladder, there was no evidence of blockage of the common duct, stasis of bile or other more serious conditions.

Since at least 10% of the human population in the United States is estimated to have gallstones and more than 85% of these gallstones are composed predominantly of cholesterol,⁴ the cottonrat could provide an experimental model for research on cholelithiasis. This species is easily reared and maintained in the laboratory; moreover, several laboratory strains presently are available.

Acknowledgements

We appreciate the technical assistance of Linda Jones. This study was supported in part by funds from The Institute of Museum Research, The Museum of Texas Tech

University and in part by funds from the Department of Pathology, Texas Tech University Health Sciences Centers to the senior author.

LITERATURE CITED

1. DAM, H. 1969. Nutritional aspects of gallstone formation with particular reference to alimentary production of gallstones in laboratory animals. *World Rev. Nut. Diet.* 11: 199-239.
2. DENBESTEN, L., S. SAFAIE-SHIRAZI, W.E. CONNER and S. BELL. 1974. Early changes in bile composition and gallstone formation induced by a high cholesterol diet in prairie dogs. *Gastroenterology* 66: 1036-1045.
3. FRITZ, J.S. and G.H. SCHENK, Jr. 1973. *Quantative Analytical Chemistry*. 2nd ed. Allyn and Bacon Publ. Co. London, 660 pp.
4. INGELFINGER, F.J. 1968 Digestive disease as a national problem. V. Gallstones. *Gastroenterology* 55: 102-104.
5. PATTON, D.E., K. PLOTNER, G.E. COX and C.B. TAYLOR. 1961. Biliary cholesterol deposits in ground squirrels and prairie dogs. *Fed. Proc.* 20: 248.
6. SOKAL, R.R. and F.J. ROHLF. 1969. *Biometry*. W.H. Freeman and Co., San Francisco, 776 pp.

Received for publication 12 September 1977