

THE HISTOPATHOLOGY AND PREVALENCE OF *Henneguya sebasta* AND *Kudoa clupei* IN THE ROCKFISH, *Sebastes paucispinis* OF SOUTHERN CALIFORNIA

Authors: HECKMANN, RICHARD A., and JENSEN, LAURITZ A.

Source: Journal of Wildlife Diseases, 14(2) : 259-262

Published By: Wildlife Disease Association

URL: <https://doi.org/10.7589/0090-3558-14.2.259>

The BioOne Digital Library (<https://bioone.org/>) provides worldwide distribution for more than 580 journals and eBooks from BioOne's community of over 150 nonprofit societies, research institutions, and university presses in the biological, ecological, and environmental sciences. The BioOne Digital Library encompasses the flagship aggregation BioOne Complete (<https://bioone.org/subscribe>), the BioOne Complete Archive (<https://bioone.org/archive>), and the BioOne eBooks program offerings ESA eBook Collection (<https://bioone.org/esa-ebooks>) and CSIRO Publishing BioSelect Collection (<https://bioone.org/csiro-ebooks>).

Your use of this PDF, the BioOne Digital Library, and all posted and associated content indicates your acceptance of BioOne's Terms of Use, available at www.bioone.org/terms-of-use.

Usage of BioOne Digital Library content is strictly limited to personal, educational, and non-commercial use. Commercial inquiries or rights and permissions requests should be directed to the individual publisher as copyright holder.

BioOne is an innovative nonprofit that sees sustainable scholarly publishing as an inherently collaborative enterprise connecting authors, nonprofit publishers, academic institutions, research libraries, and research funders in the common goal of maximizing access to critical research.

THE HISTOPATHOLOGY AND PREVALENCE OF *Henneguya sebasta* AND *Kudoa clupei* IN THE ROCKFISH, *Sebastes paucispinis* OF SOUTHERN CALIFORNIA

RICHARD A. HECKMANN and LAURITZ A. JENSEN, Department of Zoology, Brigham Young University, Provo, Utah 84602, USA and 17639 Clymer Street, Granada Hills, California 91344, USA.

Abstract: The pathogenesis of two histozoic myxosporidians, *Henneguya sebasta* and *Kudoa clupei*, was studied from the Pacific rockfish, *Sebastes paucispinis*. Infection of the bulbus and truncus arteriosus with *H. sebasta* was observed in 30 of 100 fish. The parasite metastasized throughout the tissue causing necrosis, hyperplasia and hypertrophy of the connective tissue and smooth muscle. *K. clupei*, found in 37 of 100 fish, caused necrosis and atrophy of host skeletal muscle. The unattractive appearance of *Kudoa* cysts in rockfish filets detracted from their commercial value.

INTRODUCTION

Tissue-invading myxosporidians are some of the most destructive and injurious protozoans found in fresh water and marine fishes.⁸ Two histozoic forms, *Henneguya sebasta* and *Kudoa clupei*, are common in California rockfishes.^{4,5} *H. sebasta* is found in the bulbus and truncus arteriosus, while *K. clupei* localizes in skeletal muscle. The histozoic habit of these parasites suggests pathogenicity, but to date precise histologic and physiologic evidence of disease are limited. Recently, Meyers *et al.*³ described the effect of *Henneguya* sp. on the bulbus and truncus arteriosus of the bluefish, *Pomatomus saltatrix*. Rogers and Gaines⁷ summarized known research on the lesions caused by protozoan parasites in fish. *K. clupei* and *H. sebasta* were not included in the review. Recently the histopathology and histogenesis of a related myxosporidan, *Henneguya exilis* was described in catfish.^{1,2} This paper describes the histozoic nature and prevalence of the two myxosporidians in the rockfish, *Sebastes paucispinis*, and emphasizes the histopathology of the infection.

MATERIALS AND METHODS

One hundred fish obtained from commercial and sport fishermen were fileted and the muscles were examined for protozoan cysts. The heart and aorta were examined for abnormalities. Infected tissue was processed by standard histological techniques, cut in serial sections 3 to 5 μ m thick, and stained with Mallory's triple trichrome stain and hemotoxylin and eosin. *Kudoa* and *Henneguya* spores isolated from the tissues were stained with Grams and Giemsa's stains, respectively.

RESULTS

Henneguya sebasta

Fish infected with *H. sebasta* had gross enlargements on the bulbus and truncus arteriosus (Fig. 1). Tissue sections of these enlargements showed a marked hypertrophy with numerous spores present in the infected areas. The parasite appeared to have the ability to metastasize throughout the three tissue layers of the bulbus or truncus arteriosus.

Smooth muscle frequently shows necrosis, pyknosis, and some hyper-

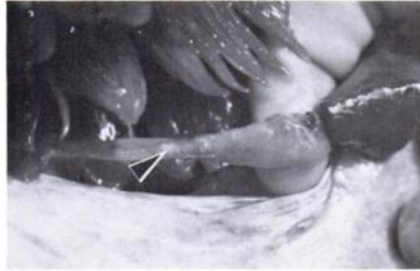

FIGURE 1. *Henneguya sebasta*, macroscopic observation of an infected bulb and truncus arteriosus with gross enlargement and mass of parasites (arrow).

plasia and hypertrophy (Fig. 2). Proliferation of connective tissue is evident near the parasite, but no fibrous encapsulation of the myxosporidan by the host was observed. Of 100 rockfish examined, 30 were positive for the parasite. Larger rockfish, over 60 cm long, had a higher prevalence of the disease (10 of 20 fish).

*Kudoa clupei*dae

Cysts of *Kudoa clupei*dae in the rockfish usually are elongated, oval structures measuring 7 to 22 mm by 1 to 5 mm in diameter (Fig. 3). They are most frequently situated in the skeletal muscle, either horizontal or diagonal to the integument. Occasionally, deep inter-muscular cysts were observed. Of 100



FIGURE 3. *Kudoa clupei*dae, cyst in muscle filet.

rockfish examined, 37 were infected with *Kudoa*. Ruptured cysts were filled with a thick, creamy substance. Contents of the cysts, however, are primarily *Kudoa* spores. The developmental sequence of cyst formation, determined by the serial sections, begins with the atrophy and necrosis of the endomysium surrounding individual muscle fibers. This is followed by intramyofibril invasion by the parasite, resulting in necrosis (Fig. 4). Asexual division increases the number of myxosporidians in the infected area and the cyst becomes encapsulated (Fig. 5). The later phase is characterized by tissue necrosis, severe atrophy (Fig. 5), some hypertrophy and presence of pyknotic nuclei. There was no evidence of chronic inflammation within the infected tissue. The host eventually isolates the spores

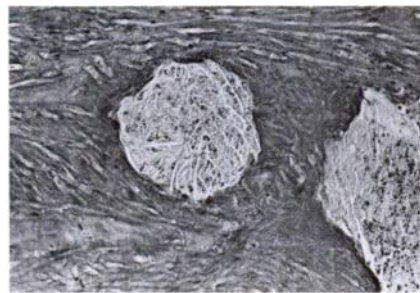


FIGURE 2. *Henneguya sebasta*, destruction of smooth muscle due to myxosporidan with no cyst encapsulation.

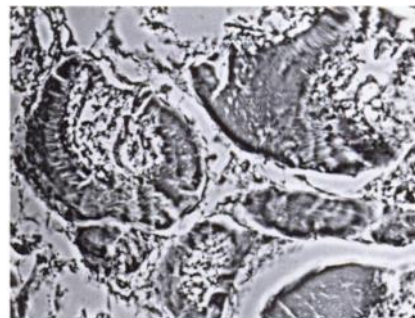


FIGURE 4. *Kudoa clupei*dae, marked necrosis of skeletal muscle.

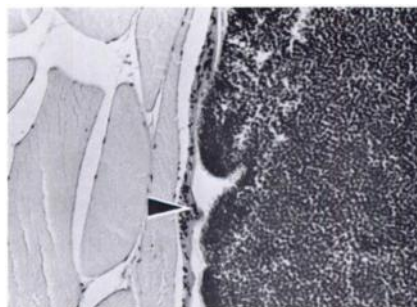


FIGURE 5. *Kudoa clupeiidae*, encapsulated cyst. Note capsule wall (arrow).

within a connective tissue capsule of collagenous fibers and fibroblasts (Fig. 5).

DISCUSSION

One of the more remarkable characteristics of *H. sebasta* is its ability to metastasize throughout the tunica adventitia and tunica interna layers of the bulb and truncus arteriosus near the heart. *H. sebasta* apparently has the ability to destroy smooth muscle (Fig. 2) and connective tissue of the bulb and truncus arteriosus. At no time does the host encapsulate the parasite. *Henneguya* probably lyses these tissues, which might weaken and eventually rup-

ture the aorta and adjoining vessels. Since the disease seems to be more obvious in older fish, the host quite possibly survives the infection.

Cysts of *K. clupeiidae* in rockfish filets are quite obvious to the average sportsman and fish market customer. Pus exuding from the ruptured cyst is unappetizing and, thus, heavily infected fish usually are discarded. To cope with customer complaints, the owner of a Southern California fish market coined the term "flavor buds" to describe these unappealing objects.

Myxosporidian parasites reportedly cause mushiness, milkiness or a softening of the flesh in many species of fishes.⁸ Patashnik and Groninger⁶ reported proteolytic enzyme activity of *Kudoa* sp. from several Pacific fishes. The proteolytic activity of *K. clupeiidae* apparently is responsible for the extensive necrosis of the muscle fibers in *S. paucispinis*. Nevertheless, liquefaction of refrigerated rockfish filets is not common in Southern California.

Complete encapsulation of *Kudoa* suggests that the spores are released upon the death of the host. A question suggesting further research is whether commercial and sport fishermen are significantly perpetuating the life cycle of *K. clupeiidae* by disposing spent rockfish carcasses in the ocean.

Acknowledgements

We wish to thank Mark Ridgway and Wayne Caywood of Malibu Seafood for providing the fish. Thanks are due to Craig Breinholt for sectioning the tissues.

LITERATURE CITED

1. CURRENT, W.L. and J. JANOVY. 1976. Ultrastructure of interlamellar *Henneguya exilis* in the channel catfish. *J. Parasit.* 62: 975-981.
2. McCrAREN, J.P., M.L. LANDOLT, G.L. HOFFMAN and F.P. MEYER. 1975. Variation in response of channel catfish to *Henneguya* sp. Infections (Protozoa, Myxosporidea). *J. Wildl. Dis.* 11: 2-7.
3. MEYERS, T.R., T.K. SAWYER, and S.A. MacLEAN. 1977. *Henneguya* sp. (Cnidospora: Myxosporida) parasitic in the heart of the bluefish, *Pomatomus saltatrix*. *J. Parasit.* 63: 890-896.

4. MOSER, M. and M.S. LOVE. 1975. *Henneguya sebasta* sp. n. (Protozoa, Myxosporida) from California rockfish, *Sebastes* spp. J. Parasit. 61: 481-483.
5. ———, ——— and L.A. JENSEN. 1976. Myxosporida (Protozoa) in California rockfish, *Sebastes* spp. J. Parasit. 62: 690-692.
6. PATASHNIK, M. and H.S. GRONINGER. 1964. Observations on the milky conditions in some Pacific coast fishes. J. Fish. Res. Bio. Canada 21: 335-346.
7. ROGERS, W.A. and J.L. GAINES, Jr. 1975. Lesions of protozoan diseases in fish. In: *The Pathology of Fishes*. Ed. by W.E. Ribelin and G. Migaki. University of Wisconsin Press. 117-141.
8. SINDERMAN, C.J. 1970. *Principal Diseases of Marine Fish and Shellfish*. Academic Press, New York, 369 pp.

Received for publication 4 February 1977
