

OSTEOARTHRITIS IN A COYOTE X DOG HYBRID FROM NEBRASKA

Authors: MAHAN, B. R., and GIPSON, P. S.

Source: Journal of Wildlife Diseases, 14(3) : 395-398

Published By: Wildlife Disease Association

URL: <https://doi.org/10.7589/0090-3558-14.3.395>

The BioOne Digital Library (<https://bioone.org/>) provides worldwide distribution for more than 580 journals and eBooks from BioOne's community of over 150 nonprofit societies, research institutions, and university presses in the biological, ecological, and environmental sciences. The BioOne Digital Library encompasses the flagship aggregation BioOne Complete (<https://bioone.org/subscribe>), the BioOne Complete Archive (<https://bioone.org/archive>), and the BioOne eBooks program offerings ESA eBook Collection (<https://bioone.org/esa-ebooks>) and CSIRO Publishing BioSelect Collection (<https://bioone.org/csiro-ebooks>).

Your use of this PDF, the BioOne Digital Library, and all posted and associated content indicates your acceptance of BioOne's Terms of Use, available at www.bioone.org/terms-of-use.

Usage of BioOne Digital Library content is strictly limited to personal, educational, and non-commercial use. Commercial inquiries or rights and permissions requests should be directed to the individual publisher as copyright holder.

BioOne is an innovative nonprofit that sees sustainable scholarly publishing as an inherently collaborative enterprise connecting authors, nonprofit publishers, academic institutions, research libraries, and research funders in the common goal of maximizing access to critical research.

OSTEOARTHROSIS IN A COYOTE X DOG HYBRID FROM NEBRASKA

B. R. MAHAN, University of Nebraska State Museum and School of Life Sciences, University of Nebraska, Lincoln, Nebraska 68588, USA.

P. S. GIPSON, Alaska Cooperative Wildlife Research Unit, U.S. Fish and Wildlife Service, University of Alaska, Fairbanks, Alaska 99701, USA.

Abstract: Osteoarthritis is described in a wild, 14-year-old coyote (*Canis latrans*) x dog (*C. familiaris*) hybrid shot in southeastern Nebraska. There was ankylosis of five vertebrae, the head of the left femur was absent, and periarticular osteophytes occurred throughout the skeleton. The age is significant because wild coyotes seldom live beyond 6 years and coyote x dog hybrids are considered to be less fit for survival in the wild than coyotes.

CASE REPORT

Arthritis, more properly osteoarthritis or degenerative arthropathy, is seldom reported in wild canids, although it is common among dogs (*Canis familiaris*).^{1,13} Coyotes (*Canis latrans*) rarely live long enough to develop problems of old age.⁶ Cross² described arthritic conditions in two wolves (*C. lupus*) being prepared as museum material, but Fox⁵ found no incidences of the disease among a considerable number of canid skeletons from various museums.

On 27 January 1976, a male canid suspected to be a coyote x dog hybrid was obtained from a fur buyer in Johnson County, Nebraska. Statistical analysis of cranial measurements indicated that the animal was a hybrid.⁹ Crowns of only 22 teeth from the normal complement of 42 remained,⁶ and all were extremely worn, with the pulp cavity exposed on most. The left molar/1 was broken or worn so that it appeared as two separate teeth (Fig. 1). The skull was similar to the one illustrated in Young and Jackson's¹⁴ *The Clever Coyote* (p. 65, Plate 13d), except the hybrid skull still had peg-like lower canines. Cranial sutures were barely visible because of almost complete fusion.

The animal had only one testicle and a misshapen baculum; the left femorotibial (knee) joint was twice as large as the right (Fig. 2d). After preparation of the skeleton, periarticular osteophytes were found about most of the synovial joints, including the left temporomandibular joint. The largest osteophytes were on the sternum (Fig. 2a), heads of nine ribs (Fig. 2b), the left hind leg joints, the right hind foot, and both anterior and posterior rims of some vertebrae. Osteophytes were evident on the 4th-7th cervical, the 1st-10th, 12th-13th thoracic, and the 2nd-7th lumbar vertebrae. Ankylosis occurred between the 1st/2nd, 3rd/4th, 10th/11th thoracic, 6th/7th lumbar, and 4th/5th coccygeal vertebrae.

The most extensive osteophyte formation occurred at the left coxofemoral (hip) and knee joints (Fig. 2c and d). The head of the left femur was absent probably making any leg movement extremely painful. The right hind foot was more severely affected than was the left (Fig. 3), and may have been in a steel trap at one time. Animals frequently bite the steel trap in an effort to free themselves, resulting in breaking or chipping of teeth. The hybrid's canines were broken and then heavily worn, suggesting that such breakage occurred early in life.

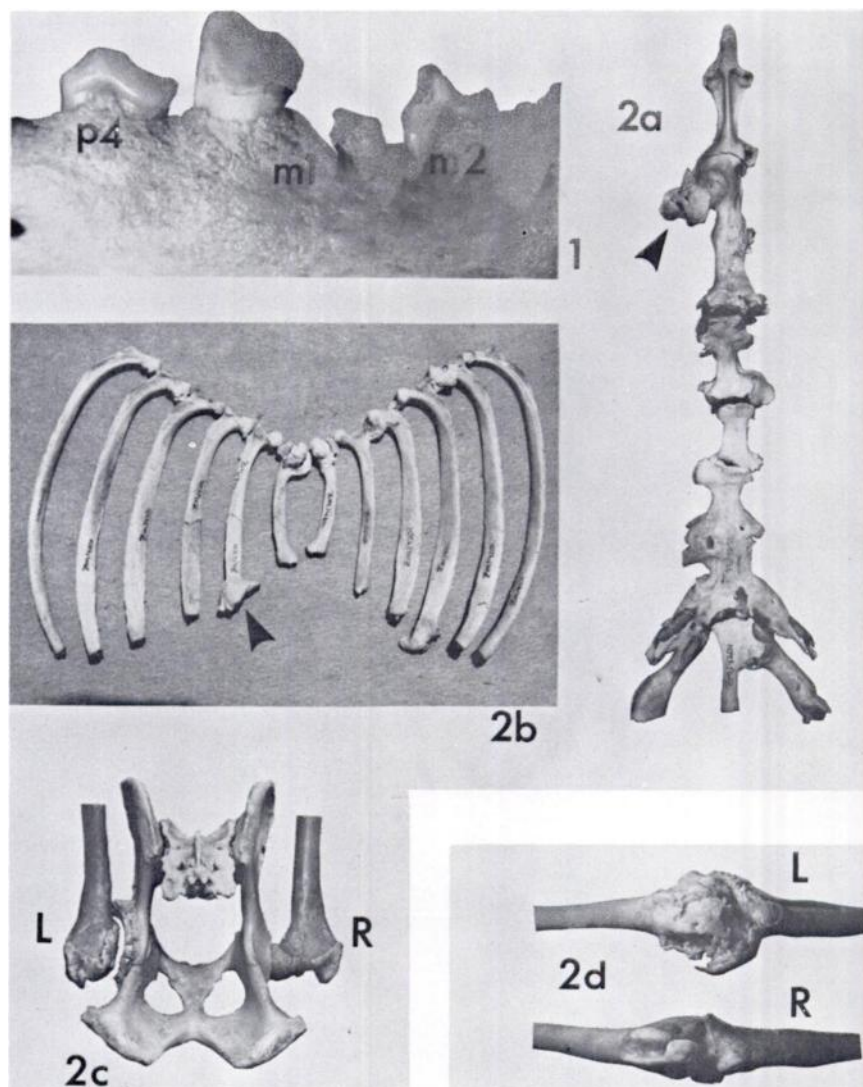


FIGURE 1. Left molar/1; breakage or wear has divided the tooth into two parts.

FIGURE 2a - d. Various skeletal structures with large osteophytes: (a) Sternum; (b) heads of ribs, 1 - 6, note articulation of second left rib and sternum; (c) left hip joint, L, and right hip joint, R; (d) left knee joint, L, and right knee joint, R.

Osteoarthritis often is described as a disease of the aged. It may be primary i.e. spontaneous, or secondary i.e.

precipitated by an injury of some type.^{1,13} Ankylosis of the 3rd and 4th thoracic, 6th and 7th lumbar, and 4th and 5th coc-

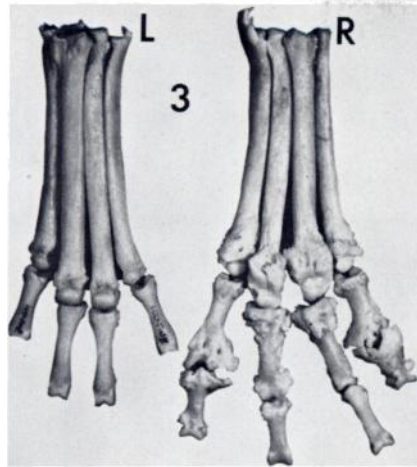


FIGURE 3. Comparison of right hind foot, R, with large periarticular osteophytes and left hind foot, L. Not all phalanges were recovered during disarticulation.

cygeal vertebrae, a healed fracture of a rib (number 12, left), absence of the left femur head, and healed fractures with osteophyte formation around several costal cartilages suggest that the hybrid suffered one or more injuries during life. Osteophytes at these injury sites and elsewhere indicated that both types of osteoarthritis may have been present.

Cross² suggested that both types of osteoarthritis contributed to the conditions he described in two Ontario wolves.

Since there were no incisors, estimate of the hybrid's age by tooth wear⁶ was not possible. We estimated the hybrid to be 14 years old, on the basis of cementum layers in tooth roots.⁸

Our specimen is the oldest wild-caught coyote x dog hybrid reported and is significant since few wild coyotes live longer than 6 years;⁶ moreover, Mengel¹² suggested that hybrids are somewhat less fit to live in the wild than coyotes. Coyotes live longer than 10 years in captivity^{3,4,10,11,14} and there are many reports of dogs living to be more than 15 years old. Two wild coyotes captured in Texas were aged as 13.5 and 14.5 years old.⁷

The hybrid's advanced age and skeletal condition probably severely hindered its ability to catch active prey. Hunters who killed the animal described it as "barely able to walk". Its stomach was full at the time it was shot and contained 541.5 g (grams) of hog and a trace of chicken.

The hybrid skeleton has been deposited in the University of Nebraska State Museum, Zoology Collections, number ZM14201.

Acknowledgements

We thank C. A. Mebus, H. L. Gunderson, and G. O. Kruse of the University of Nebraska, and H. T. Gier of Kansas State University for their critical review and helpful suggestions regarding the manuscript, and C. L. Messenger for the photographs.

LITERATURE CITED

1. BARRETT, R.E. 1977. Canine polyarthritis. *Current Vet. Therapy* 6: 890-897.
2. CROSS, E.C. 1940. Arthritis among wolves. *Can. Field-Nat.* 54: 2-4.
3. DOBRORUKA, L.J. 1968. Ein hohes Alter beim Präriewolf, *Canis latrans* Say, 1823. *Zool. Gart., Prag.* 35: 280.
4. FLOWER, S.S. 1931. Contributions to our knowledge of the duration of life in vertebrate animals. *Proc. Zool. Soc. London.* 1931: 145-234.

5. FOX, H. 1939. Chronic arthritis in wild mammals. *Trans. Am. Phil. Soc.* 31: 73-124.
6. GIER, H.T. 1968. *Coyotes in Kansas*. Bull. Agric. Exp. Sta., Kansas State Univ., No. 393, Manhattan, 118 pp.
7. KNOWLTON, F.F. 1972. Preliminary interpretations of coyote population mechanics with some management implications. *J. Wildl. Manage.* 36: 369-382.
8. LINHART, S.B., and F.F. KNOWLTON. 1967. Determining age of coyotes by tooth cementum layers. *J. Wildl. Manage.* 31: 362-365.
9. MAHAN, B.R., P.S. GIPSON and R.M. CASE. 1978. Characteristics and distribution of coyote x dog hybrids collected in Nebraska. *Am. Midl. Nat.*: *In press*.
10. MANN, W.M. 1943. Wild animals in and out of the zoo. *Smithsonian Sci. Ser.*, Vol. 6. Smithsonian Inst., Wash., D.C., 374 pp.
11. MANVILLE, R.H. 1953. Longevity of the coyote. *J. Mammal.* 34: 390.
12. MENGEL, R.M. 1971. A study of dog-coyote hybrids and implications concerning hybridization in *Canis*. *J. Mammal.* 52: 316-336.
13. OLSSON, S. 1971. Degenerative joint disease (osteoarthrosis): a review with special reference to the dog. *J. Sm. Anim. Pract.* 12: 333-342.
14. YOUNG, S.P. and H.H.T. JACKSON. 1951. *The Clever Coyote*. Stackpole Co., Harrisburg, Pa. 411 pp.

Received for publication 28 January 1978
