

ABERRATIONS OF THE TOOTH ARCADE AND MANDIBLE IN DALL'S SHEEP FROM SOUTHWESTERN YUKON 1

Authors: GLAZE, ROBERT L., HOEFS, MANFRED, and BUNCH, THOMAS D.

Source: Journal of Wildlife Diseases, 18(3) : 305-309

Published By: Wildlife Disease Association

URL: <https://doi.org/10.7589/0090-3558-18.3.305>

The BioOne Digital Library (<https://bioone.org/>) provides worldwide distribution for more than 580 journals and eBooks from BioOne's community of over 150 nonprofit societies, research institutions, and university presses in the biological, ecological, and environmental sciences. The BioOne Digital Library encompasses the flagship aggregation BioOne Complete (<https://bioone.org/subscribe>), the BioOne Complete Archive (<https://bioone.org/archive>), and the BioOne eBooks program offerings ESA eBook Collection (<https://bioone.org/esa-ebooks>) and CSIRO Publishing BioSelect Collection (<https://bioone.org/csiro-ebooks>).

Your use of this PDF, the BioOne Digital Library, and all posted and associated content indicates your acceptance of BioOne's Terms of Use, available at www.bioone.org/terms-of-use.

Usage of BioOne Digital Library content is strictly limited to personal, educational, and non-commercial use. Commercial inquiries or rights and permissions requests should be directed to the individual publisher as copyright holder.

BioOne is an innovative nonprofit that sees sustainable scholarly publishing as an inherently collaborative enterprise connecting authors, nonprofit publishers, academic institutions, research libraries, and research funders in the common goal of maximizing access to critical research.

ABERRATIONS OF THE TOOTH ARCADE AND MANDIBLE IN DALL'S SHEEP FROM SOUTHWESTERN YUKON¹

ROBERT L. GLAZE,² MANFRED HOEFS,³ and THOMAS D. BUNCH¹

Abstract: Nine Dall's sheep (*Ovis dalli dalli*) collected in the Ruby Mountains of southwestern Yukon were examined for aberrations of the tooth arcade and mandible. Missing and displaced teeth were common in older sheep (≥ 6 yr). Necrosis of the mandible was observed in five of eight rams and in one ewe. *Corynebacterium pyogenes* was cultured from exudates from two rams with enlarged fistulated mandibles. The sequence of events leading to lesions of the tooth arcade and to "lumpy jaw" is postulated to be associated with abnormal wearing of teeth and a disrupted alignment of the tooth arcade, impaction of vegetable matter between teeth and between the gingiva and the root of the tooth, and penetration of the traumatized gingiva membrane and alveolus by oral bacteria which induce a necrotizing infection.

INTRODUCTION

Aberrations of the tooth arcade (i.e., loosened, displaced, missing, or shed teeth, excessive protrusion or uneven abrasion, etc.) and focal osteolysis of the mandible have a high prevalence in many populations of Dall's sheep (Sheldon, 1930; Murie, 1944; Neiland, 1972; Hoefs and Cowan, 1979). Because of enlargement of the mandible, the disease has been referred to as "lumpy jaw." Early reports of lumpy jaw in Dall's sheep implied that *Actinomyces* was the etiologic agent (Murie, 1944). *Actinomyces*, however, has never been identified in lesions of the mandible in Dall's sheep (Neiland, 1972). Neiland (1972) isolated *Corynebacterium pyogenes* and *Fusobacterium necrophorum* from a severe case of lumpy jaw in a Dall's sheep. We collected several Dall's sheep from a population having a high prevalence of lumpy jaw and herein describe the lesions found.

MATERIALS AND METHODS

One ewe and eight rams were collected from a population in the Ruby Range of the Kluane Lake area in southwestern Yukon. A post-mortem examination was conducted on all sheep. The tooth arcade and mandible of each animal was examined and abnormalities were recorded. Two mandibles with large granulomatous lesions were removed, packaged in blue ice and air transported to the Utah State University Veterinary Diagnostic Laboratory for identification of pathogenic organisms and for radiographic analysis. Exudate from granulomatous lesions was examined for *Actinomyces* according to the technique of Carter (1973) and for other microorganisms by growing on blood agar as described by Washington (1981). Radiographs were taken of the lateral sides of mandibles and of 6mm transverse sections removed from areas with granulomatous lesions.

¹ Supported by the Foundation for North American Wildsheep, The Yukon Wildlife Branch and Utah State University, Logan, Utah 84322, USA.

² Glaze Veterinary Clinic, Kerrville, Texas 78025, USA.

³ Yukon Wildlife Branch, Box 2703, Whitehorse, Yukon Territory Y1A 2C6, Canada.

⁴ Department of Animal, Dairy and Veterinary Sciences, Utah State University, Logan, Utah 84322, USA.

RESULTS

Aberrations of the tooth arcade were observed in the ewe and five of the six rams that were six or more years of age. The severity of loss or displacement of teeth was associated with increasing age. The tooth arcades of the two rams that were classified as 2 yr of age were normal. The most extreme case of tooth loss was observed in a ram judged to be more than 14 yr of age. Abnormal protrusion in pairs of teeth was often associated with missing teeth. Dental aberrations also consisted of marked angulation of occlusal surfaces of cheek teeth, with sharp edges on the buccal aspect of maxillary teeth and the lingual aspect of mandibular teeth (Fig. 1).

Five of the eight rams and the ewe had various degrees of focal necrosis of the lower mandible. In more advanced cases, the body of the mandible was markedly enlarged. The periosteal surface of each enlarged area was irregular and

roughened, often with several fistulous tracts.

A creamy, viscous exudate was found in sagittal sections of two mandibles (Fig. 2). Associated with these pockets of infection were one to several fistulous tracts. Cultures of exudates grew *Corynebacterium pyogenes*.

Radiographs of severely affected mandibles showed areas of radiolucency with tracts extending downward from roots of some molar teeth to the proliferative periosteal surface. Cross sections of affected mandibles showed focal areas with loss of trabecular and cortical bone (Fig. 3).

Impacted vegetation was observed in some of the mandibles between the gingiva and crown-root junction of molar teeth. The impacted substance, which often consisted of hardened plant material, extended downward along the roots of molar teeth.

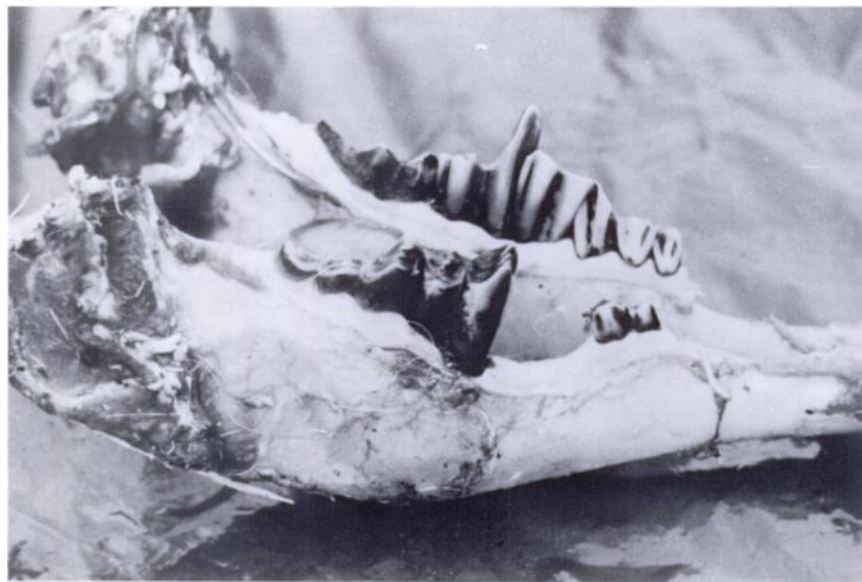

FIGURE 1. Mandibles of a Dall's sheep showing a tooth that is missing or has undergone excessive abrasion resulting in aberrant protrusions of opposing occluding teeth.

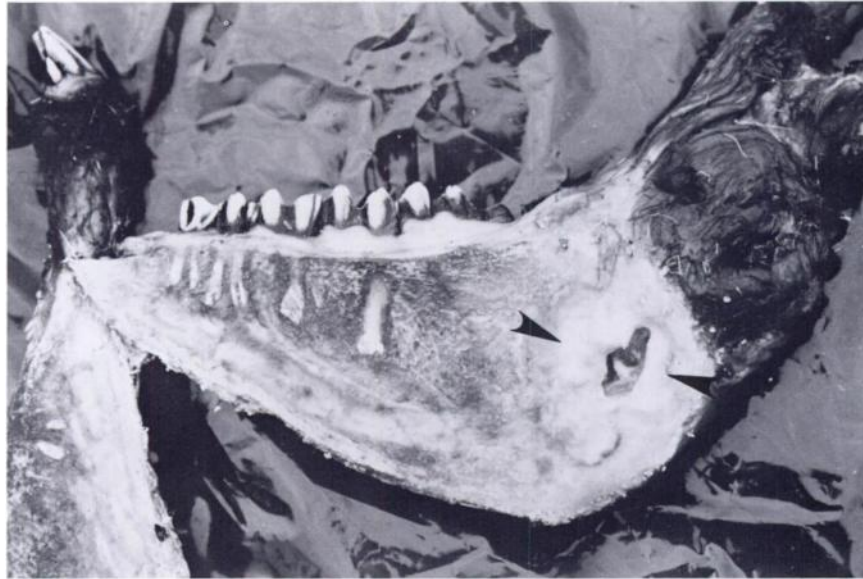


FIGURE 2. Sagittal section of a mandible of a Dall's sheep with necrotic areas (arrows) from which *Corynebacterium pyogenes* was cultured.

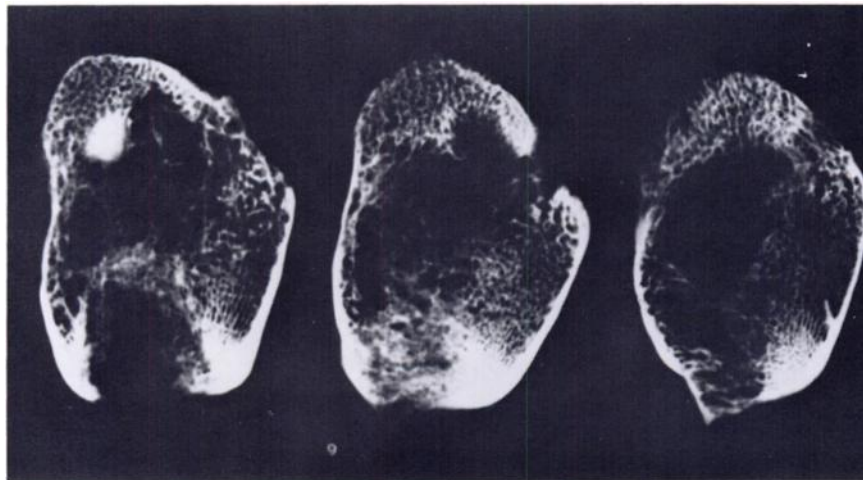

FIGURE 3. Cross sections of affected mandibles showing extensive loss of trabecular and cortical bone.

DISCUSSION

The Yukon Wildlife Branch began to inspect the jaws of hunter-killed Dall's

rams in the Fall of 1979 (Hoefs and Cowan 1979). They found that on a Territory-wide scale, 54% of the rams

killed (n=176) had dental problems of various kinds and/or affected mandibles. Preliminary analysis of 1980 data revealed a similarly high prevalence of dental lesions. Exudates from several of these mandibles were cultured at the Wildlife Pathology and Parasitology Division of the Canadian National Wildlife Research Center, Ottawa. *Actinomyces* was not found, although *Proteus*, *Micrococci* and *Escherichia* were isolated.

The prevalence of aberrations of the tooth arcade and mandible in the Dall's sheep we investigated approached 67%. Based on studies of hunter-killed rams (7 yr old or older) in this population, the prevalence was 49% in 1979 (n=35) and 45% in 1980 (n=30) (Hoefs and Cowan, 1979). The implications of this morbidity rate are unknown; however, missing, displaced or aberrant growth of teeth must affect an animal's consumption of forage. Although the relationship of tooth arcade aberrations and lumpy jaw to malnutrition remains speculative, Sheldon (1930) observed dead Dall's rams that were severely emaciated and attributed their condition to lumpy jaw. Murie (1944), in his classic study of Dall's sheep in Mt. McKinley National Park, assumed that lumpy jaw lowered the life expectancy of affected sheep by predisposing them to predation. Allred and Bradley (1966) concluded that necrosis and other dental problems must be considered an important limiting factor affecting life expectancy. Neiland (1972) stated that sheep with lumpy jaw do not efficiently use forage resources and lose condition disproportionately to seasonal declines in the nutritional production of the range they inhabit. Oral abscesses and necrotic areas harbor organisms that may infect other tissues.

All sheep examined in this study were in excellent condition. We were working, however, in July when the quality of alpine forage was near its seasonal peak.

Our observations support the conclusion of Neiland (1972) that there is no

factual basis for associating lumpy jaw in Dall's sheep with Actinomycosis. We believe that tooth arcade lesions in Dall's sheep of the Kluane area are predisposed by excessive abrasion of teeth, marked angulation of occlusal surfaces and tooth malalignment, with concomitant impaction of vegetable matter. These aberrations cause inadequate lateral movement of the jaws and further subnormal resistance to wear. On the reasons for this, we can only speculate.

The climate in the study area is characterized by low annual precipitation and frequent high winds. On the west side of Kluane Lake, about three miles from our study population, where intensive ecological research has been done, frequent dust storms result in the deposition of large amounts of dust and silt on the forage. The sheep in that area do not live as long as in other areas of less siltation. Accelerated tooth wear is believed to be the primary cause of their reduced longevity. It was found that the dry weight of some of the plants consisted of as much as 50% dry mineral matter. Seventy percent of the skulls (n=20) picked up in this area exhibited lumpy jaw (Hoefs and Cowan, 1979). This phenomenon may also apply to our study area, though to a lesser degree. Escalated tooth abrasion of sheep resulting from siltation on forages also has been observed in Siberian wild sheep, *Ovis nivicola*, (Egorou, 1967). Mastication of soil and sand by domestic sheep of arid and semi-arid ranges of the western and southwestern United States also has been reported to cause accelerated dental attrition (Jensen, 1974). The rate of wear was directly related to volume of soil and sand ingested.

Excessive tooth abrasion may also be caused by ingestion of less palatable, coarse vegetation. Some supportive evidence comes from the analysis of data acquired from mandibles submitted by sheep hunters, which suggests that dense populations of sheep also have

high prevalence of mandibular and dental problems. It is in high density populations that use of less palatable coarse forage is most likely.

Lastly, improper mineralization of the developing tooth from a calcium deficiency or a calcium phosphorous imbalance may also contribute to tooth and jaw anomalies. Research conducted on domestic sheep identified a relationship between mandibular anomalies and the pasturing of sheep on marginal ranges (Orr, 1979). Domestic sheep subsisting on calcium-deficient diets or calcium/

phosphorus-unbalanced diets during their first 18 mo develop defective tooth enamel and dentine (Jensen, 1974).

Chronic infections, such as we observed in Dall's sheep, also may lead to enlargements of the mandibles and numerous fistulous tracts. These effects resemble the *Actinomyces* lesions that have been described for domestic livestock and therefore may have led to *Actinomyces* being considered as the sole etiological agent of lumpy jaw in Dall's sheep.

Acknowledgements

The authors thank Drs. James LeGrande Shupe and Ross A. Smart, Department of Animal, Dairy and Veterinary Sciences, Utah State University, Logan, for their assistance in describing the pathology associated with bone lesions of the mandible in Dall's sheep. Field assistance was provided by Mr. Toni Nette and Dr. Homer S. Ellsworth. This manuscript is published as Utah State University Agricultural Experiment Station Journal Paper No. 2759.

LITERATURE CITED

- ALLRED, G. and W.B. BRADLEY. 1966. Comparative studies of necrosis associated with teeth in desert bighorns. Trans. Desert Bighorn Council. 10: 86-97.
- CARTER, G.R. 1973. *Diagnostic Procedures in Veterinary Microbiology*. 2nd Ed. Charles C. Thomas, Springfield, Illinois. 362 pp.
- EGOROU, O.V. 1967. *Wild Ungulates of Yutia*. Israel Program of Scientific Translations, Jerusalem, Israel. 204 pp.
- HOEFS, M. and I. MCT. COWAN. 1979. Ecological investigation of a population of Dall Sheep (*Ovis dalli dalli* Nelson). Syesis. 12, Suppl. 1. 81 pp.
- JENSEN, R. 1974. *Diseases of Sheep*. Lea and Febiger, Philadelphia, Pennsylvania. 389 pp.
- MURIE, A. 1944. *The Wolves of Mount McKinley*. U.S. Dept. Int. Nat. Parks Serv., Fauna Series 5. 238 pp.
- NEILAND, K.A. 1972. Sheep disease studies. Alaska Dept. of Fish and Game. Project No. W-17-3 & 4. 31 pp.
- ORR, M.B. 1979. A Syndrome of Dental Abnormalities of Sheep II. The pathology and radiology. N.Z. Vet. J. 27: 276-278.
- SHELDON, C. 1930. *The Wilderness of Denali: Exploration of a Hunter-naturalist in Northern Alaska*. Charles Scribner's Sons, New York. 412 pp.
- WASHINGTON, J.A. 1981. *Laboratory Procedures In Clinical Microbiology*. Springer-Verlag, New York. 856 pp.

Received for publication 2 November 1981