

Sparganosis in a Saddle-back Tamarin: Another Case of Viral-Induced Proliferation?

Authors: Gardiner, C. H., and Imes, G. D.

Source: Journal of Wildlife Diseases, 22(3) : 437-439

Published By: Wildlife Disease Association

URL: <https://doi.org/10.7589/0090-3558-22.3.437>

The BioOne Digital Library (<https://bioone.org/>) provides worldwide distribution for more than 580 journals and eBooks from BioOne's community of over 150 nonprofit societies, research institutions, and university presses in the biological, ecological, and environmental sciences. The BioOne Digital Library encompasses the flagship aggregation BioOne Complete (<https://bioone.org/subscribe>), the BioOne Complete Archive (<https://bioone.org/archive>), and the BioOne eBooks program offerings ESA eBook Collection (<https://bioone.org/esa-ebooks>) and CSIRO Publishing BioSelect Collection (<https://bioone.org/csiro-ebooks>).

Your use of this PDF, the BioOne Digital Library, and all posted and associated content indicates your acceptance of BioOne's Terms of Use, available at www.bioone.org/terms-of-use.

Usage of BioOne Digital Library content is strictly limited to personal, educational, and non-commercial use. Commercial inquiries or rights and permissions requests should be directed to the individual publisher as copyright holder.

BioOne is an innovative nonprofit that sees sustainable scholarly publishing as an inherently collaborative enterprise connecting authors, nonprofit publishers, academic institutions, research libraries, and research funders in the common goal of maximizing access to critical research.

Sparganosis in a Saddle-back Tamarin: Another Case of Viral-Induced Proliferation?

C. H. Gardiner¹ and G. D. Imes, Jr., Department of Veterinary Pathology, Armed Forces Institute of Pathology, Washington, D.C. 20306, USA

A saddle-back tamarin (*Saguinus fuscicollis illigeri* Pucheran, 1845) maintained in Oak Ridge Laboratory, Oak Ridge, Tennessee, for 6 yr was found dead in its cage. Necropsy revealed numerous small nodules in the thoracic cavity only, 1–5 mm in diameter, causing marked adhesions of thoracic organs. Grossly the nodules appeared as abscesses. A 1-cm³ portion of supradiaphragmatic nodule was fixed in 10% buffered formalin and submitted for histopathology.

Histologically there were multiple adventitious cysts in apposition to one another (Fig. 1). The fibrous connective tissue forming the cyst walls was infiltrated by plasma cells and lymphocytes. The cysts contained intact and degenerating cestode larvae in addition to inflammatory cells, i.e., macrophages, lymphocytes, plasma cells, and rare giant cells. The morphology of the larva was most consistent with that of a sparganum. Although measurements of diameter and width are difficult with cestodes, the diameter was estimated to be from 200 to 500 μ m. The larvae were filled with parenchyma and contained excretory canals and fine strands of muscle. Many larvae contained very basophilic accumulations of large nuclei when stained with H&E (Figs. 1–4). These measured up to 9 μ m in diameter. These nuclei were most abundant in the cortical layer of the larvae. An amorphic eosino-

philic substance was found on the tegument of numerous larvae (Fig. 2).

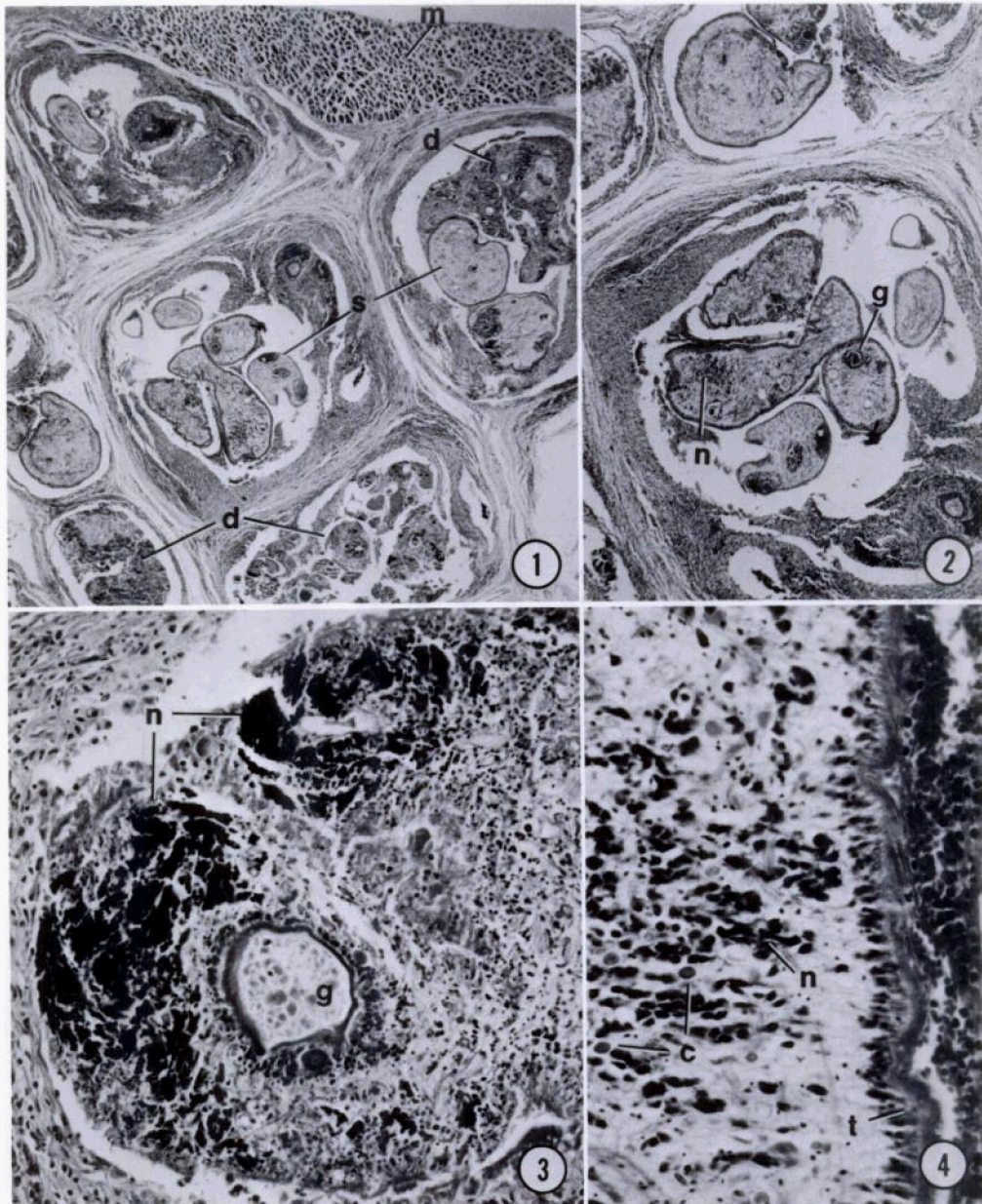
Portions of the paraffin-embedded tissue were cut from the block, deparaffinized, postfixed in Dalton's osmium-dichromate solution (Dalton, 1955, Anat. Rec. 121: 281), and processed for transmission electron microscopy. Sections were cut at 8 nm and studied with a Zeiss 9 electron microscope.

Ultrastructurally, the large, basophilic nuclei noted in histologic section were found to be cerebriiform with large nuclei and peripheral plaques of chromatin (Fig. 5). Viral particles, averaging 200 nm in diameter, were found throughout the cytoplasm of intact and degenerating larvae. The particles had an electron-lucent core and thick shell (Fig. 5, inset). Spherical viruses averaging 200 nm in diameter are uncommon, but have been reported with some members of the Arenaviridae and Paramyxoviridae families (Mohanty and Dutta, 1981, Veterinary Virology, Lea and Febiger, Philadelphia, Pennsylvania, pp. 10–38).

This case is almost identical to one published recently by Buergelt et al. (1984, J. Parasitol. 70: 121–125). Their case involved proliferative spargana in the liver, spleen, stomach, and peritoneum of a cat. The spargana in the present case had many similarities to the spargana in that case. Both types contained large basophilic, hyperchromatic nuclei and viral particles within the stroma of the parasite. The viral particles in their case, however, measured 70 to 80 nm in diameter. Mueller and Strano (1974, J. Parasitol. 60: 15–19)

Received for publication 28 June 1985.

¹ Present address: Naval Medical Research Institute Detachment, Lima, Peru, APO Miami, Florida 34031, USA.



FIGURES 1-4. Adventitious cysts in the thoracic cavity of a saddle-back tamarin due to spargana. 1. Numerous adventitious cysts attached to skeletal muscle containing spargana; (d), degenerating spargana; (m) skeletal muscle; (s), intact spargana. H&E, $\times 15$. 2. Higher magnification of adventitious cysts; (g), glandular accumulation within sparganum; (n), hyperchromatic nuclei. H&E, $\times 25$. 3. Degenerating sparganum containing accumulations of hyperchromatic nuclei (n) and glandular secretions (g). H&E, $\times 160$. 4. Intact sparganum; (c), calcareous corpuscles; (n), hyperchromatic nuclei; (t) tegument, H&E, $\times 250$ (AFIP MIS #84-12694-1).

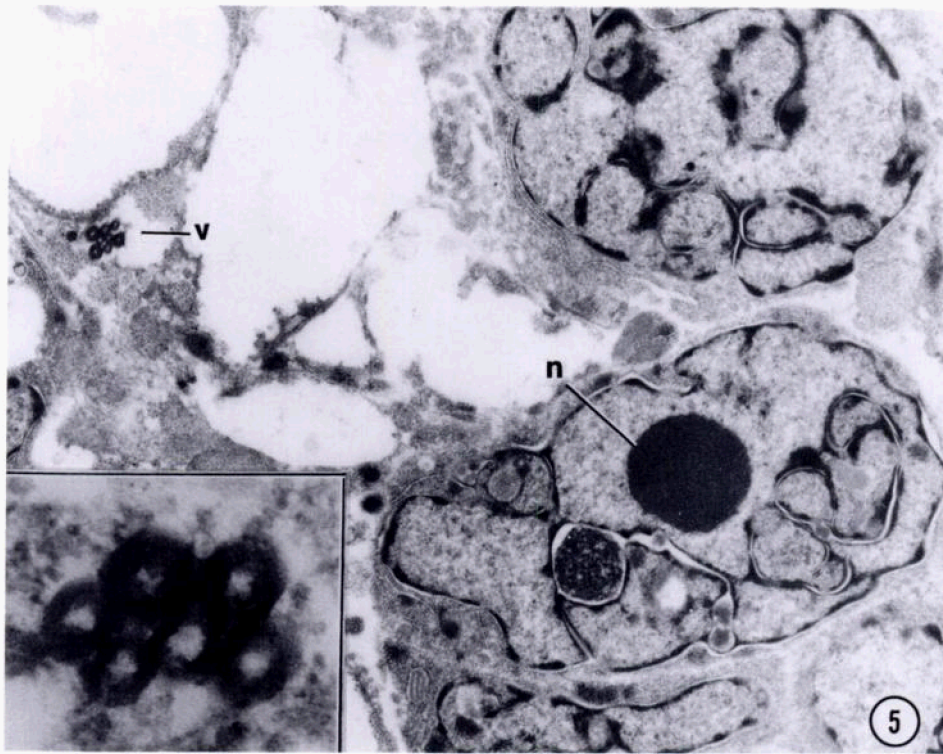


FIGURE 5. Transmission electron micrograph of sparganum from a saddle-back tamarin. Parenchyma of sparganum demonstrating large, cerebriform nuclei; (n), nucleolus; (v), viral particles, TEM, $\times 10,600$. Inset. Higher magnification of viral particles. Note electron-lucent core and thick shell. TEM, $\times 56,600$ (AFIP MIS #84-12694-2).

hypothesized the proliferative nature of spargana infected with viruses. The viral particles in their case measured approximately 85 nm in diameter.

It is not known how the tamarin in this case became infected with the spargana, but we assume it ingested a copepod containing a proceroid. The adventitious na-

ture of the cysts, each containing an intact or degenerating coiled larva, is also unexpected. Histologic sections of only a small portion of the grossly described mass contained at least 15 oval cysts. It seems unlikely that the tamarin ingested this number of proceroids.