

ULTRASTRUCTURE OF SARCOCYSTIS SPP. (PROTOZOA: APICOMPLEXA) IN RODENTS FROM NORTH SULAWESI AND WEST JAVA, INDONESIA

Authors: O'Donoghue, P. J., Watts, C. H. S., and Dixon, B. R.

Source: Journal of Wildlife Diseases, 23(2) : 225-232

Published By: Wildlife Disease Association

URL: <https://doi.org/10.7589/0090-3558-23.2.225>

BioOne Complete (complete.BioOne.org) is a full-text database of 200 subscribed and open-access titles in the biological, ecological, and environmental sciences published by nonprofit societies, associations, museums, institutions, and presses.

Your use of this PDF, the BioOne Complete website, and all posted and associated content indicates your acceptance of BioOne's Terms of Use, available at www.bioone.org/terms-of-use.

Usage of BioOne Complete content is strictly limited to personal, educational, and non - commercial use. Commercial inquiries or rights and permissions requests should be directed to the individual publisher as copyright holder.

BioOne sees sustainable scholarly publishing as an inherently collaborative enterprise connecting authors, nonprofit publishers, academic institutions, research libraries, and research funders in the common goal of maximizing access to critical research.

ULTRASTRUCTURE OF *SARCOCYSTIS* SPP. (PROTOZOA: APICOMPLEXA) IN RODENTS FROM NORTH SULAWESI AND WEST JAVA, INDONESIA

P. J. O'Donoghue,¹ C. H. S. Watts,² and B. R. Dixon³

¹ Central Veterinary Laboratories, Department of Agriculture, Frome Rd., Adelaide, South Australia 5000, Australia

² South Australian Museum, North Terrace, Adelaide, South Australia 5000, Australia

³ Tissue Pathology Division, Institute of Medical and Veterinary Science, Frome Rd., Adelaide, South Australia 5000, Australia

ABSTRACT: Tissue cysts of the protozoan genus *Sarcocystis* were detected in the skeletal muscles of 16 (40%) of 40 wild rodents captured in North Sulawesi and West Java, Indonesia. Two types of cysts were found to differ in their morphological characteristics. Macroscopic and microscopic cysts bounded by thick radially-striated cyst walls were detected at both locations in a total of 13 rodents belonging to seven different species (*Bunomys chrysocomus*, *B. fratorum*, *Maxomys bartelsii*, *M. musschenbroekii*, *Paruromys dominator*, *Rattus xanthurus* and *R. exulans*). The primary cyst walls contained numerous broad spatula-like protrusions and the cysts were identified as *S. singaporensis* Zaman and Colley, 1976. In contrast, microscopic cysts bounded by thin smooth cyst walls were detected in seven rodents belonging to three different species captured at Toraut in North Sulawesi (*B. chrysocomus*, *B. fratorum* and *P. dominator*). Ultrastructural examination revealed numerous slender hair-like protrusions of their primary cyst walls. It is proposed that these cysts be named *S. sulawesiensis* sp. n. on the basis of their unique morphological characteristics, their intermediate host range and their limited geographic distribution. Mixed infections by both species were found in three rodent species (*B. chrysocomus*, *B. fratorum* and *P. dominator*).

Key words: Apicomplexa, *Sarcocystis* spp., ultrastructure, rodents, Indonesia, electron microscopy.

INTRODUCTION

Sarcocystis spp. cysts have been reported previously in the skeletal muscles of several rodent species from Indonesia. Macroscopic cysts were detected in the muscles of four *Rattus argentiventer* (= *R. rattus brevicaudatus*), 10 *R. rattus diardi* and 53 *R. norvegicus* (= *R. norvegicus javanicus*) examined from three locations in West Java (Holz and Sioe, 1965), whereas microscopic cysts were detected in the diaphragm muscles of eight *R. rattus diardi*, 12 *R. exulans* and one *R. argentiventer* captured in Central Java (Cross et al., 1973). Microscopic cysts were also detected in eight *R. exulans* and eight *R. rattus* (= *R. rattus palelae*) in a survey of 262 rats examined from more than 50 locations in Sulawesi (Brown et al., 1974). However, none of these reports provided detailed morphological descriptions of the cysts and the species were not identified. This in-

vestigation describes the morphological and ultrastructural characteristics of two *Sarcocystis* spp. detected in rodents from Indonesia.

MATERIALS AND METHODS

Forty wild rodents were captured by trapping at Toraut, Hogs Back, Lakes Bungalow and Muajat in North Sulawesi and Ciboros in West Java during July–August 1985 (Fig. 1). The carcasses were opened by midline incisions and fixed in 10% formalin prior to their transport to the South Australian Museum in Adelaide. The thoracic and abdominal skeletal musculature of each rodent was subject to close visual examination for the presence of macroscopic parasitic cysts. Muscle samples were then taken from the walls of the abdominal cavity of each animal and processed for microscopic examination. The muscle samples were embedded in paraffin wax, sectioned at 5 µm thickness, stained with haematoxylin and eosin and examined under a light microscope at 100–400× magnification. When parasitic cysts were detected in the histological sections, the corresponding paraffin-embedded

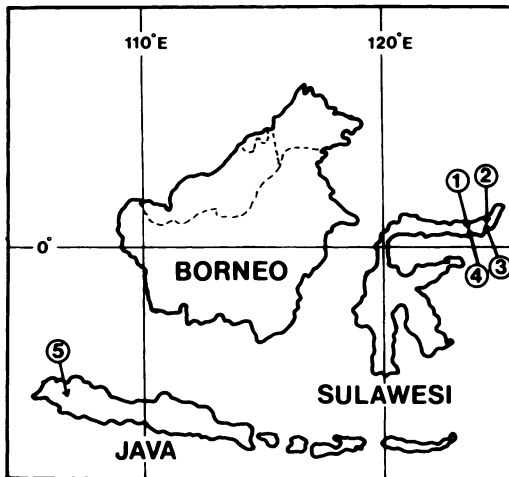


FIGURE 1. Collection sites for rodents in Indonesia (1, Hogs Back; 2, Muajat; 3, Lakes Bungalow; 4, Toraut; and 5, Ciboros).

tissues were processed for ultrastructural examination. The tissues were deparaffinized in xylol containing 2% osmium tetroxide, cleared in propylene oxide and embedded in epoxy resin (TAAB Laboratories Ltd., Berkshire, England). Ultrathin sections were cut at 75 nm thickness, stained with 6% uranyl acetate and 0.5% lead citrate, and examined in a transmission electron microscope (JEM 100 CX, JEOL Ltd., Tokyo, Japan). Voucher specimens of formalin-fixed tissues containing cysts were also deposited with the South Australian Museum, Adelaide, Australia and allocated accession numbers E 1792–1807.

TABLE 1. *Sarcocystis* spp. in rodents from Indonesia.

Location	Host species	Number examined	Number infected	Thick-walled cysts (<i>S. singaporensis</i>)	Thin-walled cysts (<i>S. sulawesiensis</i> sp. n.)
North Sulawesi	<i>Bunomys chrysocomus</i>	4	2 ^a	2	1
	<i>Bunomys fratrorum</i>	10	6 ^a	3	5
	<i>Maxomys hellwaldii</i>	5	0	—	—
	<i>Maxomys musschenbroekii</i>	6	1	1	—
	<i>Paruromys dominator</i>	5	3 ^a	3 ^b	1
	<i>Rattus exulans</i>	1	1	1	—
	<i>Rattus hoffmani</i>	2	0	—	—
	<i>Rattus xanthurus</i>	3	1	1	—
West Java	<i>Maxomys bartelsii</i>	3	2	2	—
	<i>Niviventer crenoriventer</i>	1	0	—	—
Total		40	16 (40%)	13 (33%)	7 (18%)

^a Mixed infections by both species detected in one *B. chrysocomus*, two *B. fratrorum* and one *P. dominator*.

^b Macroscopic cysts detected in one *P. dominator*.

RESULTS

Sarcocystis spp. cysts were detected in the skeletal muscles of 16 (40%) of the 40 wild rodents examined (Table 1). Cysts were detected in six rodent species from North Sulawesi and in another species from West Java. Light and electron microscopic examination of the cysts revealed two distinct morphological types; thick-walled and thin-walled cysts.

Thick-walled cysts

Cysts bounded by thick radially-striated cyst walls were detected in 13 rodents (11 from North Sulawesi and two from West Java) belonging to seven different species (Table 1). Cysts found in 12 of the rodents were all microscopic in size, whereas both macroscopic and microscopic cysts were detected in the remaining animal (one *P. dominator* from North Sulawesi). The microscopic cysts ranged in size from 20 to 280 μm in length by 20 to 100 μm in width, whereas the macroscopic cysts ranged from 1 to 4 mm in length by 0.2 to 0.5 mm in width. The cyst wall of both macroscopic and microscopic cysts measured from 3.5 to 5.0 μm in diameter and the radial striations occurred at 1–2 μm intervals (Fig. 2). The cysts were septate and their interior compartments were filled with cystozoites

measuring 5–7 μm in length by 1.0–1.5 μm in width.

Ultrastructural studies on both macroscopic and microscopic thick-walled cysts from the different host species revealed that their primary cyst walls were repeatedly folded to form regular spatula-like protrusions projecting perpendicularly outwards from the surface of the cysts (Fig. 3). A band of ground substance measuring $\leq 0.7 \mu\text{m}$ in thickness was located immediately beneath the primary cyst wall. This band of ground substance also gave rise to thin septa dividing the cyst interior into a series of compartments. The compartments were filled with numerous mature cystozoites containing organelles characteristic of apicomplexan protozoa (apical complex, micronemes, rhoptries, polysaccharide granules, micropores). Large undifferentiated merozoites were also occasionally observed within several compartments. The primary cyst wall consisted of a single unit membrane thickened by an underlying layer of osmiophilic material and its continuity was regularly interrupted by the presence of numerous vesicle-like invaginations measuring 0.05 μm in diameter (Fig. 4). The spatula-like protrusions ranged from 3.5 to 5.0 μm in length and they consisted of short narrow stalks (0.5–1.5 μm long by 0.1–0.7 μm wide) surmounted by large broad bulbs (3.0–4.5 μm long by 1.0–2.5 μm wide). The bulbs were filled with loosely-packed ground substance and they contained fewer vesicle-like invaginations than the stalks.

These thick-walled cysts were identified on the basis of their morphological and ultrastructural characteristics as *S. singaporensis* Zaman and Colley, 1976.

Thin-walled cysts

Microscopic cysts bounded by thin smooth cyst walls were detected in seven rodents from one location in North Sulawesi (Table 1). The rodents belonged to three different species captured at Toraut

(Fig. 1). The cysts were microscopic in size and ranged from 20 to 120 μm in length by 15 to 50 μm in width. Their cyst walls measured from 0.2 to 0.6 μm in diameter and no striations were evident (Fig. 5). The cysts were divided by septa into a series of internal compartments and the compartments were filled with cystozoites measuring from 3.5 to 6.0 μm in length by 1 to 2 μm in width.

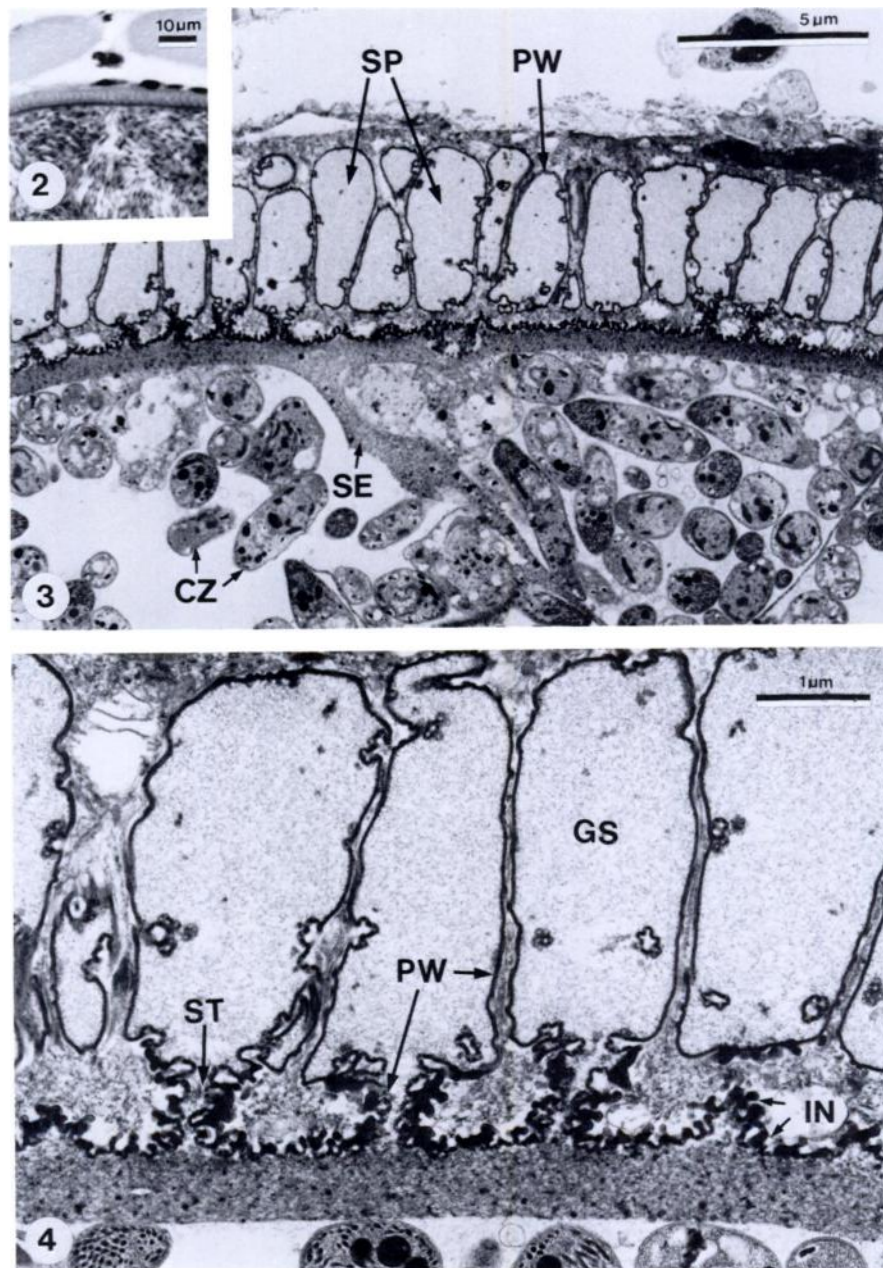
Ultrastructural studies on thin-walled cysts from the various host species revealed that their primary cyst walls contained numerous hair-like protrusions extending outwards from the cyst surface (Fig. 6). A thin band of ground substance measuring $\leq 0.2 \mu\text{m}$ in thickness was found immediately beneath the cyst wall and septa radiated inwards dividing the cyst interior into compartments. The compartments were filled with numerous mature cystozoites and several undifferentiated merozoites. The primary cyst wall consisted of a thickened unit membrane which was regularly interrupted by numerous vesicle-like invaginations. The primary cyst wall protrusions were not branched and they varied in size from 0.5 to 2.5 μm in length by 0.05 to 0.2 μm in width (Fig. 7). The protrusions were filled with loosely-packed ground substance and they were covered with numerous vesicle-like invaginations.

Cysts with similar morphological characteristics have not previously been described in rodents. Therefore it is proposed that they should be regarded as a new *Sarcocystis* sp. on the basis of their unique morphological characteristics, their intermediate host range and their limited geographical distribution. It is proposed that this species be named *Sarcocystis sulawesiensis* sp. n.

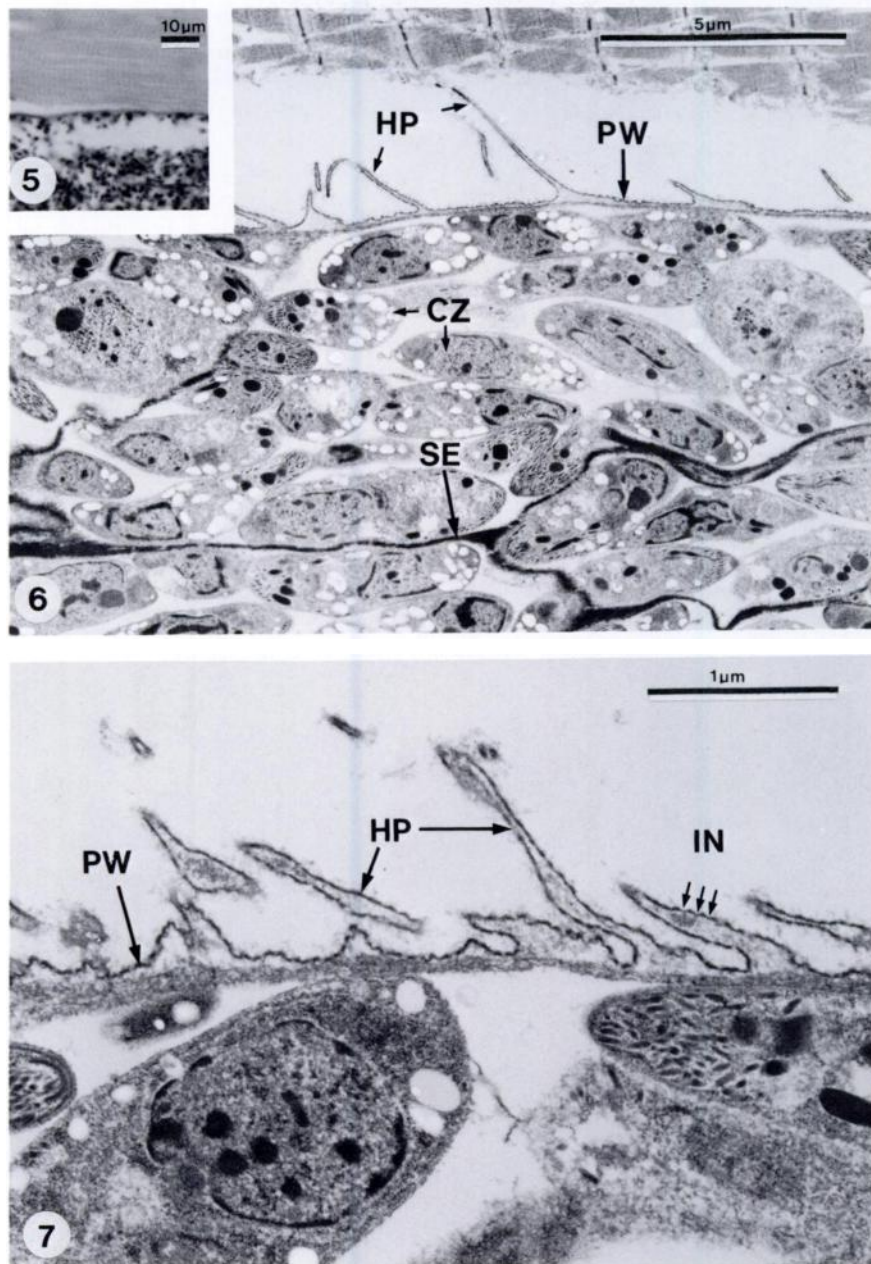
Taxonomic summary:

Sarcocystis sulawesiensis sp. n.

Type intermediate host: *Bunomys chrysocomus*



FIGURES 2-4. Microscopic cysts of *Sarcocystis singaporensis* in skeletal muscles of *Paruromys dominator*. 2. Light micrograph of cyst bounded by thick radially-striated cyst wall. H&E. 3. Transmission electron micrograph of cyst perimeter. The primary cyst wall (PW) contained numerous broad spatula-like protrusions (SP) and the cyst interior was filled with cystozoites (CZ) arranged into compartments formed by septa (SE). 4. Transmission electron micrograph of primary cyst wall showing spatula-like protrusions with finely granular ground substance (GS) and arising from short narrow stalks (ST) containing numerous vesicle-like invaginations (IN).



FIGURES 5–7. Microscopic cysts of *Sarcocystis sulawesiensis* sp. n. in skeletal muscles of *Bunomys chrysocomus*. 5. Light micrograph of cyst bounded by thin smooth cyst wall. H&E. 6. Transmission electron micrograph of cyst perimeter. The cyst interior was filled with numerous cystozoites (CZ) arranged into compartments by septa (SE) and the primary cyst wall (PW) contained thin hair-like protrusions (HP). 7. Transmission electron micrograph of primary cyst wall showing hair-like protrusions covered with vesicle-like invaginations (IN).

Other intermediate hosts: *Bunomys fratrorum*, *Paruromys dominator*.

Definitive host: Unknown.

Type locality: Indonesia, Sulawesi, Toraut (0°34'N, 123°54'E; 200–300 m).

Location in intermediate host: Cysts intracellular in skeletal muscle fibres.

Description: Mature cysts microscopic in size (20–120 × 15–50 μm), septa present, thin smooth cyst wall (0.2–0.6 μm), primary cyst wall contains numerous slender hair-like protrusions (0.5–2.5 × 0.05–0.2 μm), cystozoites banana-shaped (3.5–6.0 × 1–2 μm), metrocytes present.

Deposition of type specimens: Formalin-fixed tissues containing cysts deposited with South Australian Museum in Adelaide (accession nos. E 1795–1797, 1799–1802).

DISCUSSION

Infections of *Sarcocystis* spp. were prevalent in rodents captured in North Sulawesi and West Java, Indonesia. Infections were detected in seven of 10 rodent species examined and two different types of cysts were found to differ in their morphology and geographic distribution.

Cysts with thick radially-striated cyst walls were detected in six rodent species from North Sulawesi and in another species from West Java. The primary cyst walls contained prominent spatula-like protrusions and they were identified as *S. singaporensis* Zaman and Colley, 1976 (= *S. orientalis* Zaman and Colley, 1975 nec Machulskii and Miskaryan, 1958). This species was originally described by Zaman and Colley (1975) in the muscles of laboratory rats (*R. norvegicus*) experimentally infected with sporocysts from snakes (*Python reticulatus*) and it was proposed that the parasite be named *S. orientalis*. However, the name *S. orientalis* had already been assigned to a species found in *Capra sibirica* by Machulskii and Miskaryan (1958) (cf. Kalyakin and Zasukhin, 1975). Therefore, it was proposed that the species found in *R. norvegicus* be renamed *S. sin-*

gaporensis (Zaman and Colley, 1976). The morphological characteristics of the thick-walled cysts detected in our study conformed well to those described for *S. singaporensis* by Zaman and Colley (1975) and later by Beaver and Maleckar (1981) despite small differences in the dimensions of the cyst wall protrusions and the cystozoites.

Cysts similar in morphology to *S. singaporensis* have previously been detected in *R. rattus diardi*, *R. exulans* and *R. jalorensis* from Malaysia (Kan and Dissanaik, 1977; Kan, 1979) and in *R. fuscipes* from Australia (Rzepczyk and Scholtyseck, 1976). The results of our study extend the intermediate host range of *S. singaporensis* to include another six rodent species (*B. chrysocomus*, *B. fratrorum*, *M. musschenbroekii*, *M. bartelsii*, *P. dominator* and *R. xanthurus*) as well as extending the geographic distribution of the parasite to include North Sulawesi and West Java. Although the python *P. reticulatus* has been designated as the type definitive host of *S. singaporensis*, further transmission studies must be performed with cysts isolated from the different rodent species to confirm their definitive host specificity; particularly since *P. reticulatus* has been found in Indonesia, Malaysia, Burma, Thailand and the Philippines, but not in Australia.

In contrast to the apparent widespread distribution of *S. singaporensis*, the thin-walled cysts detected in our study were only found in three rodent species (*B. chrysocomus*, *B. fratrorum* and *P. dominator*) captured at Toraut in North Sulawesi. Ultrastructural examination of the cysts revealed their primary cyst walls to be unique in morphology in that they contained numerous thin hair-like protrusions covered with vesicle-like invaginations. Although thin-walled cysts have previously been reported in several rodent species, none have been found to contain similar protrusions of their primary cyst walls. The thin-walled cysts of *S. zamani* and *S. villivilloso* from *R. norvegicus* have elaborately-branched

primary cyst wall protrusions (Beaver and Maleckar, 1981) whereas those of *S. muris*, *S. dispersa* and *S. scotti* from *Mus musculus*, *S. booliati* from *Echinosorex gymnurus*, *S. cymruensis* from *R. norvegicus* and *S. cernae* from *Microtus arvalis* have undulating primary cyst walls without any conspicuous protrusions (Kan and Dissanaik, 1976; Viles and Powell, 1976; Ashford, 1977; Tadros, 1981).

Although the use of certain morphological characters has been questioned in the speciation of *Sarcocystis* spp. (Mehlhorn et al., 1976), recent isoenzyme electrophoretic studies have provided genetic evidence confirming the morphotypic classification of several species from domestic animals (O'Donoghue et al., 1986). Nevertheless, the thin-walled cysts detected in our study were regarded as a new species and named *S. sulawesiensis* sp. n. not only on the basis of their unique morphological characteristics, but also with regard to their intermediate host range and their limited geographic distribution. While the definitive hosts of some *Sarcocystis* spp. forming thin-walled cysts in rodents include cats, snakes and birds of prey, the definitive host(s) of *S. sulawesiensis* remains to be determined by experimental transmission studies.

At present, little information is available on the pathogenicity of the various *Sarcocystis* spp. found in rodents. Two studies have recorded high mortality rates in laboratory rats (*R. norvegicus*) experimentally infected with large numbers of *Sarcocystis* spp. sporocysts from pythons (*P. reticulatus*) (Zaman and Colley, 1975; Beaver and Maleckar, 1981). However, the majority of experimental transmission studies have involved low-dose infections subsequently reported as subclinical. Extensive studies remain to be performed not only to determine the life cycles of the various *Sarcocystis* spp. found in rodents but also to determine the pathogenicity of the parasites and their significance with regard to host disease.

ACKNOWLEDGMENTS

The authors wish to thank personnel associated with Project Wallace (Royal Entomological Society of London) for their assistance in the field, the Indonesian agency L.I.P.I. for their permission to perform the study and M. O'Callaghan for his help in the laboratory.

LITERATURE CITED

- ASHFORD, R. W. 1977. *Sarcocystis cymruensis* n. sp., a parasite of rats *Rattus norvegicus* and cats *Felis catus*. *Annals of Tropical Medicine and Parasitology* 72:37-43.
- BEAVER, P. C., AND J. R. MALECKAR. 1981. *Sarcocystis singaporensis* Zaman and Colley, (1975) 1976, *Sarcocystis villivillosi* sp. n., and *Sarcocystis zamani* sp. n.: Development, morphology, and persistence in the laboratory rat, *Rattus norvegicus*. *Journal of Parasitology* 67: 241-256.
- BROWN, R. J., W. P. CARNEY, P. F. D. VAN PEENEN, AND M. SUDOMO. 1974. *Sarcocystis* from rats in Sulawesi, Indonesia. *Southeast Asian Journal of Tropical Medicine and Public Health* 5: 451-452.
- CROSS, J. H., J. W. FRESH, G. S. JONES, AND S. GUNAWAN. 1973. *Sarcocystis* from rats of Central Java. *Southeast Asian Journal of Tropical Medicine and Public Health* 3: 435.
- HOLZ, J., AND L. J. SIOE. 1965. The parasites of rat in West-Java. *Zeitschrift für Parasitenkunde* 25: 405-412.
- KALYAKIN, V. N., AND D. N. ZASUKHIN. 1975. Distribution of *Sarcocystis* (Protozoa: Sporozoa) in vertebrates. *Folia Parasitologica (Praha)* 22: 289-307.
- KAN, S. P. 1979. Ultrastructure of the cyst wall of *Sarcocystis* spp. from some rodents in Malaysia. *International Journal for Parasitology* 9: 475-480.
- , AND A. S. DISSANAIKE. 1976. Ultrastructure of *Sarcocystis booliati* Dissanaik and Poopalachelvam, 1975 from the moonrat, *Echinosorex gymnurus*, in Malaysia. *International Journal for Parasitology* 6: 321-326.
- , AND ———. 1977. Ultrastructure of *Sarcocystis* sp. from the Malaysian house rat, *Rattus rattus diardi*. *Zeitschrift für Parasitenkunde* 52: 219-227.
- MACHULSKII, S. N., AND N. D. MISKARYAN. 1958. Trudy Buryat-Mongol'skoe Zooveterinari Institut 13: 297-299 (*non vidi*; from Kalyakin and Zasukhin, 1975).
- MEHLHORN, H., W. J. HARTLEY, AND A. O. HEYDORN. 1976. A comparative ultrastructural study of the cyst wall of 13 *Sarcocystis* species. *Protistologica* 12: 451-467.
- O'DONOGHUE, P. J., M. ADAMS, B. R. DIXON, G. E. FORD, AND P. R. BAVERSTOCK. 1986. Morphological and biochemical correlates in the char-

- acterization of *Sarcocystis* spp. *Journal of Protozoology* 33: 114–121.
- RZEPczyk, C., AND E. SCHOLTYSECK. 1976. Light and electron microscope studies on the *Sarcocystis* of *Rattus fuscipes*, an Australian rat. *Zeitschrift für Parasitenkunde* 50: 137–150.
- TADROS, W. 1981. Studies on Sarcosporidia of rodents with birds of prey as definitive hosts. In *Parasitological topics*, E. U. Canning (ed.). Allen Press, Lawrence, Kansas, USA, pp. 248–259.
- VILES, J. M., AND E. C. POWELL. 1976. The ultrastructure of the cyst wall of a murine *Sarcocystis*. *Zeitschrift für Parasitenkunde* 49: 127–132.
- ZAMAN, V., AND F. C. COLLEY. 1975. Light and electron microscopic observations on the life cycle of *Sarcocystis orientalis* sp. n. in the rat (*Rattus norvegicus*) and the Malaysian reticulated python (*Python reticulatus*). *Zeitschrift für Parasitenkunde* 47: 169–185.
- , AND ———. 1976. Replacement of *Sarcocystis orientalis* Zaman and Colley, 1975 by *Sarcocystis singaporensis* sp. n. *Zeitschrift für Parasitenkunde* 51: 137.

Received for publication 20 June 1986.