

## HEPATOZOONOSIS IN FOXES FROM PORTUGAL

Authors: Conceição-Silva, F. M., Abranches, P., Silva-Pereira, M. C. D., and Janz, J. G.

Source: Journal of Wildlife Diseases, 24(2) : 344-347

Published By: Wildlife Disease Association

URL: <https://doi.org/10.7589/0090-3558-24.2.344>

---

The BioOne Digital Library (<https://bioone.org/>) provides worldwide distribution for more than 580 journals and eBooks from BioOne's community of over 150 nonprofit societies, research institutions, and university presses in the biological, ecological, and environmental sciences. The BioOne Digital Library encompasses the flagship aggregation BioOne Complete (<https://bioone.org/subscribe>), the BioOne Complete Archive (<https://bioone.org/archive>), and the BioOne eBooks program offerings ESA eBook Collection (<https://bioone.org/esa-ebooks>) and CSIRO Publishing BioSelect Collection (<https://bioone.org/csiro-ebooks>).

Your use of this PDF, the BioOne Digital Library, and all posted and associated content indicates your acceptance of BioOne's Terms of Use, available at [www.bioone.org/terms-of-use](http://www.bioone.org/terms-of-use).

Usage of BioOne Digital Library content is strictly limited to personal, educational, and non-commercial use. Commercial inquiries or rights and permissions requests should be directed to the individual publisher as copyright holder.

---

BioOne is an innovative nonprofit that sees sustainable scholarly publishing as an inherently collaborative enterprise connecting authors, nonprofit publishers, academic institutions, research libraries, and research funders in the common goal of maximizing access to critical research.

## HEPATOZOONOSIS IN FOXES FROM PORTUGAL

F. M. Conceição-Silva,<sup>1</sup> P. Abranches,<sup>1,3</sup> M. C. D. Silva-Pereira,<sup>1</sup> and J. G. Janz<sup>2</sup>

<sup>1</sup> Disciplina de Protozoologia, Instituto de Higiene e Medicina Tropical, Rua da Junqueira 96, 1300 Lisboa, Portugal

<sup>2</sup> Centro de Estudo de Epidemiologia Tropical, Instituto de Higiene e Medicina Tropical, Rua da Junqueira 96, 1300 Lisboa, Portugal

<sup>3</sup> Author to whom correspondence should be addressed

**ABSTRACT:** *Hepatozoon* sp. is described for the first time in foxes (*Vulpes vulpes silacea*) in Portugal. Of 301 foxes examined, 143 (48%) were infected. The gametocyte was the predominant stage of the life cycle and was found in every organ except the bone marrow, where schizonts were the most abundant stage. The morphological similarity of this parasite's gametocytes to *Hepatozoon canis* is emphasized.

**Key words:** *Hepatozoon* sp., European fox, *Vulpes vulpes silacea*, *Hepatozoon canis*, survey, life history stages.

### INTRODUCTION

Several species of the genus *Hepatozoon* are reported from mammals, reptiles and birds (Levine, 1973). *Hepatozoon canis*, a parasite of the domestic dog, was the first described species. The dog tick, *Rhipicephalus sanguineus*, is the most probable vector. Dogs acquire the infection through ingestion of ticks harboring sporozoites (Christophers, 1907; Levine, 1973).

During a study on the wild reservoirs of leishmaniasis in Portugal (Abranches et al., 1982, 1983a, b, 1984), we found a species of *Hepatozoon* in foxes (*Vulpes vulpes silacea*). *Hepatozoon* sp. has been reported previously in foxes (Rau, 1926; Rioux et al., 1968; Maede et al., 1982) but the high prevalence of infection in our study resulted in a better understanding of the biology of this parasite in the vertebrate host and in the vector. Whether or not the species of *Hepatozoon* we recovered from foxes is *H. canis* remains to be resolved.

### MATERIALS AND METHODS

In January and February (season for hunting foxes) from 1979 to 1985 biological specimens were collected from 301 animals in the Lisbon and Alcácer do Sal regions of Portugal (Abranches et al., 1982, 1983a, 1984). Samples of blood, spleen, liver, tibial bone marrow and sometimes popliteal lymph node were collected. These were processed as described by Abranches et al. (1982, 1983b).

Parasites were identified by direct microscopic examination of blood, bone marrow and

tissue impression smears. Some pieces of liver and spleen were fixed in 10% formol-saline and sent to England for histological examination (P. C. C. Garnham, Imperial College, Silwood Park, Ascot, Berkshire SL5 7PY, England). For vector studies, 51 ticks were collected and smears were prepared from their hemolymph.

Representative specimens of *Hepatozoon* sp. are deposited in the collection of the British Museum of Natural History (London SW7 5BD, England; accession numbers 1987.7.27.1–4).

### RESULTS

Of the 301 foxes examined, 143 (48%) were infected with *Hepatozoon* sp. Of the organs examined the number of foxes infected/the number examined for spleen, bone marrow, lymph node and blood were 131/138 (95%), 33/56 (59%), 7/17 (41%) and 44/125 (35%), respectively. Thus the spleen and the bone marrow were the most heavily parasitized organs. The parasites were mostly intracellular, but some occurred extracellularly in the spleen, liver and bone marrow.

In the blood, gametocytes were observed mostly inside neutrophils (Fig. 1). Occasionally, gametocytes were seen in other blood cells, but the large size of the parasite (8–12 × 4–6 μm) which often obscured the cell nucleus made correct identification of the host cell difficult. The gametocytes were the most frequently observed stage in all organs except for the bone marrow. They were morphologically identical to those of *H. canis* (Wenyon,

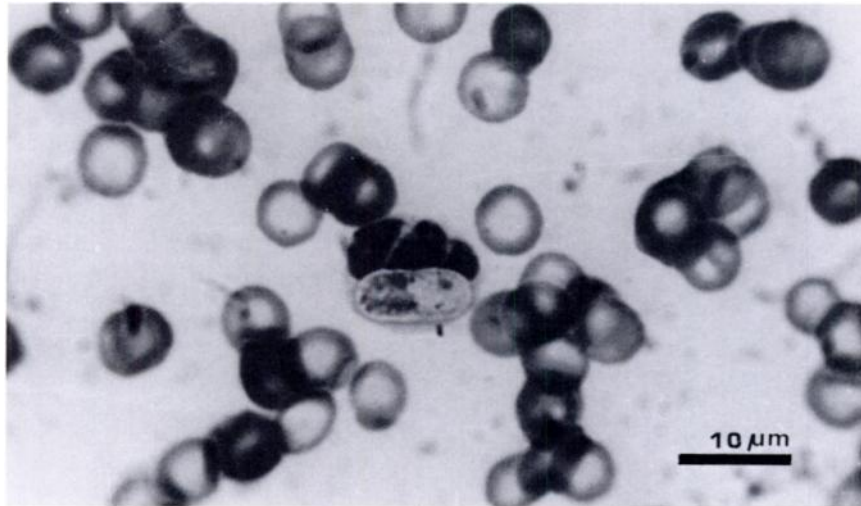


FIGURE 1. Gametocyte of *Hepatozoon* sp. in a neutrophil from a blood smear of the European fox.

1926; Soulsby, 1968; Levine, 1973). The schizonts were numerous in the bone marrow, but were scanty in the spleen and liver and were never observed in the blood. The schizonts in the bone marrow were predominantly oval and measured from  $15.8 \times 7.1 \mu\text{m}$  to  $10.3 \times 4.4 \mu\text{m}$ . The number of nuclei was not established (Fig. 2). On one liver impression smear, several extracellular curved merozoites were seen.

Histologically, two different kinds of schizonts were seen in the liver of the same

fox. There were immature schizonts ( $12 \mu\text{m}$ ) with four nuclei, as well as mature schizonts ( $16 \mu\text{m}$ ) with about 25 merozoites arranged peripherally and many others at different planes of the section resulting in a total number of  $\geq 100$ . Additionally, a ruptured schizont with about 12 merozoites (variable length but averaging  $5.8 \mu\text{m}$ ) with pointed ends and a sometimes eccentric nucleus was seen. The host cell was probably one of the reticuloendothelial series.

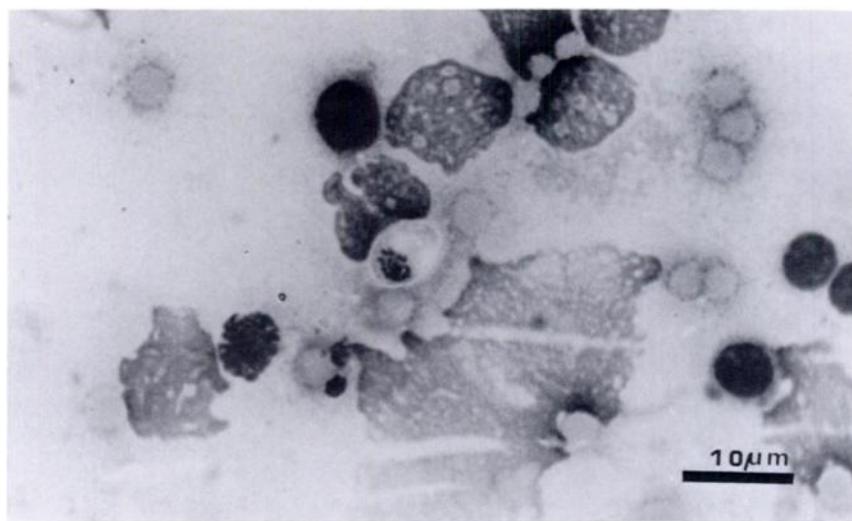


FIGURE 2. Schizont of *Hepatozoon* sp. in a bone marrow impression smear from the European fox.

Ticks collected in this study were identified as *Rhipicephalus sanguineus* (11 specimens), *R. pusillus* (26), *Ixodes festai* (8), *I. hexaporus* (4) and *I. ricinus* (2). In hemolymph smears from one tick, two gametocytes similar to those in the fox tissue were seen, but sporogonic forms of the parasite were not observed.

#### DISCUSSION

The parasite described in this study is similar to that described by Wenyon (1926) as *Hepatozoon canis*. Prior to this study, *Hepatozoon* sp. in foxes from Europe has been reported only in France (Rioux et al., 1968). *Hepatozoon* sp. was found also in *Vulpes bengalensis* from India (Rau, 1926), and more recently in *Vulpes vulpes schrenki* from Japan (Maede et al., 1982). The latter two authors suggested the parasite was *H. canis*.

The high prevalence of *Hepatozoon* sp. that we found in foxes (48%, 143 of 301) contrasts with the much lower prevalence in dogs (3%, 50 of 1,752) from the same area. The prevalence found in dogs was from examination of blood smears (for comparison, the prevalence in fox blood smears was 22% or 44 of 197). The difference was statistically significant ( $P < 0.001$ ) with chi-square analysis on prevalence data. This indicates that wild Canidae may be an important reservoir for this parasite as suggested by Davies et al. (1978). As a consequence of its peridomestic habits, the fox could represent a possible health hazard to domestic dog populations.

The pathogenicity of the *Hepatozoon* sp. remains controversial. Some authors suggest that this parasite is not very pathogenic (Rioux et al., 1964; McCully et al., 1975), while others report some cases of splenomegaly, progressive emaciation and in one case, lumbar paralysis (Levine, 1973). The prevalence of vulpine hepatozoonosis without clinical signs, even in the cases with concomitant infections (three with *Leishmania infantum* and one with microfilaria), suggests that this parasite is harmless to foxes.

The gametocyte in this parasite is the predominant form, observed in all organs with the least number seen in the bone marrow. Immature schizonts were numerous in the bone marrow, but were seen rarely in the spleen and liver. This infers that schizogony in fox infections occurs mainly in the bone marrow. In our experience all the schizonts observed in the bone marrow seemed to be at a similar developmental stage.

The search for *Hepatozoon* sp. in the ticks was unsuccessful. Examination of oocysts and sporocysts which is essential to determine the role of ticks as vectors of *Hepatozoon* sp. was not possible.

#### ACKNOWLEDGMENTS

We are very grateful to Malcolm W. Guy (Department of Tropical Hygiene of the London School of Hygiene and Tropical Medicine) for his critical review of this paper. We also wish to thank the protozoology technicians of the I.H.M.T., Maria Luisa Anselmo and João Ramada, for their valuable cooperation. We are grateful to P. C. C. Garnham for conducting the histological examinations of the organs from infected foxes. We would like to thank Travassos Santos Dias of the Centro de Zoologia from the Instituto de Investigação Científica e Tropical, Lisbon, for his valuable help in identifying the ticks.

This paper received financial support from the Instituto Nacional de Investigação Científica, Ministério da Educação e Cultura (Centro de Doenças Infecciosas e Parasitárias).

#### LITERATURE CITED

- ABRANCHES, P., F. M. CONCEIÇÃO-SILVA, M. M. S. RIBEIRO, F. J. LOPES, AND L. T. GOMES. 1983a. Kala-azar in Portugal. IV. The wild reservoir. The isolation of a *Leishmania* from a fox. Transactions of the Royal Society of Tropical Medicine and Hygiene 77: 420-421.
- , ———, AND M. C. D. SILVA-PEREIRA. 1984. Kala-azar in Portugal—V. The sylvatic cycle in the enzootic focus of Arrábida. Journal of Tropical Medicine and Hygiene 87: 197-200.
- , F. J. LOPES, P. S. FERNANDES, AND L. T. GOMES. 1982. Kala-azar in Portugal—I. Attempts to find a wild reservoir. Journal of Tropical Medicine and Hygiene 85: 123-126.
- , ———, F. M. C. SILVA, M. M. S. RIBEIRO, AND C. A. PIRES. 1983b. Le Kala-azar au Portugal. III. Résultats d'une enquête sur la leishmaniose canine réalisée dans les environs de Lis-

- bonne. Comparaison des zones urbaines et rurales. *Annales de Parasitologie Humaine et Comparée* 58: 307–315.
- CHRISTOPHERS, S. R. 1907. The sexual cycle of *Leucocytozoon canis* in the tick. Scientific Memoirs by Officers of the Medical and Sanitary Departments of the Government of India 28: 1–14.
- DAVIES, S. D., R. M. ROBINSON, AND T. M. CRAIG. 1978. Naturally occurring hepatozoonosis in a coyote. *Journal of Wildlife Diseases* 4: 244–246.
- LEVINE, N. D. 1973. Protozoan parasites of the domestic animals and of man, 2nd ed. Burgess Publishing Company, Minneapolis, Minnesota, pp. 256–257.
- MAEDE, Y., T. OHSUGI, AND N. OHOTAISHI. 1982. *Hepatozoon* infection in a wild fox (*Vulpes vulpes schrenki*) in Japan. *Japanese Journal of Veterinary Science* 44: 137–142.
- MCCULLY, R. M., P. A. BASSON, R. D. BIGALKE, V. DE VOS, AND E. YOUNG. 1975. Observations on naturally acquired hepatozoonosis of wild carnivores and dogs in the Republic of South Africa. *Onderstepoort Journal of Veterinary Research* 42: 117–134.
- RAU, M. 1926. Experimental infection of the jackal (*Canis aureus*) with *Piroplasma canis*. *Indian Journal of Medical Research* 14: 243–244.
- RIoux, J.-A., J. L. ALBARET, R. HOUIN, J. P. DEDET, AND G. LANOTTE. 1968. Ecologie des leishmanioses dans le sud de la France. 2—Les réservoirs selvatiques. Infestation spontanée du renard (*Vulpes vulpes* L.). *Annales de Parasitologie Humaine et Comparée* 43: 421–428.
- , Y. J. GOLVAN, AND R. HOUIN. 1964. Une observation d'infestation mixte à *Hepatozoon canis* (James, 1905) et *Leishmania "canis"* chez un chien de Sète (Hérault). *Annales de Parasitologie Humaine et Comparée* 39: 131–135.
- SOULSBY, E. J. L. 1968. Helminths, arthropods and protozoa of domesticated animals, 6th ed. Baillière, Tindall and Cassel, London, England, pp. 734–735.
- WENYON, C. M. 1926. Protozoology. Baillière, Tindall and Cox, London, England, pp. 1085–1092.

*Received for publication 6 January 1987.*