BioOne COMPLETE

Meningioma in a Woodchuck Exhibiting Central Vestibular Deficits

Authors: Podell, Michael, Pokras, Mark, Gerlach, Peter, and Jakowski, Richard

Source: Journal of Wildlife Diseases, 24(4) : 695-699

Published By: Wildlife Disease Association

URL: https://doi.org/10.7589/0090-3558-24.4.695

BioOne Complete (complete.BioOne.org) is a full-text database of 200 subscribed and open-access titles in the biological, ecological, and environmental sciences published by nonprofit societies, associations, museums, institutions, and presses.

Your use of this PDF, the BioOne Complete website, and all posted and associated content indicates your acceptance of BioOne's Terms of Use, available at www.bioone.org/terms-of-use.

Usage of BioOne Complete content is strictly limited to personal, educational, and non - commercial use. Commercial inquiries or rights and permissions requests should be directed to the individual publisher as copyright holder.

BioOne sees sustainable scholarly publishing as an inherently collaborative enterprise connecting authors, nonprofit publishers, academic institutions, research libraries, and research funders in the common goal of maximizing access to critical research.

Downloaded From: https://complete.bioone.org/journals/Journal-of-Wildlife-Diseases on 01 May 2024
Terms of Use: https://complete.bioone.org/terms-of-use

Journal of Wildlife Diseases, 24(4), 1988, pp. 695–699
© Wildlife Disease Association 1988

Meningioma in a Woodchuck Exhibiting Central Vestibular Deficits

Michael Podell,[1,3] Mark Pokras,[1] Peter Gerlach,[1] and Richard Jakowski,[2] Tufts University, School of Veterinary Medicine, Departments of [1] Wildlife Medicine and [2] Pathology, 200 Westboro Road, North Grafton, Massachusetts 01536, USA. [3] Address correspondence and reprint requests to Dr. Michael Podell, The Animal Medical Center, 510 East 62nd Street, New York, New York 10021, USA

ABSTRACT: An 11-yr-old captive-raised male woodchuck (*Marmota monax*) presented with ataxia, poor balance, left-sided weakness, circling to the left and nystagmus with the fast-phase directed towards the left. The clinical signs were compatible with a central vestibular deficit syndrome. Necropsy and histologic findings revealed a meningotheliomatous meningioma centered over the ventrolateral left pons and medulla along with acute bronchopneumonia, chronic glomerulopathy, interstitial nephritis, and phthisis bulbi.

Key words: Woodchuck, *Marmota monax*, meningioma, central vestibular deficits, bronchopneumonia, glomerulopathy, case history.

The woodchuck, or groundhog (*Marmota monax*: Rodentia; Sciuridae), ranges from the Atlantic coast of the United States and Newfoundland to northern Idaho and Alaska in North America. In addition, the woodchuck has been used successfully in the laboratory, especially as an animal model for hepatitis B virus (Fine et al., 1986). Thus, a significant amount of clinical and pathological data is available on captive woodchucks (Snyder, 1985). Meningioma has not been reported in this species. Herein we describe a woodchuck with a clinical presentation of central vestibular deficits with pathological findings of a meningotheliomatous meningioma, acute bronchopneumonia, chronic glomerulopathy, interstitial nephritis and phthisis bulbi.

On 21 July 1986 an 11-yr-old male woodchuck was presented to the Wildlife Clinic of Tufts University School of Veterinary Medicine (North Grafton, Massachusetts 01536, USA). Since being found orphaned at a young age, this woodchuck was raised at the Massachusetts Audubon Society Drumlin Farm in an indoor-outdoor pen that was accessible to children. Two mo prior to presentation, the animal experienced an acute episode of poor balance, circling and collapse with subsequent recovery. On the day before presentation, the woodchuck experienced a second, more severe episode.

Upon presentation, it exhibited ataxia, poor balance, non-purposeful limb movements, left-sided weakness, circling to the left and nystagmus with the fast-phase directed towards the left. A blood sample revealed a packed cell volume of 24%, total solids of 6.8 g/dl and marked hypochromasia of red cells with many target cells present. The white blood cell total count was 8,657 with a differential of 77% segmented neutrophils, 7% band neutrophils, 12% lymphocytes and 4% monocytes. These clinical pathology findings suggested the presence of a chronic, nonregenerative anemia with a left shift in the leukogram, indicating the presence of an infection. Abnormalities were not present on dorsoventral or lateral whole body radiographs. By the next day, the neurological status had deteriorated as evidenced by episodes of rolling and an inability to self-right from dorsal recumbency. Although the animal's appetite remained good, it exhibited dysphagia and subsequent respiratory problems. Considering the animal's advanced age and the severity of its problems, euthanasia was elected (6 ml intracardiac T-61® euthanasia solution, Hoechst-Roussel, Agri-Vet Company, Somerville, New Jersey 08876, USA). Necropsy was performed immediately after euthanasia. Tissue samples were fixed in 10% neutral buffered formalin solution.

Downloaded From: https://complete.bioone.org/journals/Journal-of-Wildlife-Diseases on 01 May 2024
Terms of Use: https://complete.bioone.org/terms-of-use

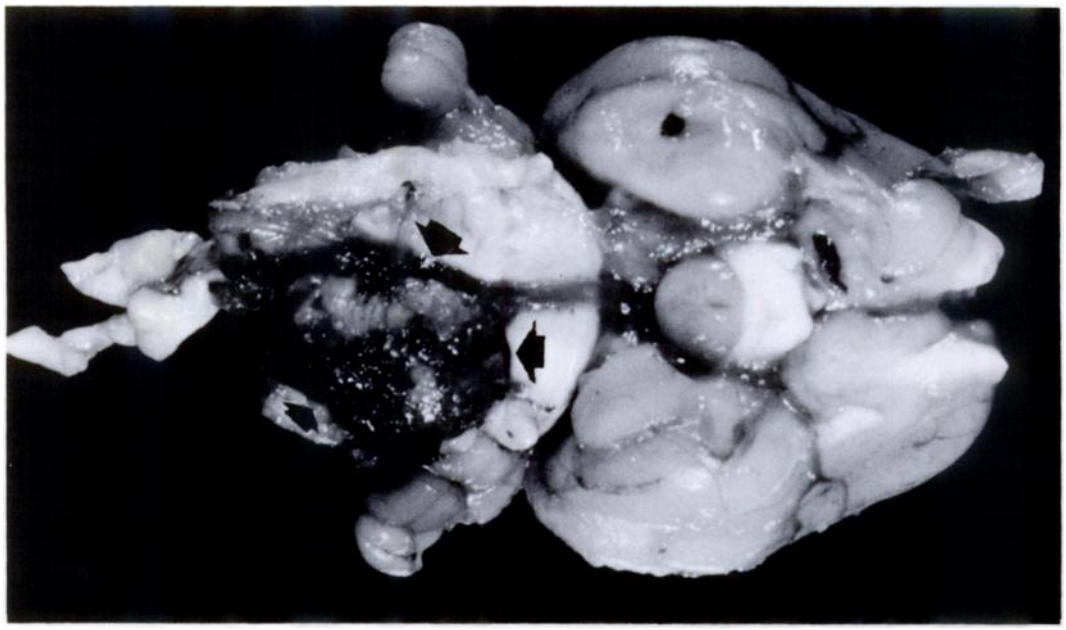

FIGURE 1. Ventral view of the dissected brain of a woodchuck demonstrating a subdural mass occupying the ventrolateral left pons and extending over the midline to compress the right side. Arrows indicate the borders of the mass. The dura mater has been removed.

Paraffin sections of multiple tissues were stained with hematoxylin and eosin (H&E).

Removal of the cranium revealed a subdural, circumscribed red-grey mass measuring 1.0 × 2.5 × 1.0 cm (Fig. 1). This mass was located adjacent to the left pons and medulla on the ventrolateral surface of the brainstem at the level of the vestibulocochlear nerve exiting from the rostral medulla (cranial nerve VIII). Transverse sections of the brain showed severe compression of the left rostral brainstem with the fourth ventricle compressed to the right of the midline. The eyes were grossly asymmetrical. The right eye measured 1.0 cm in diameter and 0.3 cm in length while the left eye was 1.8 cm and 0.6 cm, respectively. The right eye was without a lens and had no optic nerve connection. All lung lobes were mottled dark red-pink and air-filled. The liver was characterized by rounded edges, prominent reticular pattern and multifocal small, irregular nodules. Both kidneys exhibited cortical markings of tan-blue and were mottled red with multifocal raised regions that were cystic on section.

Microscopically, the subdural mass consisted of islands and packets of eosinophilic epithelioid cells with centrally located open nuclei (Fig. 2). The epithelioid cells appeared syncytial with indistinct cytoplasmic boundaries. Perilobular collagen was evident along with multiple focal collections of neutrophils and focal myeloid areas. Brain tissue underlying the mass showed marked compression atrophy. Numerous hemosiderin laden gitter cells surrounded the vascular base of the telachoroidea of the fourth ventricle. The morphologic diagnosis was meningotheliomatous meningioma of low grade malignancy.

An extensive alveolar neutrophilic infiltrate in the lungs accompanied by bronchiolar and alveolar fibrin exudate was diagnosed as an acute, diffuse and severe bronchopneumonia. Chronic interstitial nephritis and glomerulopathy were evidenced by abundant locally extensive lym-

Downloaded From: https://complete.bioone.org/journals/Journal-of-Wildlife-Diseases on 01 May 2024
Terms of Use: https://complete.bioone.org/terms-of-use

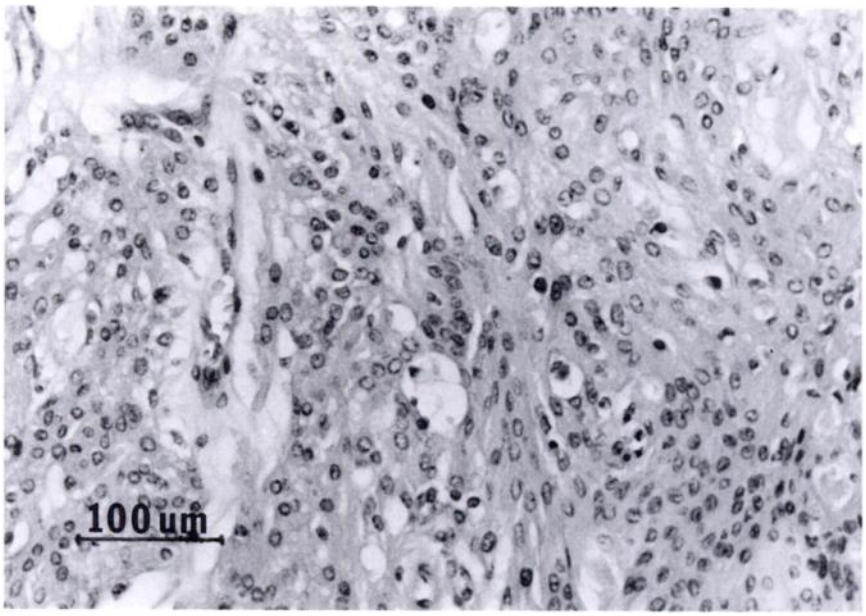

FIGURE 2. Photomicrograph of the tumor shown in Figure 1. Morphology varies from solid sheets of epitheliomatous cells to those with loosely arranged spindle-shaped morphology. H&E.

phocytic interstitial infiltrate, marked dilatation of the Bowman's space of many glomeruli, atrophy of glomerular tufts and proteinaceous filtrate filling the urinary space. Hepatic change was noted as diffuse, moderate centrilobular fatty degeneration.

The median lifespan of a colony of captive woodchucks has been reported to be about 4 yr although a maximum lifespan of 10 yr was recorded (Snyder, 1985). That this woodchuck lived to the advanced age of 11 yr is unusual. Not surprisingly, a range of lesions were identified.

Most prominent was the large meningotheliomatous meningioma located on the ventrolateral aspect of the left rostral brainstem. Unilateral involvement of the left vestibular nerve only would have resulted in a clinical presentation of a head and body tilt toward the lesion with a fast-phase component of nystagmus going away from the lesion. In this case, the head and body tilt was directed toward the side with the subdural mass (left); however, the fast-phase component was ipsilaterally directed. This presentation coupled with the histological evidence of compression atrophy of the left vestibular nuclei confirms a diagnosis of a central vestibular deficit. DeLahunta (1983) described this syndrome to include a nystagmus whose quick phase may change directions with changes in head position, ipsilateral hemiparesis and/or ataxia, a tendency to roll in one direction, dysphagia, and a weak jaw tone with atrophy of masticatory muscles. The clinical signs for this animal match this description in several respects, particularly the ipsilateral nystagmus and hemiparesis, ataxia, and dysphagia. The persistence of the head tilt directed toward the lesion rules out a central paradoxical vestibular disease characterized by a head tilt and ataxia opposite the side of the lesion (Palmer et al., 1974).

The extensive compression atrophy of the medulla centered at the level of the vestibular nerve and nuclei possibly led to degeneration of neural pathways from the trigeminal motor nucleus, the glossopharyngeal nucleus and nucleus ambiguous, to their respective cranial nerves responsible for mastication and swallowing. The

Downloaded From: https://complete.bioone.org/journals/Journal-of-Wildlife-Diseases on 01 May 2024
Terms of Use: https://complete.bioone.org/terms-of-use

resulting dysphagia may have predisposed the animal to multiple aspiration episodes, thus culminating in an acute, severe suppurative bronchopneumonia.

Meningiomas have been well documented in humans (Russell and Rubenstein, 1977), dogs (Patnaik et al., 1986), and cats (Nafe, 1979); sporadic cases are reported in other species (Owczarewicz and Pienkowski, 1972; Sreemannarayana and Christopher, 1977; Montali, 1980). While meningiomas can develop as mesothelial cell tumors from the cranial and spinal leptomeninges, intracranial meningiomas tend to predominate. In the cat, meningiomas are the most common central nervous system tumor reported (Nafe, 1979). In man, the majority of these tumors are topographically situated on the ventral aspect of the brain, most often as a spherical subdural mass that compresses underlying nervous tissue. A variety of histological patterns have been described in the literature. In man and domestic animals, meningotheliomatous (syncytial) and transitional (psammatous) are the most prevalent types reported (Russell and Rubenstein, 1977; Patnaik et al., 1986). Histologically, most meningiomas are benign.

Meningotheliomatous meningiomas were recently reported to be the second most prevalent histological pattern observed for intracranial meningiomas in dogs (Patnaik et al., 1986). However, brainstem location was a rare finding in this study, and also of those reported in cats (Nafe, 1979), and humans. Although no sex predilection was noted in dogs, males predominate in cats (Nafe, 1979) while there is a clear predominance for women to be affected (Russell and Rubenstein, 1977). An overwhelming majority of cats and dogs present with advanced neurological signs, while these are much less in humans. Montali (1980) has cited the finding of a meningioma in a captive degu (*Octodon degus*), also a rodent.

Findings of a chronic interstitial, lymphocytic nephritis and severe glomerulopathy are not unusual considering the age of this woodchuck. In dogs, chronic interstitial nephritis represents the end result of chronic glomerulonephritis (Jones and Hunt, 1983). Several forms of glomerulonephritis exist, none of which have been singled out as most often responsible for the chronicity of the lesion. Membranous glomerulonephritis has been reported to be the most frequent cause of the nephrotic syndrome in humans, and often presents with an insidious and prolonged course in domestic animals (Wright et al., 1976). In captive woodchucks, Snyder (1985) reported pyelonephritis as being the most common infectious disease noted at necropsy.

The shrunken right eyeball (phthisis bulbi) noted most likely resulted from a recurrent inflammatory process, possibly secondary to trauma. The unilateral nature of the problem along with histopathological evidence of a degenerative retina argue against the likelihood of a congenital defect or environmental (nutritional deficiency) etiology.

Persistent infection from an early age with woodchuck hepatitis virus is highly correlated with the development of hepatocellular carcinoma (HCa) in woodchucks (Tyler et al., 1981). Chronic active hepatitis is a strong indicator for HCa to follow (Snyder, 1985). In this same article, HCa was found to be the most common cause of death in a colony setting. Surprisingly, no evidence of hepatitis nor HCa was noted in this case.

We would like to thank Kathy Nowell and the staff of the Massachusetts Audubon Society's Drumlin Farm for their cooperation in documenting this animal's history.

LITERATURE CITED

DeLahunta, A. 1983. Veterinary neuroanatomy and clinical neurology, 2nd ed. W. D. Saunders Company, Philadelphia, Pennsylvania, 471 pp.

Fine, J., F. W. Quimby, and D. D. Greenhouse. 1986. Annotated bibliography on uncommonly used laboratory animals: Mammals. ILAR News 29: 19A–21A.

Jones, T. C., and R. D. Hunt. 1983. Veterinary

Downloaded From: https://complete.bioone.org/journals/Journal-of-Wildlife-Diseases on 01 May 2024
Terms of Use: https://complete.bioone.org/terms-of-use

pathology, 5th ed. Lea and Febiger, Philadelphia, Pennsylvania, 1792 pp.

MONTALI, R. J. 1980. An overview of tumors in zoo animals. *In* The comparative pathology of zoo animals, R. J. Montali and G. Migaki (eds.). Smithsonian Institution Press, Washington, D.C., pp. 532–542.

NAFE, L. A. 1979. Meningiomas in cats: A retrospective clinical study of 39 cases. Journal of the American Veterinary Medical Association 174: 1224–1227.

OWCZAREWICZ, A., AND M. PIENKOWSKI. 1972. Fibroblastic meningioma in a cow. Medical Weterynarian 28: 243.

PALMER, A. C., W. MALINOWSKI, AND K. C. BARRETT. 1974. Clinical signs including papilloedema associated with brain tumours in twenty-one dogs. Journal of Small Animal Practice 15: 359–367.

PATNAIK, A. K., W. J. KAY, AND A. I. HURVITZ. 1986. Intracranial meningioma: A comparative pathologic study of 28 dogs. Veterinary Pathology 23: 369–373.

RUSSELL, D. C., AND L. J. RUBENSTEIN. 1977. Pathology of tumours of the nervous system, 4th ed. The Williams and Wilkins Co., Baltimore, Maryland, 448 pp.

SNYDER, R. L. 1985. The laboratory woodchuck. Lab Animal 23: 20–30.

SREEMANNARAYANA, O., AND K. J. CHRISTOPHER. 1977. Meningioma in a ewe. Indian Veterinary Journal 54: 225–226.

TYLER, G. V., J. W. SUMMERS, AND R. L. SNYDER. 1981. Woodchuck hepatitis virus in natural woodchuck populations. Journal of Wildlife Diseases 17: 297–301.

WRIGHT, N. G., E. W. FISHER, W. I. MORRISON, W. B. THOMSON, AND A. S. NASH. 1976. Chronic renal failure in dogs: A comparative clinical and morphological study of chronic glomerulonephritis and chronic interstitial nephritis. Veterinary Record 98: 288–293.

Received for publication 4 November 1987.

Downloaded From: https://complete.bioone.org/journals/Journal-of-Wildlife-Diseases on 01 May 2024
Terms of Use: https://complete.bioone.org/terms-of-use