

New Information on the Location of *Capillaria procyonis* (Nematoda: Trichuroidea) in the Tongue of a Raccoon (*Procyon lotor*)

Author: Snyder, Daniel E.

Source: Journal of Wildlife Diseases, 25(2) : 294-296

Published By: Wildlife Disease Association

URL: <https://doi.org/10.7589/0090-3558-25.2.294>

The BioOne Digital Library (<https://bioone.org/>) provides worldwide distribution for more than 580 journals and eBooks from BioOne's community of over 150 nonprofit societies, research institutions, and university presses in the biological, ecological, and environmental sciences. The BioOne Digital Library encompasses the flagship aggregation BioOne Complete (<https://bioone.org/subscribe>), the BioOne Complete Archive (<https://bioone.org/archive>), and the BioOne eBooks program offerings ESA eBook Collection (<https://bioone.org/esa-ebooks>) and CSIRO Publishing BioSelect Collection (<https://bioone.org/csiro-ebooks>).

Your use of this PDF, the BioOne Digital Library, and all posted and associated content indicates your acceptance of BioOne's Terms of Use, available at www.bioone.org/terms-of-use.

Usage of BioOne Digital Library content is strictly limited to personal, educational, and non-commercial use. Commercial inquiries or rights and permissions requests should be directed to the individual publisher as copyright holder.

BioOne is an innovative nonprofit that sees sustainable scholarly publishing as an inherently collaborative enterprise connecting authors, nonprofit publishers, academic institutions, research libraries, and research funders in the common goal of maximizing access to critical research.

New Information on the Location of *Capillaria procyonis* (Nematoda: Trichuroidea) in the Tongue of a Raccoon (*Procyon lotor*)

Daniel E. Snyder, United States Department of Agriculture, Agricultural Research Service, Animal Parasite Research Laboratory, P.O. Box 952, Auburn, Alabama 36831, USA

ABSTRACT: Histologic examination of the tongue of one juvenile male raccoon demonstrated the presence of adults and unembryonated eggs of the nematode *Capillaria procyonis* within parasite-induced tunnels in the stratified squamous epithelium. There was no inflammatory infiltrate within the epithelium or the subjacent lamina propria. The shape of tunnels approximated that of the resident nematodes and were lined by flattened and attenuated epithelial cells. Therefore, the site of infection of *C. procyonis* in the raccoon includes the oral, lingual and pharyngeal epithelium in addition to the esophagus.

Key words: Raccoon, *Procyon lotor*, *Capillaria procyonis*, tongue, pathology.

Capillaria procyonis was originally described by Pence (1975) from the esophagus of raccoons (*Procyon lotor*) in Louisiana (USA). Recently, Snyder (1988) demonstrated unembryonated capillariid-type eggs in sediment from 1% pepsin-HCl digests of the tongue of raccoons in central Illinois (USA). Although adult parasites were not recovered from these digests, based on measurements and surface topography, the eggs were tentatively identified as those of *C. procyonis*.

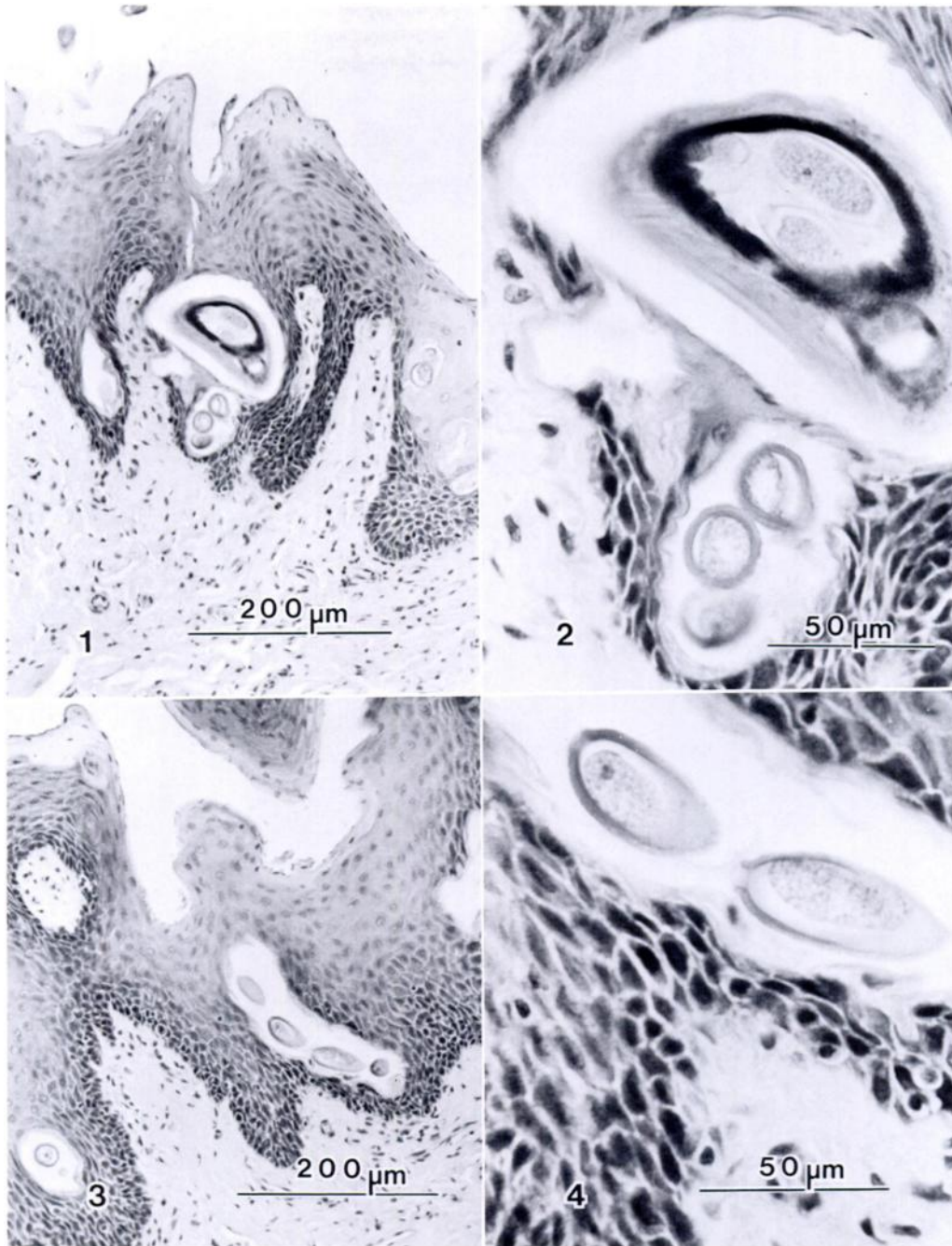
This paper describes the presence of adult parasites and eggs of *C. procyonis* as seen histologically in the epithelial lining of the tongue of a raccoon. A portion of tongue from a juvenile male raccoon, fixed in 10% neutral buffered formalin and stored since January 1986, was processed by routine methods for histopathologic examination. This animal was obtained in Farmington, Fulton County, Illinois (40°42'N, 90°00'W; Snyder, 1987).

Examination of the tongue revealed numerous sections of adult nematodes and unembryonated eggs similar to those of *Capillaria* spp. within tunnels in the stratified squamous epithelium (Figs. 1–4).

Histological sections of parasites were often located in tunnels in close association with the lamina propria; however, an inflammatory infiltrate was not seen within the epithelium or the subjacent lamina propria. The shape of the tunnels approximated that of the resident nematodes and were lined by flattened and attenuated epithelial cells (Figs. 1, 2). The walls of tunnels also were often lined by a narrow border of amorphous, eosinophilic material (Figs. 3, 4); the origin of this material was not determined. Adult parasites and eggs either bluntly dissected or scraped from the surface of the fixed tongue were similar to previous descriptions of *C. procyonis* (Pence, 1975; Butterworth and Beverley-Burton, 1980; Snyder, 1988). Representative specimens of this parasite have been deposited in the U.S. National Parasite Collection (Beltsville, Maryland 20705, USA; accession number 80442).

Scapino and Murphy (1978) found a capillariid-like nematode and its eggs similar to *C. procyonis* within tunnels in the mandibular lingual epithelium of one raccoon in Kentucky (USA). Similar parasites also have been seen histologically in the lingual, pharyngeal and tonsillar crypt epithelium of raccoons in Pennsylvania and Ohio (A. N. Hamir, pers. comm.). Based on these results, the site of infection of *C. procyonis* in the raccoon includes the oral, lingual and pharyngeal epithelium in addition to the esophagus.

Moravec (1982) has proposed a new systematic arrangement of nematodes of the family Capillariidae. Based on this proposed rearrangement, *C. procyonis* is reclassified as *Eucoleus procyonis*; however, until more detailed information on morphological differences and life history pat-



FIGURES 1–4. Histologic demonstration of *Capillaria procyonis* in the stratified squamous epithelium of the tongue of a raccoon. H&E. 1. Sections of *C. procyonis* within parasite-induced tunnels in the stratum corneum. 2. Higher magnification of Figure 1. Cross section of female nematode containing eggs. 3. Eggs of *C. procyonis* in parasite-induced tunnel in epithelium. 4. Higher magnification of Figure 3 demonstrating unembryonated eggs of *C. procyonis* within parasite-induced tunnel.

terns for this group of parasites is determined, this author prefers to use the genus name *Capillaria*.

The author is grateful to Glen C. Sanderson, Illinois Natural History Survey, Champaign, Illinois, for his assistance in obtaining specimens.

LITERATURE CITED

- BUTTERWORTH, E. W., AND M. BEVERLEY-BURTON. 1980. The taxonomy of *Capillaria* spp. (Nematoda: Trichuroidea) in carnivorous mammals from Ontario, Canada. *Systematic Parasitology* 1: 211-236.
- MORAVEC, F. 1982. Proposal of a new systematic arrangement of nematodes of the family Capillariidae. *Folia Parasitologica (Praha)* 29: 119-132.
- PENCE, D. B. 1975. *Capillaria procyonis* sp. n. (Nematoda: Trichuridae) from the esophagus of the raccoon, *Procyon lotor*. *The Journal of Parasitology* 61: 815-818.
- SCAPINO, R. P., AND R. A. MURPHY. 1978. Nematode from the masticatory mucosa of the raccoon (*Procyon lotor*). *Veterinary Pathology* 15: 136-137.
- SNYDER, D. E. 1987. Prevalence and intensity of *Trichinella spiralis* infection in Illinois wildlife. *The Journal of Parasitology* 73: 874-875.
- . 1988. *Capillaria procyonis* (Nematoda: Trichuroidea) eggs from the tongue of the raccoon (*Procyon lotor*). *Journal of Wildlife Diseases* 24: 722-723.

Received for publication 7 September 1988.