

Physaloptera retusa (Nematoda, Physalopteridae) in Naturally Infected Sagebrush Lizards, *Sceloporus graciosus* (Iguanidae)

Authors: Goldberg, Stephen R., and Bursey, Charles R.

Source: Journal of Wildlife Diseases, 25(3) : 425-429

Published By: Wildlife Disease Association

URL: <https://doi.org/10.7589/0090-3558-25.3.425>

The BioOne Digital Library (<https://bioone.org/>) provides worldwide distribution for more than 580 journals and eBooks from BioOne's community of over 150 nonprofit societies, research institutions, and university presses in the biological, ecological, and environmental sciences. The BioOne Digital Library encompasses the flagship aggregation BioOne Complete (<https://bioone.org/subscribe>), the BioOne Complete Archive (<https://bioone.org/archive>), and the BioOne eBooks program offerings ESA eBook Collection (<https://bioone.org/esa-ebooks>) and CSIRO Publishing BioSelect Collection (<https://bioone.org/csiro-ebooks>).

Your use of this PDF, the BioOne Digital Library, and all posted and associated content indicates your acceptance of BioOne's Terms of Use, available at www.bioone.org/terms-of-use.

Usage of BioOne Digital Library content is strictly limited to personal, educational, and non-commercial use. Commercial inquiries or rights and permissions requests should be directed to the individual publisher as copyright holder.

BioOne is an innovative nonprofit that sees sustainable scholarly publishing as an inherently collaborative enterprise connecting authors, nonprofit publishers, academic institutions, research libraries, and research funders in the common goal of maximizing access to critical research.

***Physaloptera retusa* (Nematoda, Physalopteridae) in Naturally Infected Sagebrush Lizards, *Sceloporus graciosus* (Iguanidae)**

Stephen R. Goldberg¹ and Charles R. Bursey,² ¹ Department of Biology, Whittier College, Whittier, California 90608, USA; ² Department of Biology, Pennsylvania State University, Shenango Valley Campus, Sharon, Pennsylvania 16146, USA

ABSTRACT: Of 292 adult sagebrush lizards (*Sceloporus graciosus*) examined for the stomach nematode, *Physaloptera retusa*, 81 (28%) were infected. Attached nematodes caused erosive inflammatory foci in the stomach mucosa. Early lesions were U-shaped. Degenerating gastric glands occurred in the adjacent mucosa. Healed lesions were fibrous connective tissue scars; regenerating gastric glands occurred at the periphery. There were no externally visible signs of infection.

Key words: Nematoda, *Physaloptera retusa*, lizard, *Sceloporus graciosus*, inflammation, stomach, histopathology.

Species of the nematode family Physalopteridae live in the stomach or intestines of all classes of vertebrates. They attach to the mucosa and can cause gastritis, enteritis and excess mucous secretion (Levine, 1980). Over 150 species of *Physaloptera* have been described (Schmidt and Roberts, 1985). However, within the United States, reptiles have been reported as definitive hosts of only four species: *P. abjecta*, *P. obtusissima*, *P. retusa* and *P. squamatae*. There is apparently only one publication on the histopathology of adult *Physaloptera* spp. infections in reptiles. Pearce and Tanner (1973) described *P. retusa* as always located in the first third of the stomach with the head deeply buried in the mucosa; necrosis was not reported. In addition, Widmer (1970) described lesions caused by third stage *Physaloptera rara* larvae in the western rattlesnake (*Crotalus viridis*), a paratenic host. In this paper we present a second report of *P. retusa* from the stomach of the sagebrush lizard (*Sceloporus graciosus*).

Adult sagebrush lizards were collected on Windy Gap Trail (elevation 1,889 m; 34°21'N, 117°48'W) in the Crystal Lake area of the San Gabriel Mountains, Los Angeles County, California by noosing

during the month of May in 1986, 1987 and 1988 ($n = 292$; 86, 36, 170, respectively). Males and females, respectively, by year of collection were 53 and 33 in 1986, 29 and seven in 1987 and 91 and 79 in 1988. Thirty-two juveniles were collected in 1988 from the same locality. The lizards were decapitated, their stomachs opened and the number of nematodes, if any, was recorded. Stomachs and nematodes were preserved in neutral, buffered 10% formalin. Glycerol mounts of nematodes were examined microscopically to determine sex and stage of development. Representative stomach tissues were later embedded in paraffin, sectioned at 6 μm and stained with Harris' hematoxylin and eosin or Masson's trichrome connective tissue stain. Six adult nematode specimens (three males, three females) have been deposited in the U.S. National Parasite Collection (Beltsville, Maryland 20705, USA; accession number 80405).

The stomachs contained *P. retusa* which was often firmly attached to the mucosa such that it could only be dislodged with force. Attached nematodes caused an erosion of the surface epithelium (Fig. 1) which reached as deep as the muscularis mucosa and resulted in up to total loss of gastric glands at the region of attachment. There was an associated active multifocal fibrosing gastritis in the mucosa. The average mucosa thickness was 250 μm . These lesions varied in shape; early ones tended to be U-shaped with a depth of about 50 μm and a length of approximately 140 μm . This somewhat elongated shape resulted from the position assumed by *P. retusa* for feeding. The interior of an early lesion was mildly edematous and contained fibrin strands. The advancing edge of the lesion

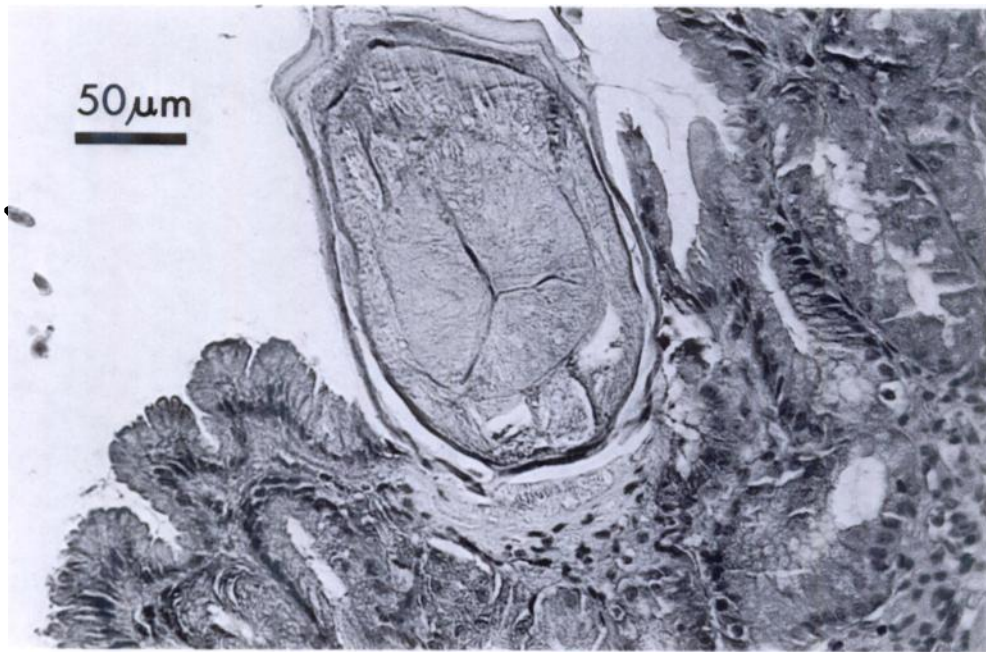


FIGURE 1. Histological section through the esophagus of an adult *Physaloptera retusa*. Nematode has caused an erosive inflammatory lesion in the gastric mucosa of a sagebrush lizard. Note localized atrophy. H&E.

was bordered by several rows of fibroblasts and a mixed inflammatory response consisting of heterophils, histiocytes and a few lymphocytes. Occasional multinucleate giant cells were noted. Degenerating gastric glands (from compression atrophy) were commonly observed adjacent to early lesions. An area of focal necrosis was sometimes seen where the head of *P. retusa* had been in contact with the mucosa.

Fibrous scars resulting from healed lesions were also noted (Fig. 2). They were approximately 100 μ m in diameter. Fibrocytes and thick connective tissue fibers were very apparent within these resolving scars. Some of the fibers stained positive for collagen with Masson's trichrome stain. Heterophils and histiocytes were noted around the scar. The number of regenerating glands increased on the periphery of the scar as healing progressed.

Of 292 adult sagebrush lizards examined during 1986 through 1988, 81 (28%) were infected with *P. retusa*. Prevalence in males and females, respectively by year

of collection, was: 25 and 39% in 1986, 31 and 0% in 1987 and 38 and 14% in 1988. More females were infected than males in 1986; the reverse was true in 1987 and 1988. The observed and expected frequencies of infection in males and females were significantly different ($\chi^2 = 36.54$, 2 df, $P < 0.001$). Mean intensity in adult males and females, respectively by year of collection, was: 4.6 and 2.0 in 1986, 4.1 and 0 in 1987 and 5.3 and 2.9 in 1988. There was a significant difference between male and female intensities (Kruskal-Wallis test, $j = 3.85$, 1 df, $P < 0.05$; Eckblad, 1984). A total of 147 *P. retusa* were collected from adult sagebrush lizards in 1988 (89 male, 17 female, 41 third stage larvae).

Thirty-two juvenile lizards (30 to 44 mm snout-vent length (SVL)) collected in 1988 were also examined; two (6%) were infected. The smallest infected juvenile measured 35 mm SVL; mean intensity was 1.5. Three worms were collected from juveniles (two males, one female).

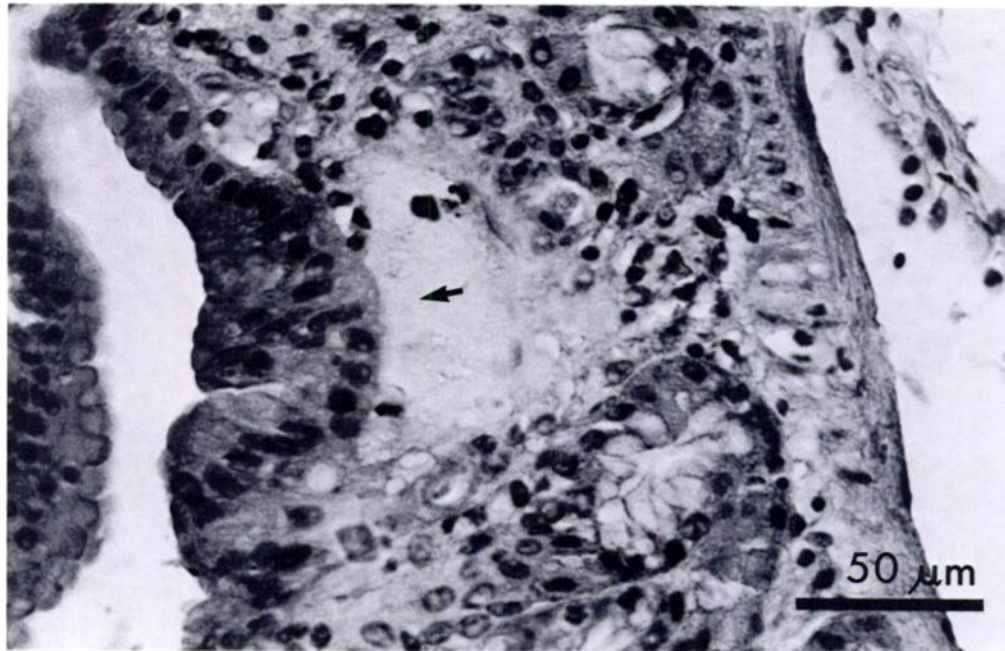


FIGURE 2. Fibrous scar (arrow) from previous attachment of adult *Physaloptera retusa*. Note absence of gastric glands. H&E.

The relationship between the number of *P. retusa* in each host and SVL of the host was examined for the 46 infected adult lizards (35 males, 11 females) collected in 1988. The correlation was not significant (linear correlation coefficient, $r = 0.11$, $P > 0.1$ and $r = 0.47$, $P > 0.1$ for males and females, respectively).

Species of the genus *Physaloptera* occur in the stomach of a variety of terrestrial vertebrates. Although it is unknown for *P. retusa*, the life cycles of several related species have been studied. These include *P. hispida* (Schell, 1952), *P. rara* and *P. praeputialis* (Petri and Ameel, 1950), and *P. maxillaris* (Hobmaier, 1941; Lincoln and Anderson, 1975). Insects scavenging fecal material ingest eggs which hatch in their gut then migrate into body tissue for subsequent development to third stage larvae. These larvae are infective to both definitive and paratenic hosts. Third stage larvae have been recovered from invertebrate and vertebrate hosts including earwigs (*Labidura reparia* and *Forficula auricularia*)

(Basir, 1948; Schell, 1952), camel crickets (*Ceuthophilus* sp.) (Petri and Ameel, 1950), field crickets (*Gryllus assimilis* and *Acheta pennsylvanicus*) (Zago Filho, 1959; Cawthorn and Anderson, 1976), grasshoppers (*Orphulella punctata*, *Eutryxalis filata* and *Dichroplus punctulatus*) (Zago, 1959), German cockroaches (*Blatella germanica*) (Petri, 1950), flour beetles (*Tribolium confusum*) (Petri and Ameel, 1950), ground beetles (*Harpalus* sp.) (Schell, 1952), ruffed grouse (*Bonasa umbellus*) (Boughton, 1935) and prairie rattlesnakes (*Crotalus viridis*) (Widmer, 1970). Vertebrates with encysted *Physaloptera* spp. are probably paratenic hosts.

We have observed a variety of insects in sagebrush lizard stomachs including ants, wasps, hemiptera, lepidoptera larvae, beetles, flies and grasshoppers. They are also known to eat spiders, mites, scorpions and ticks (Stebbins, 1985). It is not known which of these might serve as intermediate hosts for *P. retusa*. The difference in prevalence and intensities of nematode infections re-

ported here may suggest dietary differences for males, females and juveniles.

The effects of *P. retusa* on the sagebrush lizard population under study are not known. Testes were enlarged, epididymides contained sperm, and ovarian follicles were yellow (yolked) indicating that the lizards were reproductively active (Goldberg, 1975). No external symptoms of nematode infection were observed. Pearce and Tanner (1973) examined *P. retusa* infections in *Sceloporus magister*, *S. occidentalis* and *S. undulatus* and concluded effects of this parasite were negligible.

Physaloptera retusa has been reported previously from sagebrush lizards in southern Utah (Woodbury, 1934). To date the sagebrush lizard has been reported as the definitive host of only four nematode species including *Atractis penneri* (Pearce and Tanner, 1973), *Physaloptera retusa*, *Skrjabinoptera phrynosoma* (Stebbins and Robinson, 1946) and *Spauligodon giganticus* (Telford, 1970; White and Knapp, 1979). Our study is the second report of *P. retusa* from this host.

We thank S. Cohen (Southern California Permanente Medical Group), D. D. Porter (Department of Pathology, University of California at Los Angeles, School of Medicine), J. O. Britt and especially H. J. Holshuh (Comparative Medical and Veterinary Services, County of Los Angeles) for discussions on histopathology. T. A. Beinz assisted with field work and S. Belkin helped with figures.

LITERATURE CITED

- BASIR, M. A. 1948. On a *Physaloptera* larva from an insect. Canadian Journal of Research D 26: 197-200.
- BOUGHTON, R. V. 1935. Endoparasitic infestations in grouse, their pathogenicity and correlation with metero-topographical conditions. Ph.D. Dissertation. University of Minnesota, Minneapolis, Minnesota, 50 pp.
- CAWTHORN, R. J., AND R. C. ANDERSON. 1976. Effects of age, temperature, and previous infection on the development of *Physaloptera maxillaris* (Nematoda: Physalopteroidea) in field crickets (*Acheta pennsylvanicus*). Canadian Journal of Zoology 54: 442-448.
- ECKBLAD, J. 1984. Key-stat: An integrated series of statistical programs. Oakleaf Systems, Decorah, Iowa, 10 pp.
- GOLDBERG, S. R. 1975. Reproduction in the sagebrush lizard, *Sceloporus graciosus*. The American Midland Naturalist 93: 177-187.
- HOBMAIER, M. 1941. Extramammalian phase of *Physaloptera maxillaris* Molin, 1860 (Nematoda). The Journal of Parasitology 27: 233-235.
- LEVINE, N. D. 1980. Nematode parasite of domestic animals and of man. Burgess Publishing Company, Minneapolis, Minnesota, 477 pp.
- LINCOLN, R. C., AND R. C. ANDERSON. 1975. Development of *Physaloptera maxillaris* (Nematoda) in the common field cricket (*Gryllus pennsylvanicus*). Canadian Journal of Zoology 53: 385-390.
- PEARCE, R. C., AND W. W. TANNER. 1973. Helminths of *Sceloporus* lizards in the Great Basin and Upper Colorado Plateau of Utah. The Great Basin Naturalist 33: 1-18.
- PETRI, L. H. 1950. Life cycle of *Physaloptera rara* Hall and Wigdor, 1918 (Nematoda: Spiruroidea) with the cockroach, *Blattella germanica*, serving as the intermediate host. Transactions of the Kansas Academy of Science 53: 331-337.
- , AND D. J. AMEEL. 1950. Studies on the life cycle of *Physaloptera rara* Hall and Wigdor, 1918, and *Physaloptera praeputialis* Linstow, 1889. The Journal of Parasitology 36: 40 (supplement).
- SCHELL, S. C. 1952. Studies on the life cycle of *Physaloptera hispida* Schell (Nematoda: Spiruroidea) a parasite of the cotton rat (*Sigmodon hispidus littoralis* Chapman). The Journal of Parasitology 38: 462-472.
- SCHMIDT, G. D., AND L. S. ROBERTS. 1985. Foundations of parasitology. Mosby Publishing Company, St. Louis, Missouri, 775 pp.
- STEBBINS, R. C. 1985. A field guide to western reptiles and amphibians. Houghton-Mifflin Company, Boston, Massachusetts, 336 pp.
- , AND H. B. ROBINSON. 1946. Further analysis of a population of the lizard *Sceloporus graciosus gracilis*. University of California Publications in Zoology 48: 149-168.
- TELFORD, S. R. 1970. A comparative study of endoparasitism among some southern California lizard populations. American Midland Naturalist 83: 516-554.
- WHITE, R. L., II, AND S. E. KNAPP. 1979. Helminth parasites of sceloporine (Iguanidae) lizards from central Oregon. Proceedings of the Helminthological Society of Washington 46: 270-272.
- WIDMER, E. A. 1970. Development of third-stage *Physaloptera* larvae from *Crotalus viridis* Rafi-

- nesque, 1818 in cats with notes on pathology of the larvae in the reptile (Nematoda, Spiruroidea). *Journal of Wildlife Diseases* 6: 89–93.
- WOODBURY, L. A. 1934. Notes on some parasites of three Utah reptiles. *Copeia* 1934: 51–52.
- ZAGO FILHO, H. 1959. Os gafanhotos como hospedeiros intermediários de *Physaloptera praeputialis* Linst., 1889 e da *Turgida turgida* (Rud. 1819) Trav., 1920 (Nematoda, Spiruroidea). *Brazil Biological Review* 19: 9–12.

Received for publication 6 October 1988.