



Sarcocystis sp. in Mountain Goats (*Oreamnos americanus*) in Washington: Prevalence and Search for the Definitive Host

Author: Foreyt, William J.

Source: Journal of Wildlife Diseases, 25(4) : 619-622

Published By: Wildlife Disease Association

URL: <https://doi.org/10.7589/0090-3558-25.4.619>

BioOne Complete (complete.BioOne.org) is a full-text database of 200 subscribed and open-access titles in the biological, ecological, and environmental sciences published by nonprofit societies, associations, museums, institutions, and presses.

Your use of this PDF, the BioOne Complete website, and all posted and associated content indicates your acceptance of BioOne's Terms of Use, available at www.bioone.org/terms-of-use.

Usage of BioOne Complete content is strictly limited to personal, educational, and non - commercial use. Commercial inquiries or rights and permissions requests should be directed to the individual publisher as copyright holder.

BioOne sees sustainable scholarly publishing as an inherently collaborative enterprise connecting authors, nonprofit publishers, academic institutions, research libraries, and research funders in the common goal of maximizing access to critical research.

***Sarcocystis* sp. in Mountain Goats (*Oreamnos americanus*) in Washington: Prevalence and Search for the Definitive Host**

William J. Foreyt, Department of Veterinary Microbiology and Pathology, Washington State University, Pullman, Washington 99164, USA

ABSTRACT: During October and November 1986, *Sarcocystis* sp. was detected in 24 of 56 (43%) tongues from hunter-killed mountain goats (*Oreamnos americanus*) in Washington (USA). Sarcocysts had an unusual sessile polyp-shaped branched wall. Mean size of 154 sarcocysts was $71.3 \times 37.8 \mu\text{m}$ (range, 20 to 248×10 to $120 \mu\text{m}$), and the mean intensity was 2.3 (range, 1 to 28). In an attempt to identify the definitive host, infected tongues were fed to four coyotes (*Canis latrans*), eight domestic dogs, four domestic cats, three bears (*Ursus americanus*), two raccoons (*Procyon lotor*), two martens (*Martes americana*), two fishers (*Martes pennanti*), three skunks (*Mephitis mephitis*), five mink (*Mustela vison*), five ferrets (*Mustela putorius*), one pig-tail macaque (*Macaca nemestrina*), two red-tailed hawks (*Buteo jamaicensis*) and one great horned owl (*Bubo virginianus*). Oocysts or sporocysts were not detected in the feces of any host for ≤ 20 days after ingestion of the infected meat. The definitive host for *Sarcocystis* sp. in mountain goats was not identified.

Key words: *Sarcocystis* sp., mountain goat, *Oreamnos americanus*, prevalence, definitive host, experimental infections.

Sarcocystis spp. of ruminants are obligate two-host parasites that are commonly detected as sarcocysts in striated muscles (Dubey, 1976; Frenkel et al., 1979; Levine and Tadros, 1980; Levine, 1986; Levine and Ivens, 1986; Dubey et al., 1988). Carnivorous animals are definitive hosts that complete the life cycle by ingesting sarcocysts in infected meat. Ruminant intermediate hosts become infected by ingesting sporulated oocysts or sporocysts from the feces of infected carnivores.

Although *Sarcocystis* spp. have been described from a variety of wild ruminants (Dubey et al., 1988), there is only a single survey of *Sarcocystis* sp. in mountain goats (*Oreamnos americana*). In the one survey in Alberta (Canada), 11 of 15 mountain goats were infected, but details regarding the sarcocysts were not reported (Mahrt

and Colwell, 1980). The present study was undertaken to determine the prevalence and intensity of *Sarcocystis* sp. in mountain goats in Washington (USA), and an attempt was made to determine its definitive host.

Prior to the mountain goat hunting season in 1986 in the state of Washington, all modern firearms hunters with permits ($n = 200$) were sent a letter requesting the tongue from their goat if they were successful in killing a goat. Hunters were asked to chill the tongue on ice and send the tongue with an ice pack by priority mail or bus to Washington State University (Pullman, Washington 99164, USA). When tongues were received, sections approximately $1.5 \times 1.5 \times 0.5$ cm were removed from the dorsal anterior one-third and from the dorsal posterior one-third of the tongue for the histological sectioning, and the remaining parts of the tongue were stored at 4 C. Tongues were examined for sarcocysts the same day they were received after processing the tissues with a rapid freeze stain technique. The sections of tongue were mounted on brass chucks with Tissue-Tek O.C.T. compound (Miles Laboratories, Inc., Elkhart, Indiana 46515, USA), frozen at -30 C for 3 to 4 min, sectioned at $6 \mu\text{m}$, and mounted on a subslide with potassium dichromate and gelatin. Tissues were then fixed in a mixture of methanol (25 ml), formaldehyde (15 ml) and acetic acid (6 drops) for 3 to 4 min, and then stained with Mayer's hematoxylin for 3 min and eosin for 15 sec. Prepared tissues were examined microscopically at $100\times$ and the number of sarcocysts per cm^2 was determined. Length and width of sarcocysts were measured. For electron microscopy, small cubes of formalin-fixed tissue were transferred to 2% glutaralde-

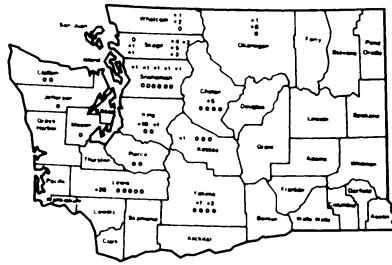


FIGURE 1. Areas in Washington where mountain goats were collected. Numbers indicate number of sarcocysts per cm^2 of tongue.

hyde in 0.1 M cacodylate buffer, and then to buffer alone. Postfixation in 1% osmium tetroxide was followed by embedding in Epon 812 (Polysciences, 400 Valley Road, Warrington, Pennsylvania 18976, USA). Thin sections were mounted on grids, contrasted with 0.25% lead citrate and 2.0% uranyl acetate suspended in absolute methanol, and viewed with a transmission electron microscope (Hitachi 600, Hitachi, Santa Clara, California 95044, USA).

When sarcocysts were observed in tissue, the corresponding tongue that was stored at 4 C was sliced in 2 to 4 cm^2 sections and fed to one or more animals or birds that were maintained in the animal holding facilities at Washington State University. At least 25 g of tongue were fed to each host. Infected tongues were fed to four coyotes (*Canis latrans*), eight domestic dogs, four domestic cats, three bears (*Ursus americanus*), two raccoons (*Procyon lotor*), two martens (*Martes americana*), two fishers (*Martes pennanti*), three skunks (*Mephitis mephitis*), five mink (*Mustela vison*), five ferrets (*Mustela putorius*), one pig-tail macaque (*Macaca nemestrina*), two red-tailed hawks (*Buteo jamaicensis*) and one great horned owl (*Bubo virginianus*). All hosts except the raptors had been in captivity since they were born and had not eaten meat for at least 60 days before ingesting the mountain goat tongues. Oocysts or sporocysts were not observed in feces of any animal or bird prior to feeding the meat.

Feces were collected from the hosts on

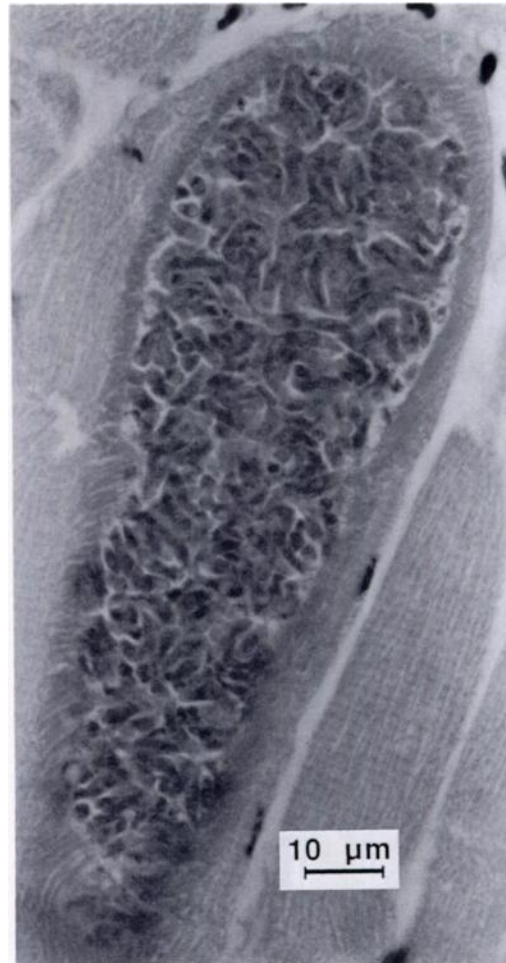

FIGURE 2. *Sarcocystis* sp. in section of tongue muscle of a mountain goat. H&E.

the day of feeding, and 10 and 20 days after feeding the tongue tissue. A modified fecal flotation technique (sugar solution, specific gravity = 1.27) was used to isolate oocysts or sporocysts in feces (Foreyt, 1986a). Slides were examined at $400\times$.

Sarcocystis sp. was detected in 24 of 56 (43%) of the tongues examined. Geographic localities for positive and negative samples in Washington are illustrated in Figure 1. Positive samples were present in 10 of 13 counties represented. Mean intensity of sarcocysts/ cm^2 of tissue was 4.25 (range = 1 to 28). Mean size of sarcocysts ($n = 154$) in tongue muscle was $71.3 \times 37.8 \mu\text{m}$ (range, 20 to 248 \times 10 to 120 μm). Mi-

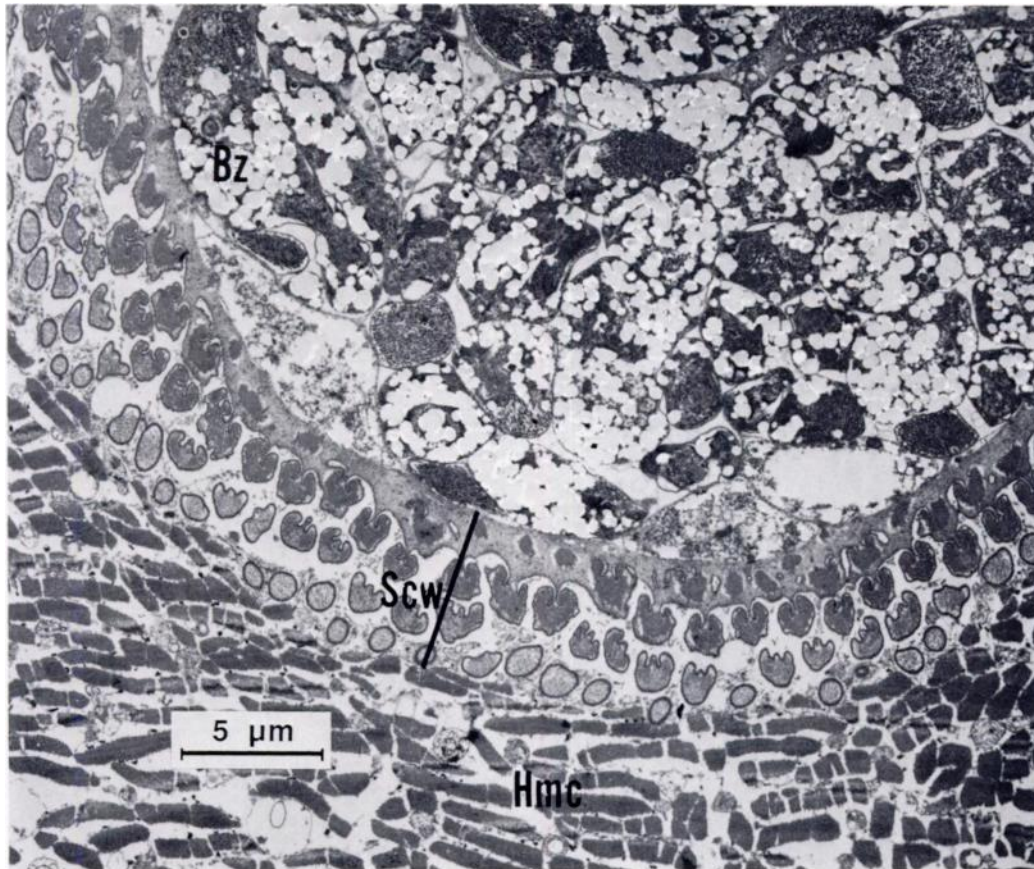


FIGURE 3. Transmission electron micrograph of *Sarcocystis* sp. sarcocyst in the tongue muscle of a mountain goat. Hmc, host muscle cell; Scw, sarcocyst cell wall; Bz, bradyzoite.

croscopically sarcocysts resembled sarcocysts from other ruminant species (Fig. 2); however, at higher magnification (2,000 to 10,000 \times), unusual sessile polyp branching of the cyst wall was observed (Figs. 3, 4). The branching cell wall was approximately 5 μ m in diameter.

Oocysts or sporocysts of *Sarcocystis* sp. were not detected in feces of any mammal or bird fed infected tongues from mountain goats. The definitive host of *Sarcocystis* sp. in mountain goats was not determined.

Prevalence of *Sarcocystis* sp. (43%) in mountain goats in Washington was of sufficient magnitude and distribution that the definitive host must be present in western Washington. Likely definitive hosts are canine and feline species, particularly dogs,

coyotes and cats, or other carnivores such as black bears, raccoons and skunks. Although pieces of tongue from at least two infected goats were fed to each host, it is possible, but unlikely, that some sarcocysts were not viable. Only a few of the tongues received were odorous, with most of the tongues appearing fresh. In 1986, 125 mountain goats in Washington were killed by hunters, and 56 tongues (43%) were submitted.

The *Sarcocystis* sp. detected in the mountain goats that we examined is an unusual species when compared to existing descriptions of known species (Dubey et al., 1988). Most notable is the cyst wall which appears to be distinctly branched with individual sessile polyp-shaped projections. This type of cell wall has been

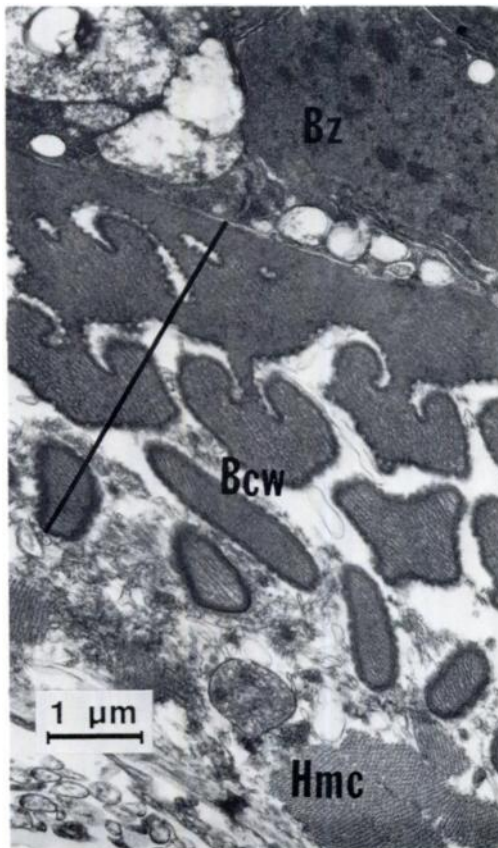


FIGURE 4. Transmission electron micrograph of the wall of *Sarcocystis* sp. in the tongue muscle of a mountain goat. Bcw, branching cyst wall; Bz, bradyzoite; Hmc, host muscle cell.

classified as Type 24 (Dubey et al., 1988), and has not been observed in other known *Sarcocystis* sp. (Mehlhorn et al., 1976; Dubey et al., 1988).

Sarcocystosis in cattle caused by *Sarcocystis bovis* can be a lethal disease. Schizogony in muscles causes rupture of blood vessels, anemia, incoordination and death (Briggs and Foreyt, 1985; Foreyt, 1986b). The impact of *Sarcocystis* sp. infection in mountain goats is unknown; however, there is the potential of *Sarcocystis* sp. as a mortality factor. The state of Washington has approximately 6,000 to 8,000 mountain goats, but mortality factors are essentially unknown (Johnson, 1983; Foreyt and Leathers, 1985; Dunbar et al., 1986). Further studies will clarify the importance and

epizootiology of *Sarcocystis* sp. in mountain goats.

LITERATURE CITED

- BRIGGS, M., AND W. J. FOREYT. 1985. Sarcocystosis in cattle. The Compendium on Continuing Education for the Practicing Veterinarian 7: 396-400.
- DUBEY, J. P. 1976. A review of *Sarcocystis* of domestic animals and of other coccidia of cats and dogs. Journal of the American Veterinary Medical Association 169: 1061-1078.
- , C. A. SPEER, AND R. FAYER. 1988. Sarcocystosis of animals and man. CRC Press, Inc., Boca Raton, Florida, 215 pp.
- DUNBAR, M. R., W. J. FOREYT, AND J. F. EVERMANN. 1986. Serologic evidence of respiratory syncytial virus infection in free-ranging mountain goats (*Oreamnos americanus*). Journal of Wildlife Diseases 22: 415-416.
- FOREYT, W. J. 1986a. Recovery of nematode eggs and larvae in deer: Evaluation of fecal preservation methods. Journal of the American Veterinary Medical Association 189: 1065-1067.
- . 1986b. Evaluation of decoquinat, lasalocid, and monensin against experimentally induced sarcocystosis in calves. American Journal of Veterinary Research 47: 1674-1676.
- , AND C. W. LEATHERS. 1985. Starvation secondary to an oral fibroma in a wild mountain goat (*Oreamnos americanus*). Journal of Wildlife Diseases 21: 184-185.
- FRENKEL, J. K., A. O. HEYDORN, H. MEHLHORN, AND M. ROMMEL. 1979. Sarcocystinae: Nomina dubia and available names. Zeitschrift für Parasitenkunde 58: 115-139.
- JOHNSON, R. L. 1983. Mountain goats and mountain sheep of Washington. Washington Department of Game Biological Bulletin No. 18, Olympia, Washington, 196 pp.
- LEVINE, N. D. 1986. The taxonomy of *Sarcocystis* (Protozoa, Apicomplexa) species. The Journal of Parasitology 72: 372-382.
- , AND V. IVENS. 1986. The coccidian parasites (Protozoa, Apicomplexa) of Artiodactyla. Illinois Biological Monograph No. 55, University of Illinois Press, Urbana, Illinois, 248 pp.
- , AND W. TADROS. 1980. Named species and hosts of *Sarcocystis* (Protozoa, Apicomplexa: Sarcocystidae). Systematic Parasitology 2: 41-59.
- MAHRT, J. L., AND D. D. COLWELL. 1980. Sarcocystis in wild ungulates in Alberta. Journal of Wildlife Diseases 16: 571-576.
- MEHLHORN, H., J. HARTLEY, AND A. O. HEYDORN. 1976. A comparative ultrastructural study of the cyst wall of 13 *Sarcocystis* species. Protistologica 12: 451-467.

Received for publication 10 February 1989.