

Nematode Related Spinal Myelomeningitis and Posterior Ataxia in Muskoxen (*Ovibos moschatus*)

Authors: Holt, Gunnar, Berg, Carl, and Haugen, Anders

Source: Journal of Wildlife Diseases, 26(4) : 528-531

Published By: Wildlife Disease Association

URL: <https://doi.org/10.7589/0090-3558-26.4.528>

The BioOne Digital Library (<https://bioone.org/>) provides worldwide distribution for more than 580 journals and eBooks from BioOne's community of over 150 nonprofit societies, research institutions, and university presses in the biological, ecological, and environmental sciences. The BioOne Digital Library encompasses the flagship aggregation BioOne Complete (<https://bioone.org/subscribe>), the BioOne Complete Archive (<https://bioone.org/archive>), and the BioOne eBooks program offerings ESA eBook Collection (<https://bioone.org/esa-ebooks>) and CSIRO Publishing BioSelect Collection (<https://bioone.org/csiro-ebooks>).

Your use of this PDF, the BioOne Digital Library, and all posted and associated content indicates your acceptance of BioOne's Terms of Use, available at www.bioone.org/terms-of-use.

Usage of BioOne Digital Library content is strictly limited to personal, educational, and non-commercial use. Commercial inquiries or rights and permissions requests should be directed to the individual publisher as copyright holder.

BioOne is an innovative nonprofit that sees sustainable scholarly publishing as an inherently collaborative enterprise connecting authors, nonprofit publishers, academic institutions, research libraries, and research funders in the common goal of maximizing access to critical research.

SHORT COMMUNICATIONS

Journal of Wildlife Diseases, 26(4), 1990, pp. 528-531
© Wildlife Disease Association 1990

Nematode Related Spinal Myelomeningitis and Posterior Ataxia in Muskoxen (*Ovibos moschatus*)

Gunnar Holt,¹ Carl Berg,¹ and Anders Haugen,² ¹ National Veterinary Institute, P.O. Box 8156 Dep, N-0033 Oslo 1, Norway; ² Engerdal, 2443 Drevsjø, Norway

ABSTRACT: In the fall of 1988 all five animals in a herd of muskoxen (*Ovibos moschatus*) developed clinical signs of posterior ataxia. Post-mortem investigation revealed inflammatory lesions of the caudal part of the spinal cord, mainly as leptomeningitis. Nematodes were seen in close association with the lesions. Although not identified, the parasites were probably an *Elaphostrongylus* sp.

Key words: Muskox, *Ovibos moschatus*, spinal cord, central nervous system, myelomeningitis, ataxia, nematodes, *Elaphostrongylus* sp., case report.

In the first half of the twentieth century several unsuccessful attempts were made to introduce muskoxen (*Ovibos moschatus*) into Sweden and Norway (Lønø, 1960). In the years 1947 to 1953 three yearlings and 24 calves of muskoxen were captured on East Greenland and transferred to Norway. Some animals died before and soon after they were released in the mountain area of Dovrefjell (62°23'N, 9°30'E) and there were probably only 10 survivors left by late autumn 1953 (Lønø, 1960). Since then a population of muskoxen has remained within an area of 8 × 13 km at an altitude of 700 to 1,600 m in Dovrefjell. In 1982 the muskoxen numbered 33 (Alendal and Helle, 1983); in 1988 there were 54 animals.

In 1971 a group of five muskoxen left their range in Dovrefjell and wandered about 140 km east to Härjedalen, Sweden (62°27'N) where they increased to a number of 16 animals by 1978 (Lundh, 1979). During the following years a population of muskoxen was established in the border area between Norway and Sweden. These

animals, together with those in Dovrefjell, are the only free-living muskoxen in Scandinavia.

In October 1988 the National Veterinary Institute (Oslo, Norway) received a report from the local wildlife authorities in Engerdal municipality near the Norwegian-Swedish border (approximately 61°50'N, 12°00'E) that all animals in a small herd of five muskoxen were showing marked signs of posterior ataxia. The herd consisted of one bull, two cows, one yearling and one calf. To prevent further suffering and enable postmortem examination in order to establish the cause of ataxia, the national wildlife authorities decided to kill these animals. Initially the affected calf was shot and submitted to the institute for postmortem examination. Later the two cows and the bull also were shot. Necropsy of these was conducted by the local veterinarian. The vertebral columns and organ samples were submitted to the institute. Remains of the yearling, possibly killed by predators, were found and the vertebral column was submitted for examination.

All animals were in a good nutritional state. There was minor bruising in the sacral and pelvic region of the calf, the bull and one cow. The calf had some blood in the synovial fluid of the right hip joint. Similar lesions with minor haemorrhages in the joint capsule and the ligamentum teres were seen in both hips of one cow. Small yellow-gray, gelatinous foci were observed in the leptomeninges of the caudal lumbar and sacral part of the spinal

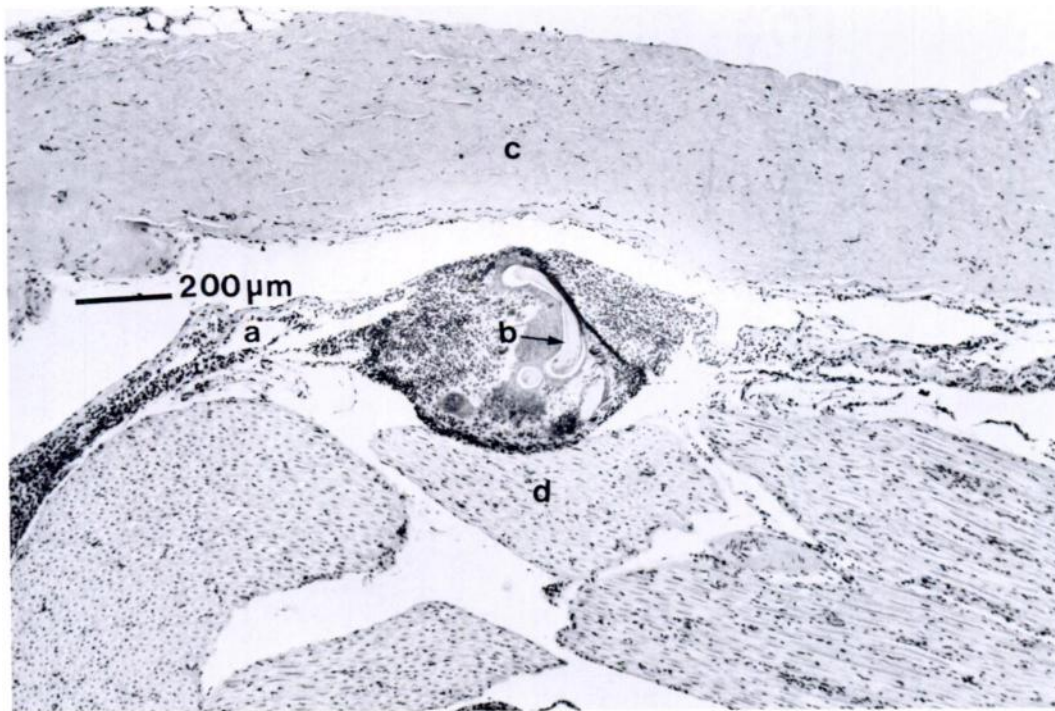


FIGURE 1. Inflamed leptomeninx (a) of the spinal cord of a muskox containing section of nematode (b) between the dura mater (c) and the nerve parenchyma (d). H&E.

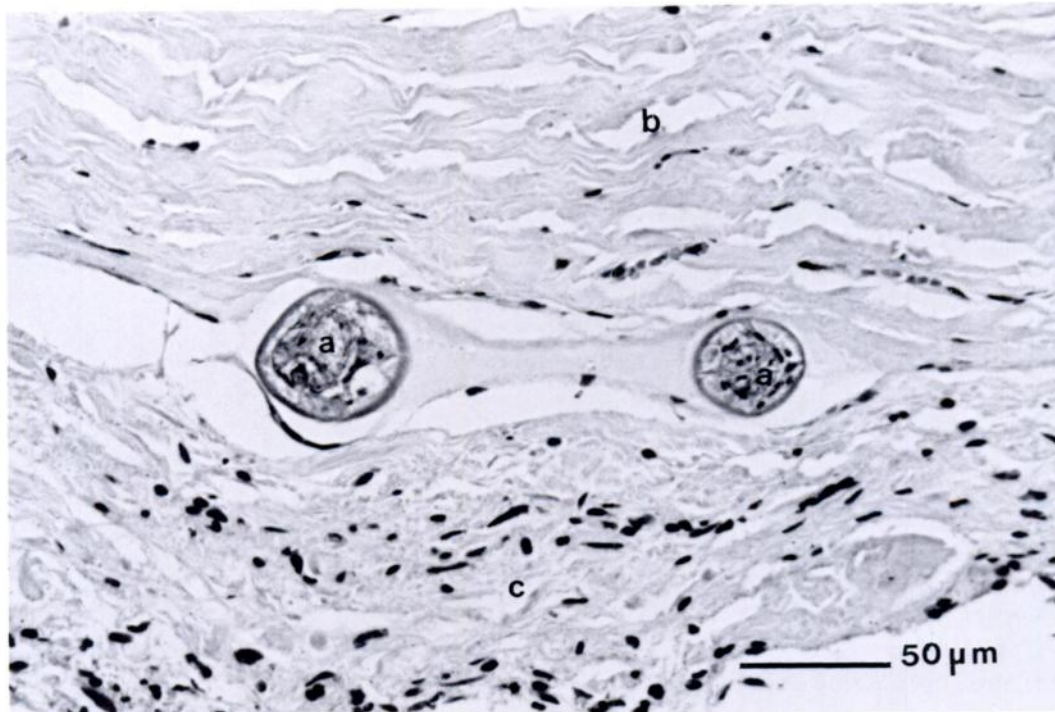


FIGURE 2. Section of nematode (a) between dura mater (b) and leptomeninx (c) in the spinal cord of a muskox. H&E.

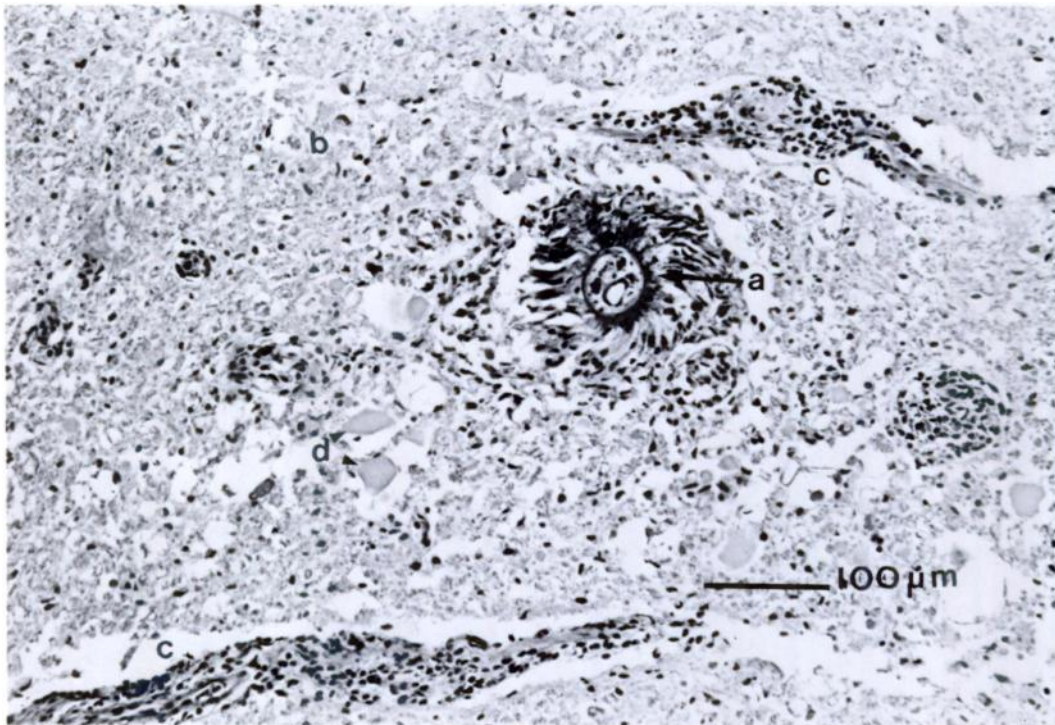


FIGURE 3. Section of nematode (a) in spinal cord parenchyma (b) of a muskox. Adjacent perivascular cuffing of mononuclear cells (c) and swollen segments of axons (d). H&E.

cord in all animals. Incomplete specimens of nematodes were extracted from these lesions. The nematodes appeared not yet to have developed reproductive organs, only cuticle, oesophagus and digestive tract could be differentiated. They resembled nematodes of the genus *Elaphostrongylus* but could not be identified with certainty. No intermuscular nematodes were detected at necropsy.

Histological examination revealed a nonpurulent leptomeningitis in the caudal lumbar and sacral part of the spinal cord. The inflammatory infiltrate consisted primarily of mononuclear cells, mostly lymphocytes and macrophages. A number of macrophages contained hematogenous pigment, and free hemosiderin was observed intercellularly. A few foci also contained eosinophilic granulocytes. In some areas the lesions were granulomatous and contained polynuclear giant cells. Sections of nematodes were seen in or near the inflamed tissue (Figs. 1, 2). A characteristic

lesion involving compact aggregations of necrotic, somewhat granular debris was often seen. This material was primarily eosinophilic and frequently had a central opening containing structures that were considered to be the remains of nematodes.

In spinal cord parenchyma, nerve roots, epidural tissue and in the dura mater itself similar lesions were observed but to a lesser extent than in the leptomeninges. Adjacent to the parasitic lesions in the spinal cord parenchyma perivascular cuffing of mononuclear cells and swollen segments of axons were occasionally observed (Fig. 3).

Disseminated eggs and larvae of *Elaphostrongylus* sp. in lung parenchyma as described by Stuve (1986) in moose (*Alces alces*) were not found. An aggregation of lung nematodes was seen in lung sections and protostrongylid larvae were found in tracheal smears from one of the cows. Similar larvae have been described in muskoxen (Alendal and Helle, 1983).

The nematodes found in the vertebral

canal are considered to be the primary cause of the spinal cord lesions and of the ataxia in the muskoxen. *Elaphostrongylus* sp. cause similar lesions in reindeer (*Rangifer tarandus*) (Bakken and Sparboe, 1973) and in moose (*Alces alces*) (Stuve, 1986). The muskoxen in question share range with both reindeer and moose and it is therefore considered likely that they have become infected with *Elaphostrongylus* sp. from either moose or reindeer. The fact that only immature worms were found may indicate that the parasite is unable to complete its life cycle in the muskox or that the animals were shot before the nematodes had time to reach maturity.

Apparently, muskoxen are easily infected with parasites normally occurring in other ruminant species (Alendal and Helle, 1983). In this incident all five animals were affected and this indicates that muskoxen can be highly susceptible to infection with the suspected parasite. The actual area is one of the very few areas where muskoxen share range with cervids hosting *Elaphostrongylus* sp. This might be the reason why this phenomenon has

not been previously reported. Alternatively, ataxia in muskoxen due to this parasite might be transient. Muskoxen are rarely observed by man and the condition might therefore have been overlooked. However, in these cases the ataxia was caused by severe spinal cord lesions and it is therefore unlikely that the animals would have recovered completely.

LITERATURE CITED

- ALENDAL, E., AND O. HELLE. 1983. Helminth parasites of muskoxen, *Ovibos moschatus*, in Norway including Spitsbergen and in Sweden, with a synopsis of parasites reported from this host. Fauna Norvegica, Series A 4: 41-52.
- BAKKEN, G., AND O. SPARBOE. 1973. Elaphostrongylosis in reindeer. Nordisk Veterinærmedicin 25: 203-210.
- LUNDH, O. 1979. Myskoxarna i Härjedalen. Fauna Flora 74: 13-26.
- LØNØ, O. 1960. Transplantation of the muskox in Europe and North-America. Norsk Polarinstitut, Meddelelser Number 84: 3-25.
- STUVE, G. 1986. The prevalence of *Elaphostrongylus cervi* infection in moose (*Alces alces*) in southern Norway. Acta Veterinaria Scandinavica 27: 397-409.

Received for publication 9 January 1990.