

Coccidia, X-Cell Pseudotumors and Ichthyophonus sp. Infections in Walleye Pollock (*Theragra chalcogramma*) from Auke Bay, Alaska

Authors: Eaton, W. D., Kent, M. L., and Meyers, T. R.

Source: Journal of Wildlife Diseases, 27(1) : 140-143

Published By: Wildlife Disease Association

URL: <https://doi.org/10.7589/0090-3558-27.1.140>

The BioOne Digital Library (<https://bioone.org/>) provides worldwide distribution for more than 580 journals and eBooks from BioOne's community of over 150 nonprofit societies, research institutions, and university presses in the biological, ecological, and environmental sciences. The BioOne Digital Library encompasses the flagship aggregation BioOne Complete (<https://bioone.org/subscribe>), the BioOne Complete Archive (<https://bioone.org/archive>), and the BioOne eBooks program offerings ESA eBook Collection (<https://bioone.org/esa-ebooks>) and CSIRO Publishing BioSelect Collection (<https://bioone.org/csiro-ebooks>).

Your use of this PDF, the BioOne Digital Library, and all posted and associated content indicates your acceptance of BioOne's Terms of Use, available at www.bioone.org/terms-of-use.

Usage of BioOne Digital Library content is strictly limited to personal, educational, and non-commercial use. Commercial inquiries or rights and permissions requests should be directed to the individual publisher as copyright holder.

BioOne is an innovative nonprofit that sees sustainable scholarly publishing as an inherently collaborative enterprise connecting authors, nonprofit publishers, academic institutions, research libraries, and research funders in the common goal of maximizing access to critical research.

Coccidia, X-Cell Pseudotumors and *Ichthyophonus* sp. Infections in Walleye Pollock (*Theragra chalcogramma*) from Auke Bay, Alaska

W. D. Eaton,^{1,2} M. L. Kent,³ and T. R. Meyers,² ¹ Juneau Center for Fisheries and Ocean Sciences, University of Alaska Fairbanks, 11120 Glacier Highway, Juneau, Alaska 99801, USA; ² Alaska Department of Fish and Game F.R.E.D. Division, Juneau, Alaska 99802, USA; ³ Department of Fisheries and Oceans, Biological Science Branch, Pacific Biological Station Nanaimo, British Columbia, Canada V9R 5K6

ABSTRACT: One hundred twenty-five walleye pollock (*Theragra chalcogramma*) were collected from Auke Bay, Alaska (USA) in 1985 and examined for histologic evidence of disease-causing infectious agents in 1987. A *Goussia* sp.-like coccidium was found in the kidney tubules of 75% and an *Eimeria* sp.-like coccidium was found in the intestine of 18% of the fish examined. The kidney coccidium was associated with sloughing of the tubular epithelium, peritubular fibrosis and granuloma formation. The intestinal coccidium was associated with severe tissue displacement and inflammation. In addition, X-cell pseudotumors were observed in the pseudobranchs (4%), and the fungus *Ichthyophonus* sp. was observed in the kidney, intestine or brain of 2% of the pollock.

Key words: Pollock, fish coccidians, *Eimeria* sp., *Goussia* sp., X-cell pseudotumors, *Ichthyophonus* sp., survey.

The walleye pollock (*Theragra chalcogramma*) is one of the most abundant and heavily exploited of the ground fish in Alaska, with harvests in the Gulf of Alaska ranging from 115,000 to 5,500,000 metric tons/yr since 1974 (Bakkala and Weststad, 1983). However, the size of the harvest fluctuates yearly among the different age classes due to environmental pressures, many of which are undefined, and exploitation rates (Francis and Bailey, 1983). One such pressure may be the presence of different pathogens.

Pathogens of the walleye pollock have not been well characterized. Arthur (1984) described the parasite fauna of pollock grossly, but no histopathologic evidence of disease was reported. The current study was conducted to identify potential disease producing infectious agents in walleye pollock from Auke Bay, Alaska through histological examination of various tissues and organs.

One hundred twenty-five walleye pol-

lock were collected from Auke Bay, Alaska during April through August, 1985, using a 5.4 m otter trawl, and examined in 1988. After gross examination at the time of collection, the fish were preserved in 10% buffered formalin for later histologic examination. Wet mount examinations were conducted using formalin fixed tissues. Tissues were processed for histology using standard techniques and stained with hematoxylin and eosin (Humason, 1979).

The fungus *Ichthyophonus* sp. was observed in 2% (3/125) of the pollock. *Ichthyophonus* sp. resting spores were seen within granulomata of the kidney, intestine and brain while germinating spores with pseudopodia-like hyphae were observed within granulomata in the kidney (Fig. 1). To our knowledge, this study provides the first record of *Ichthyophonus* sp. in walleye pollock. Although *Ichthyophonus* sp. infections have caused extensive mortalities in numerous species of fish and have been considered a possible limiting factor to population growth in some marine fish (Sindermann, 1970), the fungus probably has no significant effect on the population of pollock in Auke Bay as both the incidence and intensity of infection are very low.

Pseudobranchial X-cell pseudotumors were found in 4% (5/125) of the fish examined. The pseudotumors were generally bilateral and were composed of large aggregates of X-cells (8 to 17 μ m diameter) surrounded by connective tissue. The X-cells had infiltrated the pseudobranch and replaced most of the normal tissue (Fig. 1). These diffuse X-cell pseudotumors appear to be more similar to those found in the pseudobranchs and gills of

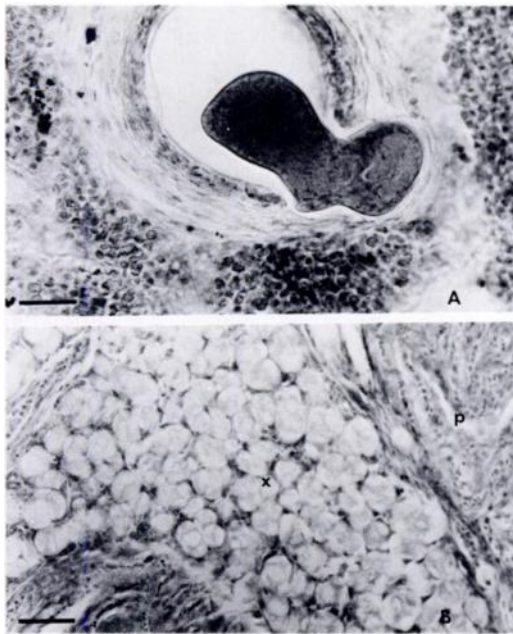


FIGURE 1. A. Germinating resting spore of the fungus *Ichthyophonus* sp. in the kidney of walleye pollock (bar = 20 μ m). B. Pseudobranchial X-cell pseudotumors observed within walleye pollock (x, X-cells; p, normal pseudobranchial tissue; bar = 30 μ m).

eelpouts (Desser and Khan, 1982) and dabs (Diamant and McVicar, 1987) than to those previously reported in pollock and cod (Alpers et al., 1977; McCain et al., 1979; Morrison et al., 1982) in that the X-cells invaded the pseudobranch tissue rather than occurring next to or on top of the pseudobranchs separated from normal cells by a connective tissue capsule. Although Diamant and McVicar (1987) concluded that some secondary respiratory capabilities may be lost due to severe X-cell infections, similar to those observed in the current study, the low prevalence of the pseudotumors in the Auke Bay pollock suggests that the X-cells do not have a significant effect on the overall population.

Two different coccidian parasites were observed; one in the kidney tubules and the other within the intestine. The kidney parasite was present in 75% (94/125) of the fish. It appeared to belong to the genus *Goussia* as examination of 20 formalin fixed

oocysts (Fig. 2) showed that they were $12.1 \pm 0.5 \mu$ m long and $11.3 \pm 0.3 \mu$ m wide, contained four ellipsoidal sporocysts that were $10.2 \pm 0.6 \mu$ m long and $5.3 \pm 0.2 \mu$ m wide, each of which apparently lacked a polar Steida body and contained two elongate sporozoites which were $12.3 \pm 0.7 \mu$ m long and $2.0 \pm 0.3 \mu$ m wide. Macrogamonts within the kidney tubule epithelium and between the epithelium and basal lamina were the earliest form of the kidney coccidium observed and were associated with sloughing of the epithelial layer of the kidney tubules. Large numbers of macrogamonts, oocysts with developing sporocysts, and free sporocysts and sporozoites within the kidney were associated with peritubular fibrosis and granulomata formation (Fig. 2). No microgamonts or asexual stages of the parasite (meronts) were observed.

The second coccidian was found in the mucosa and submucosa of the intestine of 18% (23/125) of the pollock. It appeared to be a member of the genus *Eimeria* as examination of 20 formalin fixed oocysts (Fig. 2) showed them to be $18 \pm 0.8 \mu$ m long and $14 \pm 0.9 \mu$ m wide and contain four ellipsoidal sporocysts which were $11 \pm 0.6 \mu$ m long and $5 \pm 0.4 \mu$ m wide, each having a structure suggestive of a Steida body and two sporozoites which were $8.5 \pm 0.6 \mu$ m long and $2.1 \pm 0.3 \mu$ m wide. Macrogamonts and developing oocysts with sporocysts were observed in the intestinal mucosa and submucosa of infected fish. The intensity of infection varied from a few macrogamonts causing minor tissue displacement to large numbers of macrogamonts and oocysts causing extensive tissue necrosis, inflammation, and granulomata formation (Fig. 2).

These two coccidians may have the potential to cause disease when present at the intensities seen in the Auke Bay walleye pollock. Both infections probably resulted in reduced function of the affected organ and could be a contributing factor in increased mortalities. Further investigations are necessary to determine the taxonomic

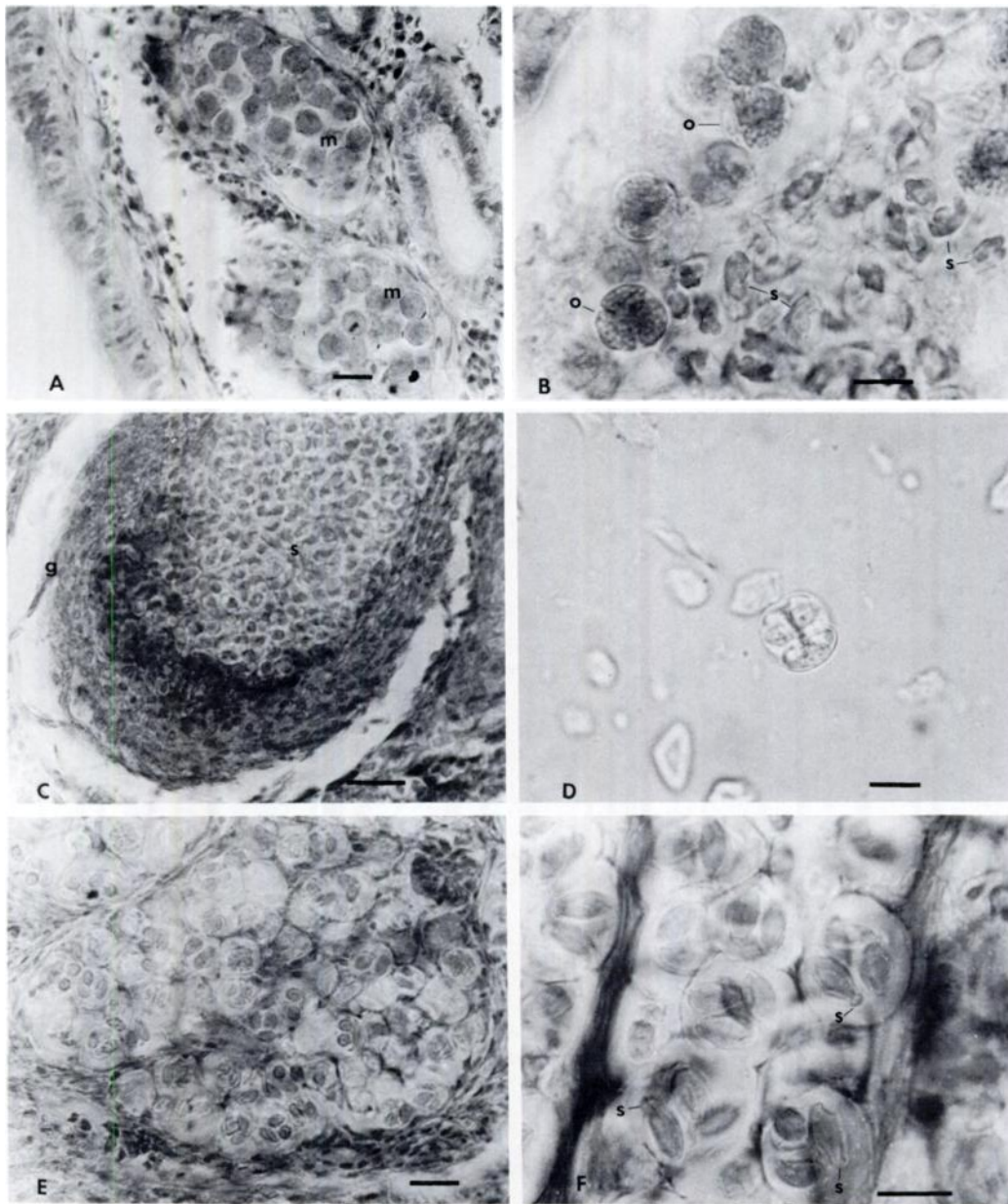


FIGURE 2. A. Macrogamonts (m) of the *Goussia* sp.-like coccidium in walleye pollock kidney tubules (bar = 20 μ m). B. Developing oocysts (o) and sporocysts (s) with sporozoites of the *Goussia* sp.-like coccidium within the lumen of a fibrotic kidney tubule of pollock (bar = 10 μ m). C. Kidney granuloma (g) containing sporocysts (s) of the *Goussia* sp.-like parasite (bar = 30 μ m). D. Oocysts of the *Goussia* sp.-like coccidium containing four sporocysts each with two sporozoites (from formalin preserved material) in walleye pollock kidney (bar = 10 μ m). E. *Eimeria* sp.-like coccidium in the mucosa and submucosa of the intestine of walleye pollock (bar = 20 μ m). F. Oocysts of the *Eimeria* sp.-like coccidium containing four sporocysts, each of which has a polar thickening resembling Steida bodies (s; bar = 10 μ m).

placement of these parasites and if they are important in pollock survival and, thus, may affect population size.

This work was supported by Alaska Sea Grant Project Number NA-82AA-D-SG041 and conducted at the Juneau Center for Fisheries and Ocean Sciences, which is part of the University of Alaska Fairbanks School of Fisheries and Ocean Sciences. Histological preparations were done by Sally Short, Alaska Department of Fish and Game.

LITERATURE CITED

- ALPERS, C. E., B. B. MCCAIN, M. S. MEYERS, S. R. WELLINGS, M. POORE, J. BAGSHAW, AND C. J. DAWE. 1977. Pathological anatomy of pseudobranch tumors in Pacific cod, *Gadus macrocephalus*. *Journal of the National Cancer Institute* 59: 377-398.
- ARTHUR, J. R. 1984. A survey of the parasites of walleye pollock (*Theragra chalcogramma*) from the northeastern Pacific Ocean off Canada and a geographical analysis of the parasite fauna of this fish throughout its range. *Canadian Journal of Zoology* 62: 675-684.
- BAKKALA, R. G., AND V. WESPESTAD. 1983. Pollock. In *Condition of groundfish resources of the eastern Bering Sea and Aleutian Islands region in 1982*, R. Bakkala and L. Low (eds.). National Marine Fisheries Service, Seattle, Washington, TM F/NWC-42.
- DESSER, S. S., AND R. A. KHAN. 1982. Light and electron microscopic observations on pathological changes in the gills of the marine fish *Lycodes lavalaei* Vladikov and Tremblay associated with the proliferation of an unidentified cell. *Journal of Fish Diseases* 5: 351-364.
- DIAMANT, A., AND A. H. MCVICAR. 1987. The effect of internal and external X-cell lesions on common dab, *Limanda limanda* L. *Aquaculture* 67(1987): 127-133.
- FRANCIS, R. C., AND K. M. BAILEY. 1983. Factors affecting recruitment of selected gadoids in the northeast Pacific and east Bering Sea. In *From year to year*, W. A. Wooster (ed.). Sea Grant, University of Washington, Seattle, Washington, pp. 35-57.
- HUMASON, G. L. 1979. Animal tissue techniques. W. H. Freeman and Company, San Francisco, California, 661 pp.
- MCCAIN, B. B., W. D. GRONLUND, M. S. MEYERS, AND S. R. WELLINGS. 1979. Tumors and microbial diseases of marine fishes in Alaskan waters. *Journal of Fish Diseases* 2: 111-130.
- MORRISON, C. M., G. SHUM, R. G. APPY, P. ODENSE, AND C. ANNAND. 1982. Histology and prevalence of X-cell lesions in Atlantic cod (*Gadus morhua*). *Canadian Journal of Fisheries and Aquatic Sciences* 39: 1519-1530.
- SINDERMAN, C. J. 1970. Principal diseases of marine fish and shellfish. Academic Press, New York, New York, 369 pp.

Received for publication 18 January 1990.