



New Locality Record for *Heterobilharzia americana*

Authors: McKown, Richard D., Veatch, Johna K., and Fox, Lloyd B.

Source: Journal of Wildlife Diseases, 27(1) : 156-160

Published By: Wildlife Disease Association

URL: <https://doi.org/10.7589/0090-3558-27.1.156>

BioOne Complete (complete.BioOne.org) is a full-text database of 200 subscribed and open-access titles in the biological, ecological, and environmental sciences published by nonprofit societies, associations, museums, institutions, and presses.

Your use of this PDF, the BioOne Complete website, and all posted and associated content indicates your acceptance of BioOne's Terms of Use, available at www.bioone.org/terms-of-use.

Usage of BioOne Complete content is strictly limited to personal, educational, and non - commercial use. Commercial inquiries or rights and permissions requests should be directed to the individual publisher as copyright holder.

BioOne sees sustainable scholarly publishing as an inherently collaborative enterprise connecting authors, nonprofit publishers, academic institutions, research libraries, and research funders in the common goal of maximizing access to critical research.

New Locality Record for *Heterobilharzia americana*

Richard D. McKown,¹ Johna K. Veatch,² and Lloyd B. Fox,³ ¹ Department of Laboratory Medicine, College of Veterinary Medicine, Kansas State University, Manhattan, Kansas 66506, USA; ² Department of Veterinary Diagnosis, College of Veterinary Medicine, Kansas State University, Manhattan, Kansas 66506, USA; ³ Kansas Department of Wildlife and Parks, Emporia Research Office, Emporia, Kansas 66801, USA

ABSTRACT: Thirty raccoons (*Procyon lotor*) from three counties in east-central and southeast Kansas (USA) were examined for schistosomiasis. Eleven (37%) of the raccoons had adult schistosomes identified as *Heterobilharzia americana* present in the mesenteric vessels, histopathological lesions compatible with schistosomiasis, or both. This represents the first report of *H. americana* in Kansas and in the central United States.

Key words: *Heterobilharzia americana*, Schistosomatidae, raccoon, *Procyon lotor*, histopathology, survey.

Two species of schistosomes, *Schistosomium douthitti* and *Heterobilharzia americana* infect mammals in the United States. *Heterobilharzia americana* was described from a bobcat in Florida (Price, 1929), and has since been reported from various species and localities throughout the southern Atlantic and Gulf Coast states in the United States. Other records include the nine-banded armadillo (*Dasypus novemcinctus*) from Louisiana (Krotoski et al., 1984); a captive born Brazilian tapir (*Tapirus terrestris*) originally from Mississippi (Yamini and Schillhorn van Veen, 1988); beaver (*Castor canadensis*) from Texas (Fedynich et al., 1986); bobcat from Louisiana (Shoop and Corkum, 1982); coyote (*Canis latrans*) from Texas and Louisiana (Custer and Pence, 1981); domestic dogs from Louisiana (Malek et al., 1961; Lee, 1962a) and Texas (Sponenberg, 1976; Troy et al., 1987); mountain lion (*Felis concolor coryi*) from Florida (Forrester et al., 1985); mink (*Mustella vison*) from Louisiana (Shoop and Corkum, 1982); nutria (*Myocastor coypus*) from Louisiana (Malek et al., 1961; Lee, 1962a); opossum (*Didelphis marsupialis*) from Louisiana (Kaplan, 1964); raccoon (*Procyon lotor*) from Florida (Bartsch and Ward, 1976; Schaffer et al., 1981), Georgia (Byrd et al.,

1967), Louisiana (Malek et al., 1961; Lee, 1962a; Shoop and Corkum, 1982), North Carolina (Miller and Harkema, 1960; Schaffer et al., 1981) and Texas (Price, 1943; Goff and Ronald, 1981; Schaffer et al., 1981); red wolves (*Canis rufus*) from Texas and Louisiana (Custer and Pence, 1981); red wolf × coyote hybrids (*Canis rufus* × *Canis latrans*) from Texas and Louisiana (Custer and Pence, 1981); swamp rabbits (*Sylvilagus aquaticus*) from Louisiana (Malek et al., 1961) and white-tailed deer (*Odocoileus virginianus*) from South Carolina (Byrd et al., 1967). However, this parasite has not previously been reported from central North America.

Raccoons used in this survey were obtained from two sources; a trapper, and from the Kansas Department of Wildlife and Parks (Emporia Research Office, Emporia, Kansas 66801, USA). Diseased or dead raccoons collected as part of a separate study conducted by the Department of Wildlife and Parks to determine the effects of hound training seasons on raccoon populations were sent to the Department of Veterinary Diagnosis at Kansas State University (College of Veterinary Medicine, Veterinary Clinical Science Building, Manhattan, Kansas 66506, USA). Thirty raccoons from three counties, one from Greenwood County (37°42'N, 96°09'W), one from Crawford County (37°30'N, 94°50'W), and 28 from Lyon County (all from a 4.5 mile section of the Neosho River between 38°24'N, 96°09'W and 38°22'N, 96°06'W) were received between April 1988 and May 1990. All raccoons were either presented dead or were euthanized by carbon dioxide asphyxiation in a CO₂ chamber. Eleven of thirty (37%) raccoons had adult schistosomes or

histopathological lesions compatible with heterobilharziasis (Thrasher, 1964; Bartsch and Ward, 1976; Krotoski et al., 1984; Slaughter et al., 1988).

Routine necropsies were performed and representative tissue samples were taken from each animal. All tissues, which included brain, various lymph nodes, tongue, esophagus, lung, heart, diaphragm, liver, spleen, pancreas, stomach, small and large intestine, kidney and urinary bladder, were fixed in 10% neutral buffered formalin. The small and large intestines and mesentery were cleaned and the mesenteric vessels were examined with the aid of a high intensity light shone through the vessel. Any adult *H. americana* were easily seen within the vessels and were flushed into a petri dish with physiological saline, relaxed and later fixed in AFA. The number of *H. americana* present in each of the raccoons ranged from three to 32. In one case, no adult flukes were found in the vessels but viable eggs containing miracidia were present in the liver. A Semichon's aceto-carmin stained slide of a male and female pair *in copula* has been deposited in the U.S. National Parasite Collection (Beltsville, Maryland 20705, USA; Accession number 80972).

For histopathological examination, the formalin-fixed tissues were trimmed, dehydrated, embedded in paraffin, and stained with hematoxylin and eosin according to routine histological techniques. The tissues of infected animals had typical lesions of heterobilharziasis (Thrasher, 1964; Bartsch and Ward, 1976; Krotoski et al., 1984; Slaughter et al., 1988). In one raccoon from Lyon County the kidney, heart, spleen, cerebrum, and cerebellum appeared normal. Sections of the mesenteric lymph node had medullary edema with increased eosinophils. Clusters of schistosome eggs were found scattered randomly throughout the lymph node and were surrounded by eosinophils, lymphocytes, and occasional fibrous tissue (Fig. 1). The mesentery had numerous eggs within vessels which were surrounded by

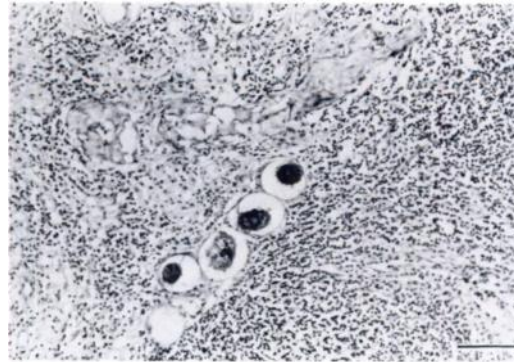


FIGURE 1. Eggs of *Heterobilharzia americana* within mesenteric lymph node of a raccoon. H&E. Bar = 100 μ m.

an eosinophilic granulomatous response (Fig. 2). Eosinophils infiltrated the tunica media of arterioles within the section. The liver had increased periportal fibrosis and eggs were found in the veins of the portal triads (Fig. 3). Eosinophils, lymphocytes, and occasional macrophages and plasma cells surrounded the eggs. Sections of small intestine had a few eggs in the mucosa and in submucosal vessels, but were without the surrounding inflammatory reaction. The pancreas had a moderate eosinophilic infiltrate around two vessels in the interlobular connective tissue. One egg was found within the parenchyma of the pancreas and lacked an inflammatory response. The gastric mucosa was within normal limits, but the submucosa had a marked eosinophilic inflammatory response. Eggs were not present within the section examined. However, lung sections had two foci of eggs surrounded by macrophages within alveolar septa (Fig. 4).

Of the 11 raccoons positive for *H. americana*, fecal samples from five were examined by a fine mesh screening technique ("Fluke-Finder"; Visual Difference, 5051C Old Pullman Road, Moscow, Idaho 83843, USA); all were passing viable eggs in the feces. All adult schistosomes were found in various locations throughout the mesenteric vessels. No single-sex infections were detected; however, in one animal there were nine males and one *in copula*

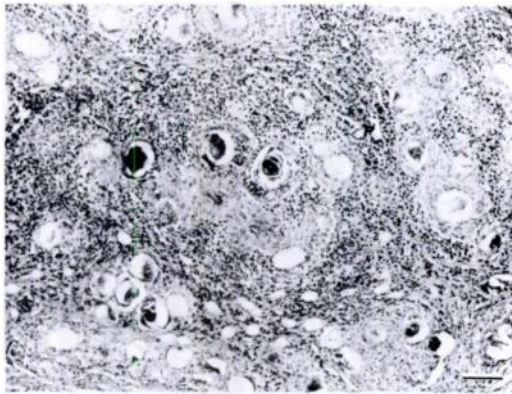


FIGURE 2. Granulomatous reaction surrounding *Heterobilharzia americana* eggs in the mesentery of a raccoon. H&E. Bar = 100 μ m.

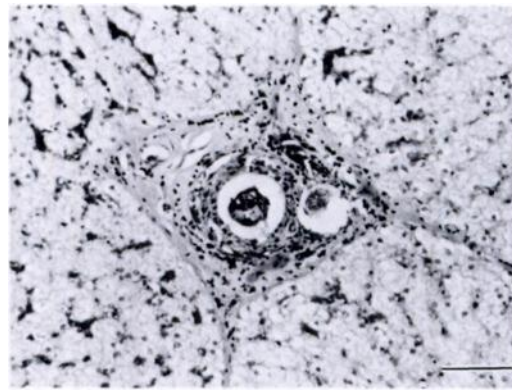


FIGURE 3. Eggs of *Heterobilharzia americana* present in periportal triad of the liver with surrounding inflammatory response and fibrosis of a raccoon. H&E. Bar = 100 μ m.

male/female pair. In another, multiple pairings occurred, in which there was one male pairing with more than one female. The frequency with which this occurs is unknown since there is only one other reference to this phenomenon (Kaplan, 1964).

It once was common practice for private hunting clubs to translocate raccoons to supplement local populations. In most cases the raccoons were simply trapped from one area and shipped to another site and released. Along with the newly introduced animals came the various diseases and parasites of their place of origin (Schaffer et al., 1981). Between 1934 and 1953, over 2,000 raccoons were introduced from other states into Kansas, with the majority of these coming from Texas (884) and Florida (476) (Cockrum, 1952; Stains, 1956), both of which are endemic for *H. americana*. Since 1983 the importation of raccoons into Kansas has been controlled by the Livestock Commissioner of the Kansas Animal Health Department and importation is prohibited except by special permit obtained prior to the entry of the animals into the state. With the passage of this law the shipment of raccoons into Kansas has dropped, but it is not known whether it has stopped completely.

The importation of infected raccoons into Kansas is the most probable explanation for the presence of *H. americana*

in the state. If its occurrence was due to the natural northern spread of the disease into suitable areas one would expect there to be reports of its occurrence in states to the east and south of Kansas, primarily Arkansas and Oklahoma, but we could find no such reports.

Assuming the probable introduction of the parasite into the state via translocated raccoons, its continued presence requires the existence of a suitable snail intermediate host. Two lymnaeid snails, *Fossaria cubensis* and *Pseudosuccinea columella*, are intermediate hosts for *H. americana* (Lee, 1962a, b; Malek, 1967, 1970; Malek and Armstrong, 1967; Goff and Ronald, 1981; Malek et al., 1987). Malek (1967)

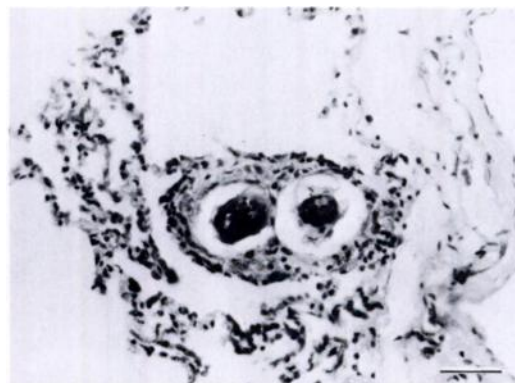


FIGURE 4. Alveolar septa in a raccoon with *Heterobilharzia americana* eggs. H&E. Bar = 100 μ m.

showed that the range of *H. americana* should not be limited by the range of its snail intermediate hosts because the snail's range far exceeds the known range of the parasite. The range of *P. columella* has been reported to include eastern Kansas (Burch, 1982), while the report of *F. cubensis* nearest to Kansas is of a single specimen from Oklahoma (Greger, 1915) and this record is suspect. The most probable intermediate host for *H. americana* in Kansas is therefore *P. columella*. Further field and laboratory investigations are needed to see if other lymnaeids that are known to occur in the state such as *Fossaria modicella* or *Fossaria bulimoides* (Leonard, 1959) may be susceptible to infection.

The presence of *H. americana* in the central United States has implications in both human and animal health. The cercarial stage of this parasite has been reported to cause a severe dermatitis in humans (Burks and Jung, 1960; Malek and Armstrong, 1967), non-human primates (Lee, 1962b), dogs (Thrasher, 1964; Lee, 1962b), cats (Lee, 1962b) and several species of laboratory animals (Lee, 1962b). With outdoor activities on the increase in many areas, the potential for heterobilharziasis to occur in both humans and animals does exist. Due to the range of hosts that are affected by this parasite, the widespread dissemination of the disease, particularly in a naive population, could be possible. In those animals in which the host-parasite relationship is well balanced (i.e., raccoons) the presence of moderate numbers of adult parasites causes pathology but does not appear to be life threatening. However, in those animals where the host-parasite relationship is not so well balanced (i.e., dogs) an infection can result in acute disease that can often prove fatal (Lee, 1962b; Sponenberg, 1976; Slaughter et al., 1988). Due to the impact on human and animal health the northern spread of *H. americana* is of importance. While not one of the major diseases of wildlife or domestic animal populations at this time, it

should be monitored in the future and its presence in an area should be made known to wildlife specialists, veterinarians and physicians.

We would like to thank S. J. Upton and C. G. Chitko-McKown for reviewing the manuscript and offering suggestions. This manuscript is Kansas Agricultural Experiment Station Contribution Number 90-366-J.

LITERATURE CITED

- BARTSCH, R. C., AND B. C. WARD. 1976. Visceral lesions in raccoons naturally infected with *Heterobilharzia americana*. *Veterinary Pathology* 13: 241-249.
- BURCH, J. B. 1982. Freshwater snails (Mollusca: Gastropoda) of North America. Cincinnati, Ohio. Environmental Monitoring and Support Laboratory Office of Research and Development. Publ. No. EPA-600/3-82-026. United States Environmental Protection Agency, Washington, D.C., 365 pp.
- BURKS, J. W., AND R. C. JUNG. 1960. A new type of water dermatitis in Louisiana. *The Southern Medical Journal* 53: 716-719.
- BYRD, E. E., A. K. PRESTWOOD, AND W. P. MAPLES. 1967. A new host and two new locality records for the blood fluke, *Heterobilharzia americana* Price, 1929. *The Journal of Parasitology* 53: 1115-1116.
- COCKRUM, E. L. 1952. Mammals of Kansas. University of Kansas Publications, Museum of Natural History, Topeka, Kansas, 303 pp.
- CUSTER, J. W., AND D. B. PENCE. 1981. Ecological analyses of helminth populations of wild canids from the gulf coastal prairies of Texas and Louisiana. *The Journal of Parasitology* 67: 289-307.
- FEDYNICH, A. M., D. P. PENCE, AND R. L. URUBEK. 1986. Helminth fauna of beaver from Central Texas. *Journal of Wildlife Diseases* 22: 579-582.
- FORRESTER, D. J., J. A. CONTI, AND R. C. BELDEN. 1985. Parasites of the Florida panther (*Felis concolor coryi*). *Proceedings of the Helminthological Society of Washington* 52: 95-97.
- GOFF, W. L., AND N. C. RONALD. 1981. Certain aspects of the biology and life cycle of *Heterobilharzia americana* in East Central Texas. *American Journal of Veterinary Research* 42: 1775-1777.
- GREGER, D. K. 1915. The Gastropoda of Payne County, Oklahoma. *Nautilus* 29: 88-90.
- KAPLAN, E. H. 1964. *Heterobilharzia americana* Price, 1929, in the opossum from Louisiana. *The Journal of Parasitology* 50: 797.
- KROTOSKI, W. A., C. K. JOB, F. B. COGSWELL, AND E. A. MALEK. 1984. Enzootic schistosomiasis in

- a Louisiana armadillo. *American Journal of Tropical Medicine and Hygiene* 33: 269-272.
- LEE, H. F. 1962a. Life history of *Heterobilharzia americana* Price 1929, a schistosome of the raccoon and other mammals in the Southeastern United States. *The Journal of Parasitology* 48: 728-739.
- . 1962b. Susceptibility of mammalian hosts to experimental infection with *Heterobilharzia americana*. *The Journal of Parasitology* 48: 740-745.
- LEONARD, A. B. 1959. Handbook of gastropods in Kansas. Miscellaneous Publication Number 20, University of Kansas Museum of Natural History, Topeka, Kansas, 224 pp.
- MALEK, E. A., L. R. ASH, H. F. LEE, AND M. D. LITTLE. 1961. *Heterobilharzia* infection in the dog and other mammals in Louisiana. *The Journal of Parasitology* 47: 619-623.
- , AND J. C. ARMSTRONG. 1967. Infection with *Heterobilharzia americana* in primates. *The American Journal of Tropical Medicine and Hygiene* 16: 708-714.
- . 1967. Experimental infection of several lymnaeid snails with *Heterobilharzia americana*. *The Journal of Parasitology* 53: 700-702.
- . 1970. Further studies on mammalian susceptibility to experimental infection with *Heterobilharzia americana*. *The Journal of Parasitology* 56: 64-66.
- , R. B. SHORT, W. H. TEEHAN, AND A. JAMA. 1987. Differential susceptibility of snail hosts to *Heterobilharzia americana* from Texas and Louisiana. *The Journal of Parasitology* 73: 872-873.
- MILLER, G. C., AND R. HARKEMA. 1960. A new locality record for *Heterobilharzia americana* Price, 1929. *The Journal of Parasitology* 46: 206.
- PRICE, E. W. 1929. A synopsis of the trematode family Schistosomidae with descriptions of new genera and species. *Proceedings of the United States National Museum* 75 (Article 18): 1-39.
- . 1943. A redescription of *Heterobilharzia americana* Price (Trematoda: Schistosomatidae). *Proceedings of the Helminthological Society of Washington* 10: 85-86.
- SCHAFER, G. D., W. R. DAVIDSON, V. F. NETTELS, AND E. A. ROLLOR, III. 1981. Helminth parasites of translocated raccoons (*Procyon lotor*) in the southeastern United States. *Journal of Wildlife Diseases* 17: 217-227.
- SHOOP, W. L., AND K. C. CORKUM. 1982. Additional trematodes of mammals in Louisiana with a compilation of all trematodes reported from wild and domestic mammals in the state. *Tulane Studies in Zoology and Botany* 23: 109-122.
- SLAUGHTER, J. B., L. H. BILLUPS, AND G. K. ACOR. 1988. Canine heterobilharziasis. *Compendium of Continuing Education for the Practicing Veterinarian* 10: 606-612.
- SPONENBERG, P. 1976. Heterobilharziasis. *The Southwest Veterinarian* 29: 159-161.
- STAINS, H. J. 1956. The raccoon in Kansas, natural history, management, and economic importance. Miscellaneous Publication Number 10, University of Kansas Museum of Natural History and State Biological Survey of Kansas, Topeka, Kansas, 76 pp.
- THRASHER, J. P. 1964. Canine schistosomiasis. *Journal of the American Veterinary Medical Association* 144: 1119-1125.
- TROY, G. C., D. FORRESTER, C. COCKBURN, L. D. MORTON, R. STORTS, E. WILSON, AND T. CRAIG. 1987. *Heterobilharzia americana* infection and hypercalcemia in a dog: A case report. *Journal of the American Animal Hospital Association* 23: 35-40.
- YAMINI, B., AND T. W. SCHILLHORN VAN VEEN. 1988. Schistosomiasis and nutritional myopathy in a Brazilian tapir (*Tapirus terrestris*). *Journal of Wildlife Diseases* 24: 703-707.

Received for publication 18 February 1990.