

## **Histopathology of Eighth Cranial Nerve of Mass Stranded Dolphins at Goto Islands, Japan**

Authors: Morimitsu, T., Kawano, H., Torihara, K., Kato, E., and Kono, M.

Source: Journal of Wildlife Diseases, 28(4) : 656-658

Published By: Wildlife Disease Association

URL: <https://doi.org/10.7589/0090-3558-28.4.656>

---

BioOne Complete ([complete.BioOne.org](https://complete.BioOne.org)) is a full-text database of 200 subscribed and open-access titles in the biological, ecological, and environmental sciences published by nonprofit societies, associations, museums, institutions, and presses.

Your use of this PDF, the BioOne Complete website, and all posted and associated content indicates your acceptance of BioOne's Terms of Use, available at [www.bioone.org/terms-of-use](http://www.bioone.org/terms-of-use).

Usage of BioOne Complete content is strictly limited to personal, educational, and non - commercial use. Commercial inquiries or rights and permissions requests should be directed to the individual publisher as copyright holder.

---

BioOne sees sustainable scholarly publishing as an inherently collaborative enterprise connecting authors, nonprofit publishers, academic institutions, research libraries, and research funders in the common goal of maximizing access to critical research.

## Histopathology of Eighth Cranial Nerve of Mass Stranded Dolphins at Goto Islands, Japan

T. Morimitsu,<sup>1</sup> H. Kawano,<sup>1</sup> K. Torihara,<sup>1</sup> E. Kato,<sup>1</sup> and M. Koono,<sup>2</sup> <sup>1</sup> Department of Otorhinolaryngology, Miyazaki Medical College, Kiyotake, Miyazaki, Japan; <sup>2</sup> Second Department of Pathology, Miyazaki Medical College, Kiyotake, Miyazaki, Japan

**ABSTRACT:** We examined four dolphins (*Grampus griseus*) of 582 mass-stranded. Almost no contents were found in the alimentary canal. *Nasitrema gondo* and *Crassicauda grampicola* were found in the tympanic cavity. Severe degeneration of the eighth cranial nerve was observed microscopically in all animals and an egg of *Nasitrema* was found in a tissue crevice of the nerve. We propose that the nerves were damaged directly by *Nasitrema*.

**Key words:** Dolphin, *Grampus griseus*, mass stranding, *Nasitrema gondo*, *Crassicauda grampicola*, eighth cranial neuropathy.

Morimitsu et al. (1986, 1987) proposed that parasitogenic eighth cranial neuropathy was a cause of live strandings of dolphins, based on three instances of mass stranding. However, the mechanisms of nerve damage by parasites were not clear.

On 2 November 1990, a herd of approximately 3,000 Risso's dolphin (*Grampus griseus*) was observed offshore, 582 of them stranded at the Miiraku beach of Fukuejima, the Goto Islands, Nagasaki, Japan (32°44'N, 128°41'E).

The members of the Miiraku Fishermen's Union froze four dolphins at -25 C. Six days later, two male and two female dolphins were necropsied. Each alimentary canal, from the stomach to the rectum, was split and the contents were examined macroscopically. There were no apparent fresh wounds on the dolphin heads and no hemorrhagic cerebrospinal fluid following their decapitation. The tympanoperiotic bones (cetoliths) were extracted and stored in 10% formalin solution. Parasites were sought in the tympanic cavity, the eustachian tube, and the pterygoid sinus; all parasites found were stored in 10% formalin. The eighth cranial nerve and the seventh cranial nerve were removed together from the introitus of the

internal auditory canal and sectioned for histological studies at 8  $\mu$  thickness, stained with hematoxylin and eosin, Bodian's and Klueber-Barrera's stains (Luna, 1968).

In all animals the stomachs were completely empty except for a small amount of sand. No remnants such as fish bones or squid beaks were found. The small and large intestines also were completely empty; however, the rectum of animal 4 contained a small amount of mucoid feces. Although the body weight and the thickness of blubber were not measured, the fishermen testified that the animals were clearly thinner than those caught by chance in stationary nets.

Two species of parasites were found in the tympanic cavity and the pterygoid air sinus: *Nasitrema gondo* and *Crassicauda grampicola*. The numbers of *Nasitrema* collected from animals 1 through 4 were 180, 10, 1, and 28 respectively; the numbers of *Crassicauda* in animals 1 through 4 were 2, 21, 8, and 21, respectively. However, since not all parasites could be collected, these are minimum counts. All of the nematodes collected lacked a head. There were many coupled nematodes.

The eighth cranial nerve of all animals had severely degenerated, although the seventh cranial nerve remained roughly unchanged (Fig. 1). Based on the presence of many leucocytes between the degenerated nerve fibers, the degeneration observed in the eighth nerve was premortem. Degree of degeneration of the eighth cranial nerve varied by animal. The most interesting and decisive finding was an egg of *Nasitrema* in a tissue crevice of the nerve of animal 2 (Fig. 1b). This tissue crevice may have been a tunnel made by a *Nasitrema* which crept into the nerve. The

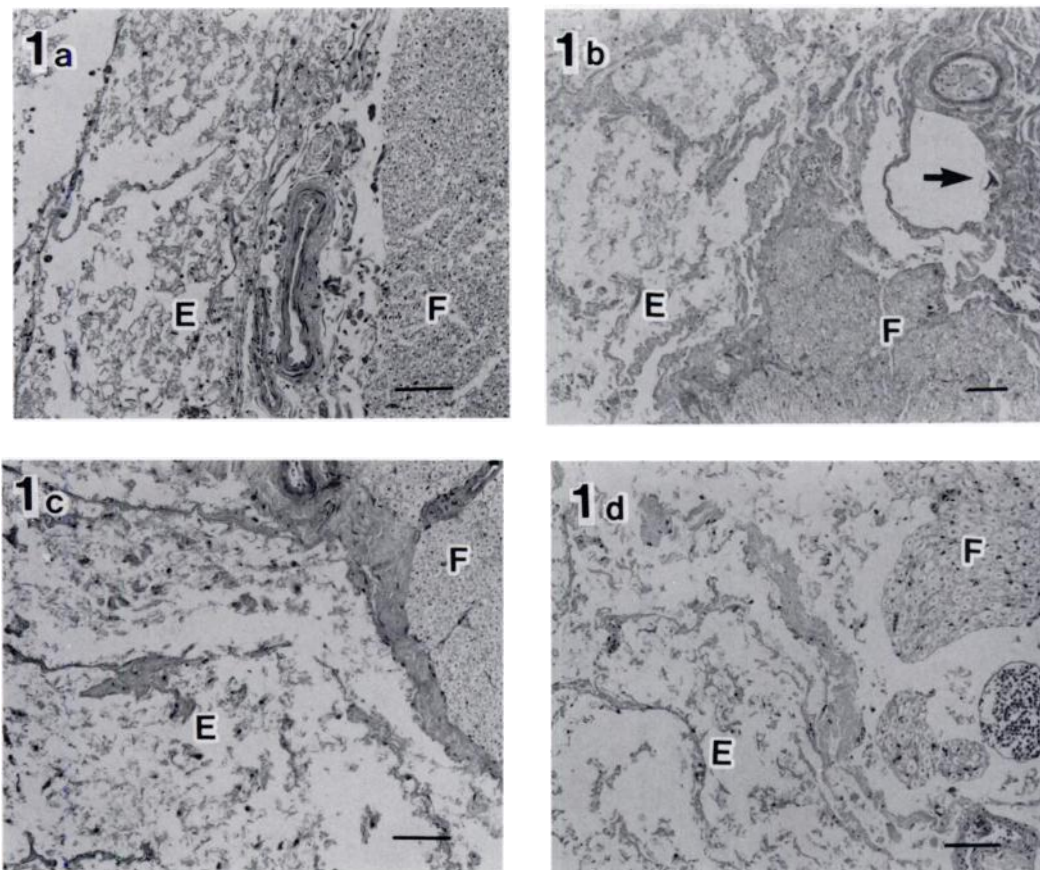


FIGURE 1. The seventh and eighth cranial nerves of animal 1 through animal 4 respectively. Note egg of *Nasitrema* in a tissue crevice of animal 2 (arrow). E, Eighth cranial nerve; F, Seventh cranial nerve. H&E stain. Scale bar is 10  $\mu\text{m}$ .

axon of the eighth nerve stained by Bodian's stain and the sheath of the nerve stained by Kluever-Barrera's stain also had severe degeneration; however, the axon and sheath of the seventh cranial nerve appeared normal.

*Nasitrema gondo* is a common and relatively harmless parasite infecting the pterygoid air sinus of Odontoceti (Walker and Cowan, 1981). However, the parasite can be dangerous and fatal if it infects the tympanic cavity because the eighth cranial nerve has no protective bony covering (Reysenbach de Haan, 1957) and is easily damaged. Dolphins lacking their auditory function cannot catch food. Infestation of *Nasitrema gondo* in the ear and the eighth cranial neuropathy resulting in mass

stranding was reported earlier by Morimitsu et al. (1986, 1987). In these earlier reports it was not clear how *Nasitrema gondo* damaged the nerve. Based on the egg found in a tissue crevice of the nerve, we speculate that *Nasitrema gondo* migrated into the nerve and damaged it directly.

Raga et al. (1982) reported that *Crassicauda grampicola* caused erosion of the pterygoid bone in *Grampus griseus* and postulated that pterygoid parasitism can be an important factor in natural mortality because of the proximity of the ear and brain. The infestation of *Crassicauda grampicola* in the tympanic cavity of mass stranded dolphin was first recorded by us.

It is not clear why the seventh cranial nerve consistently suffered less than the

eighth cranial nerve. Perhaps the susceptibility of these nerves to injury by parasites varies; the eighth cranial nerve is afferent and the seventh cranial nerve is efferent.

We thank the members of the Miiraku Fishermen's Union who collected dolphins, and Drs. Ishii and Kageyama of the Department of Parasitology, National Institute of Health, Tokyo, for identification of the parasites.

#### LITERATURE CITED

- LUNA, L. G. 1968. Manual for histologic staining methods of the Armed Forces Institute of Pathology, 3rd ed. McGraw-Hill Book Company, New York, New York, 258 pp.
- MORIMITSU, T., T. NAGAI, M. IDE, A. ISHII, AND M. KOONO. 1986. Parasitogenic octavus neuropathy as a cause of mass stranding of Odontoceti. *The Journal of Parasitology* 72: 469-472.
- , ———, ———, H. KAWANO, A. NAICHUU, M. KOONO, AND A. ISHII. 1987. Mass stranding of Odontoceti caused by parasitogenic eighth cranial neuropathy. *Journal of Wildlife Diseases* 23: 586-590.
- RAGA, J. A., S. CASINOS, S. FILELLA, AND A. RADUAN. 1982. Notes on cetaceans of the Iberian coast. V. *Crasstacuda grampicola* Johnstone & Mawson, 1941 (Nematoda) cause of injuries in the pterygoids of specimens of *Grampus griseus*. *Säugetierkundliche Mitteilungen* 30: 315-318.
- REYSENBACH DE HAAN, F. W. 1957. Hearing in whales. *Acta Oto-laryngologica Supplementum* 134, 114 pp.
- WALKER, W. A., AND D. F. COWAN. 1981. Air sinus parasitism and pathology in free ranging common dolphins (*Delphinus delphis*) in the eastern tropical Pacific. National Marine Fisheries Service, Southwest Fisheries Center, Administrative Report No. LJ-81-23C, National Oceanic Administration, Washington, D.C., 19 pp.

*Received for publication 15 October 1991.*