

First Report of a *Demodex* sp. in Raccoons (*Procyon lotor*)

Authors: Hamir, Amir N., Snyder, Daniel E., Hanlon, Cathleen A., and Rupprecht, Charles E.

Source: Journal of Wildlife Diseases, 29(1) : 139-141

Published By: Wildlife Disease Association

URL: <https://doi.org/10.7589/0090-3558-29.1.139>

The BioOne Digital Library (<https://bioone.org/>) provides worldwide distribution for more than 580 journals and eBooks from BioOne's community of over 150 nonprofit societies, research institutions, and university presses in the biological, ecological, and environmental sciences. The BioOne Digital Library encompasses the flagship aggregation BioOne Complete (<https://bioone.org/subscribe>), the BioOne Complete Archive (<https://bioone.org/archive>), and the BioOne eBooks program offerings ESA eBook Collection (<https://bioone.org/esa-ebooks>) and CSIRO Publishing BioSelect Collection (<https://bioone.org/csiro-ebooks>).

Your use of this PDF, the BioOne Digital Library, and all posted and associated content indicates your acceptance of BioOne's Terms of Use, available at www.bioone.org/terms-of-use.

Usage of BioOne Digital Library content is strictly limited to personal, educational, and non-commercial use. Commercial inquiries or rights and permissions requests should be directed to the individual publisher as copyright holder.

BioOne is an innovative nonprofit that sees sustainable scholarly publishing as an inherently collaborative enterprise connecting authors, nonprofit publishers, academic institutions, research libraries, and research funders in the common goal of maximizing access to critical research.

First Report of a *Demodex* sp. in Raccoons (*Procyon lotor*)

Amir N. Hamir,¹ Daniel E. Snyder,² Cathleen A. Hanlon,³ and Charles E. Rupprecht,³ ¹Laboratory of Large Animal Pathology, New Bolton Center, University of Pennsylvania School of Veterinary Medicine, 382 West Street Road, Kennett Square, Pennsylvania 19348, USA; ²Department of Agricultural Research Service, Animal Parasite Research Laboratory, PO Box 952, Auburn, Alabama 36831, USA; ³Thomas Jefferson University, Department of Microbiology, Center for Neurobiology, Philadelphia, Pennsylvania 19107, USA.

ABSTRACT: *Demodex* spp. mites were seen in skin sections of 5 of 53 raccoons (*Procyon lotor*) necropsied on Parramore Island, Virginia (USA). In all infections, mites were present in the skin over the lower legs; in one raccoon they also were located in a follicle of a vibrissa. None of the raccoons had *Demodex*-related gross lesions. Histopathologically, minimal lesions were seen in the affected follicles. This is the first documentation of *Demodex* spp. in raccoons.

Key words: *Demodex* spp., raccoons, case report, *Procyon lotor*.

Demodex spp. mites are found in hair follicles or sebaceous glands of most mammals (Yager and Scott, 1985). Although the mites generally are morphologically similar, they are considered separate species when found in different hosts (Yager and Scott, 1985). *Demodex* sp. has not been documented previously in the raccoon (*Procyon lotor*).

During a recent field trial of a vaccinia-rabies glycoprotein (V-RG) recombinant oral vaccine for raccoons (Rupprecht et al., 1986) on Parramore Island, Virginia, USA (Hanlon et al., 1989), tissues of raccoons were examined histopathologically for vaccine-related lesions. At that time *Demodex* sp. was found in some of the raccoons. We document the relevant histopathologic findings in skin sections of raccoons with this parasite.

The V-RG oral vaccine trial on Parramore Island, Virginia (37°32'N; 75°38'W) extended from August 1990 to August 1991. During this time 53 raccoons from the island were live-trapped, euthanized and necropsied (Hanlon et al., 1989). Various tissues, including skin samples from the head and lower limb (forepaw) regions were collected into 10% neutral buffered formalin for histopathological examina-

tion (Hanlon et al., 1989). The tissues were embedded in paraffin, sectioned at 5 μ m and stained with hematoxylin and eosin (H&E) for examination by light microscopy, as previously described (Rupprecht et al., 1986).

Gross lesions attributable to minor physical trauma often were seen on the paws and occasionally on the head. However, no gross abnormalities suggestive of mange were identified in any of the raccoons.

Histopathologically, mites were seen in 5 (9%) of the 53 raccoons examined. In all cases the mites were present in the hair follicles of the leg (Fig. 1) and in one raccoon, they also were present in the skin taken from the face. At the latter site, the mites were located in the hair follicles, as well as in a follicle of vibrissa (Fig. 2). The mites appeared morphologically similar at both the anatomic locations. The mites were slender and cigar-shaped with short stubby legs. Mites were located between the hair shaft and the inner root sheath.

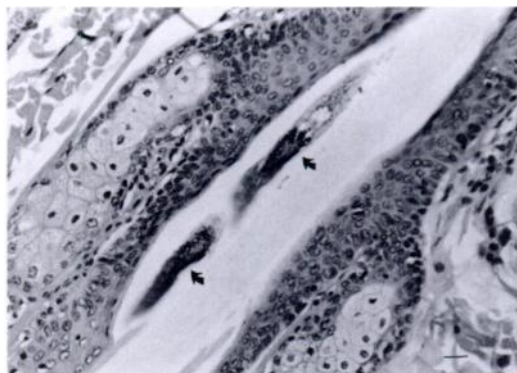


FIGURE 1. Photomicrograph of skin showing presence of two *Demodex* mites (arrows) in the hair follicles of a raccoon. H&E stain. Bar = 50 μ m.

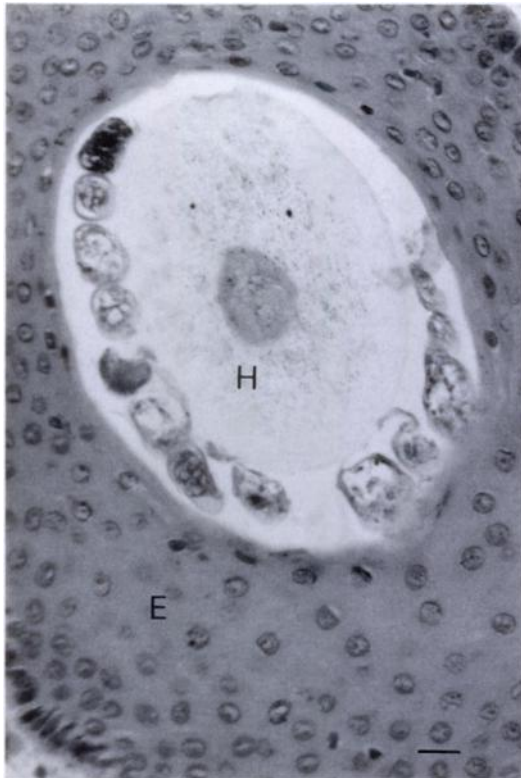


FIGURE 2. Photomicrograph of skin from raccoon facial area, showing cross-sections of numerous mites between the hair shaft (H) and the epidermis (E) within the vibrissa. H&E stain. Bar = 50 μ m.

At both anatomic locations, minor pathologic changes were seen within the affected hair follicles. The epithelium adjacent to the mites was moderately attenuated and some of the epithelial cells in such areas had mild degenerative changes (Fig. 1). A rare finding was a completely degenerated hair follicle containing a mite within the sloughed keratinocytes (Fig. 3). The mites incited a minor cellular response which consisted of a minimal mononuclear cellular infiltrate (predominantly macrophages and a few lymphocytes) into the surrounding dermis (Fig. 3). Morphologically, the mites were similar to *Demodex* sp. in other mammalian hosts.

Several small pieces (0.5 cm square) of skin were removed with a scalpel from the forepaw of one infected raccoon and placed into a 10% solution of potassium hydroxide

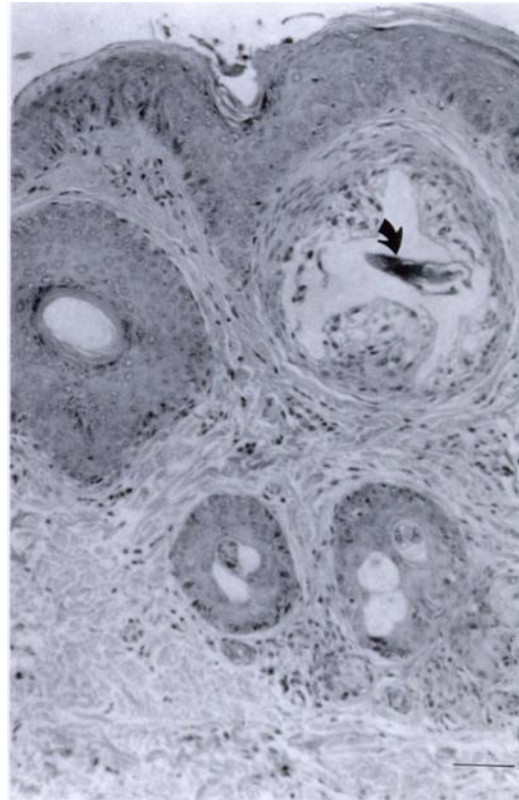


FIGURE 3. Photomicrograph of raccoon skin with a mild inflammatory infiltrate in the dermis. One of the hair follicles contains a section of *Demodex* mite (arrow). The epidermis surrounding the mite is disorganized and the cells are vacuolated. There also is some perifollicular fibrosis. H&E stain. Bar = 100 μ m.

(KOH). After one hour the vial was vigorously shaken by hand for approximately one minute. The pieces of skin were removed from the KOH with forceps, and the liquid portion was centrifuged at 1,500 rpm for 5 min. The liquid was suctioned off and the pellet re-suspended with glycerol. Small amounts of glycerol suspension were placed on glass slides under a coverslip and examined for mites. All stages (ovum, larva, protonymph, nymph, adult) of a demodicid mite were observed in this suspension (Fig. 4). The length (10 specimens each) of adult females and adult males ranged from 175 to 220 μ m (mean = 204, SE = 10.0) and from 160 to 165 μ m (mean = 158, SE = 5.2), respectively. An

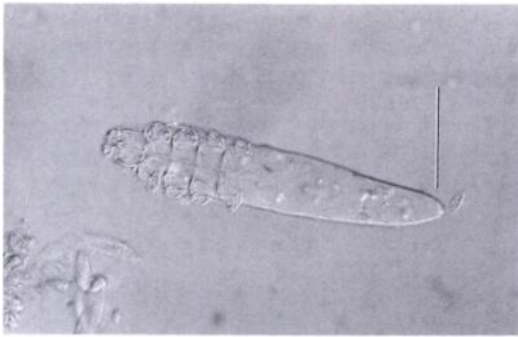


FIGURE 4. A female *Demodex* mite isolated from the formalin-fixed skin (forepaw) of a raccoon. Bar = 50 μ m.

H&E tissue section and several excised pieces of skin in 10% neutral buffered formalin with mites in situ have been deposited in the U.S. National Parasite Collection (Beltsville, Maryland 20705, USA; Accession No.: 82482).

This is the first report of *Demodex* sp. infestation in the raccoon. During the past five years various tissues have been examined, including the skin (usually of ventral abdomen or head) of over 300 raccoons from various areas of the United States (Ohio, Iowa, Pennsylvania, Delaware, Maryland, Virginia and South Carolina) but the presence of this parasite was not found in any of the animals (Hamir, unpubl.). However, the skin from the lower leg was not examined previously in any of these raccoons. Since *Demodex* spp. appeared to be more prevalent in the lower leg regions of the raccoons, this parasite may have been overlooked in the previous raccoon submissions.

Clinical lesions of demodectic infection vary between and within host species. Lesions can either be localized or generalized

and consist of well-circumscribed, erythematous scaly and alopecic patches which are usually present on the head and the extremities. In the generalized form, the lesions are more severe and extensive and may result in secondary bacterial infections (Yager and Scott, 1985).

We found no infected raccoons with any gross or severe histopathologic lesions that were attributed to the mite. This is not unusual since the mites are part of the normal skin fauna of most mammals (Yager and Scott, 1985). Lesions are produced only when the equilibrium between the host and the parasite is altered in favor of the mite (Yager and Scott, 1985).

This study was supported in part by a grant from the Commonwealth of Pennsylvania Department of Agriculture. The technical expertise of R. Buchanan, B. Lehmann and S. Hindman is greatly appreciated.

LITERATURE CITED

- HANLON, C. L., D. E. HAYES, A. N. HAMIR, D. E. SYNDER, S. JENKINS, C. P. HABLE, AND C. E. RUPPRECHT. 1989. Proposed field evaluation of a rabies recombinant vaccine for raccoons (*Procyon lotor*): Site selection, target species characteristics, and placebo baiting trials. *Journal of Wildlife Diseases* 25: 555-567.
- RUPPRECHT, C. E., T. J. WIKTOR, D. H. JOHNSON, A. N. HAMIR, B. DIETZSCHOLD, W. H. WUNNER, L. T. GLICKMAN, AND H. KOPROWSKI. 1986. Oral immunization and protection of raccoons (*Procyon lotor*) with a vaccinia-rabies glycoprotein recombinant virus vaccine. *Proceedings of the National Academy of Sciences, USA* 83: 7947-7950.
- YAGER, J. A., AND D. W. SCOTT. 1985. The skin and appendages. In *Pathology of Domestic Animals*, Vol. 1., 3rd ed. Academic Press, Orlando, Florida, pp. 500-501.

Received for publication 24 February 1992.