

## **An Unidentified Protozon Parasite in the Kidney of the Great-Horned Owl (*Bubo virginianus*)**

Author: HELMBOLDT, C. F.

Source: Bulletin of the Wildlife Disease Association, 3(1) : 23-25

Published By: Wildlife Disease Association

URL: <https://doi.org/10.7589/0090-3558-3.1.23>

---

The BioOne Digital Library (<https://bioone.org/>) provides worldwide distribution for more than 580 journals and eBooks from BioOne's community of over 150 nonprofit societies, research institutions, and university presses in the biological, ecological, and environmental sciences. The BioOne Digital Library encompasses the flagship aggregation BioOne Complete (<https://bioone.org/subscribe>), the BioOne Complete Archive (<https://bioone.org/archive>), and the BioOne eBooks program offerings ESA eBook Collection (<https://bioone.org/esa-ebooks>) and CSIRO Publishing BioSelect Collection (<https://bioone.org/csiro-ebooks>).

Your use of this PDF, the BioOne Digital Library, and all posted and associated content indicates your acceptance of BioOne's Terms of Use, available at [www.bioone.org/terms-of-use](http://www.bioone.org/terms-of-use).

Usage of BioOne Digital Library content is strictly limited to personal, educational, and non-commercial use. Commercial inquiries or rights and permissions requests should be directed to the individual publisher as copyright holder.

---

BioOne is an innovative nonprofit that sees sustainable scholarly publishing as an inherently collaborative enterprise connecting authors, nonprofit publishers, academic institutions, research libraries, and research funders in the common goal of maximizing access to critical research.

## An Unidentified Protozon Parasite in the Kidney of the Great-Horned Owl (*Bubo virginianus*)

C. F. HELMBOLDT

Department of Animal Diseases, University of  
Connecticut, Storrs, Connecticut

Received for publication 15 June, 1966

### ABSTRACT

A protozoan parasite resembling *Klossiella* sp. was found in the collecting tubuli of the kidney from a great-horned owl (*Bubo virginianus*).

### INTRODUCTION

Protozoan parasites occur in the kidney as *Klossiella* spp. in such mammals as the burro<sup>1</sup>, guinea pig<sup>5</sup>, American jack<sup>6</sup>, mouse<sup>7</sup>, and zebra<sup>4</sup>; others of the *Eimeria* spp. have been seen in birds as the goose<sup>2</sup> and woodcock<sup>3</sup>. Even reptiles are not spared, as a *Klossiella* sp. was seen in the kidneys of a boa constrictor<sup>8</sup>. This note reports a protozoan parasite in the kidneys of a great-horned owl (*Bubo virginianus*).

### History and Preparation

The bird was a mature female kept in a zoological garden. It had been live trapped in southern New England a few weeks previously. This placed the date in November 1964. A toe had become infected and hampered the bird's roosting ability. The lesion was so advanced that the toe was removed under local procaine anesthesia. Several hours later the bird died suddenly possibly due to procaine sensitivity. Ten percent formalin was injected into the large wing vein to produce an embalmed state; necropsy was done 12 hours later. Sections,

representative of all body systems, were fixed in formalin, embedded in paraffin, sectioned, and stained by hematoxylin-eosin.

### RESULTS

*Gross pathology.* The body was well fleshed; it was heavily infested by mites which unfortunately were not identified. The digestive system was empty. The toe which had been amputated was almost obliterated by a round (9.0 cm.) mass with a foul smelling necrotic core. Culture of this core resulted in the isolation of *Escherichia coli*.

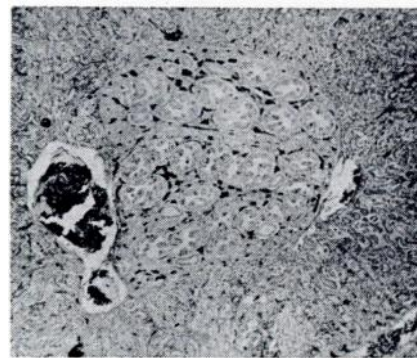


Fig. 1 A group of collecting tubuli occupy the center of the field. It is in these tubuli that the parasite is found.

Scientific Contribution No. 202, Agricultural Experiment Station, University of Connecticut, Storrs.

*Histopathology.* The metatarsal mass consisted of multiple confluent granulomata with copious dense connective tissue stroma.

The only other lesion seen was in the kidney. In the epithelium of the collecting tubules intracytoplasmic parasites were present in great numbers (Fig 1).

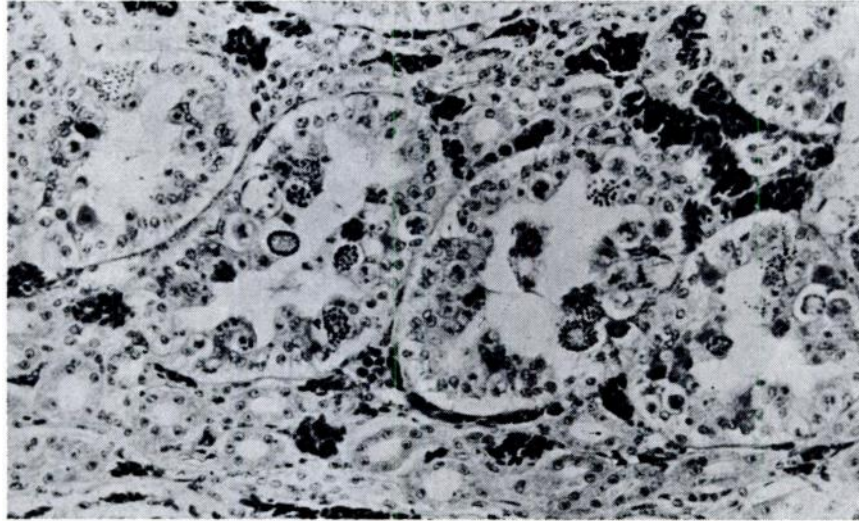


Fig. 2 Collecting tubuli of the kidney contain parasitic forms in the epithelium. Note lack of reaction. The darker masses are erythrocytes.

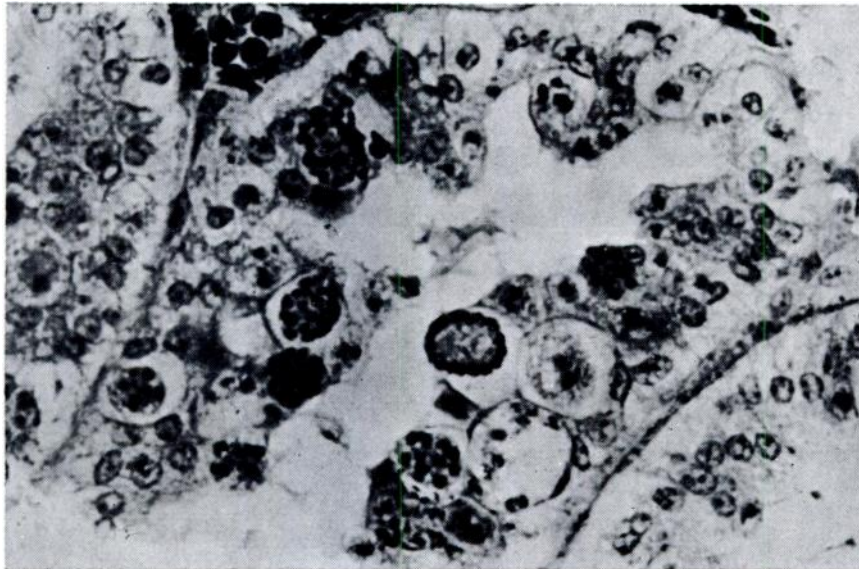


Fig. 3 A higher power view to illustrate the intracellular character of the parasite.

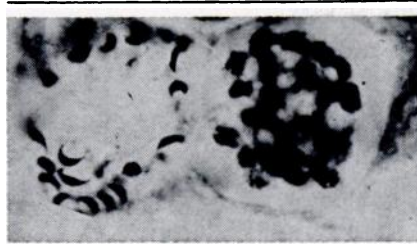

Fig. 4 The small ellipsoidal bodies appear to be leaving a ruptured cell.

The simple cuboidal epithelium had been disrupted as to present irregular piling up with consequent reduction of the lumen (Fig. 2). There was neither hyperplasia of the epithelium nor a phagocytic reaction.

The parasite occurred chiefly as a thin-walled ovoid cyst about 40 x 30 microns and contained numerous irregular basophilic bodies up to 2 microns in diameter; these bodies seemed round and hollow. Focusing up and down revealed many other such bodies. In some of these cysts only the periphery contained solid basophilic bodies (Fig. 3) while the center was finely granular eosinophilic material. Still another but less common form were small vague bodies about 10 microns. In a few areas, oocysts were free of the epithelial cells and seemed to be rupturing and releasing slightly curved, 2 x 12 microns, basophilic bodies (Fig.

4). Up to 20 were counted in one such oocyst.

Parasitic forms were not observed in the ureters.

#### DISCUSSION

The granuloma of the toe was dismissed as being insignificant and probably was caused by the trap used to catch the bird.

Positive identification of a parasite by solely histologic section is difficult and perhaps impossible when encountered for the first time. Comparison with photomicrographs of references cited strongly suggested *Klossiella* sp. as the parasite. The ovoid form with the small forms could be the sporoblast<sup>6</sup>, the large form with the peripheral bodies was the annular ring (macrogametocyte)<sup>5</sup>, and the vague forms the hyaline bodies<sup>5</sup>. The small curved bodies were likely sporozoites.

The parasite caused reaction only in the cells involved but it never elicited an inflammatory reaction. The reaction of the affected cell was more in the nature of compensation for additional cellular contents.

One of the questions naturally arising was the possibility of the existence of the parasite in other great-horned owls. Only three other sections were available from owls necropsied in 1952. These slides failed to show any parasites.

#### LITERATURE CITED

1. HARTMAN, H. A. 1961. The Protozoan Parasite, *Klossiella equi*, in the Mexican Burro. Am. J. Vet. Research 22: 1126-1128.
2. KLIMES, B. 1963. Coccidia of the Goose (*Anser anser dom.*) Zentralbl. Vet. Med., 10: 427-458.
3. LOCKE, L. N., STICKEL, W. H., and GEIS, S. A. 1965. Some Diseases and Parasites of Captive Woodcocks. J. Wildlife Management 29: 155-161.
4. NEWBERNE, J. W., ROBINSON, V. B., and BOWERS, N. C. 1958. Histological Aspects of *K. equi* in the Kidney of a Zebra. Am. J. Vet. Research 19: 304-307.
5. PEARCE, L. 1916. *Klossiella* Infection of the Guinea Pig. J. Exptl. Med., 23: 431-432.
6. SEIBOLD, H. R., and THORSON, R. E. 1955. *Klossiella equi* N. sp. (Protozoa: Klossiellidae) from the Kidney of an American Jack. J. Parasitol., 41: 285-288.
7. WENYON, C. M. 1926. Protozoology: A Manual for Medical Men, Veterinarians and Zoologists. Bailliere, Tindall and Cox, London, 1926.
8. ZWART, P. 1964. Studies on Renal Pathology in Reptiles. Vet. path., 1: 542-556.