

PARASITES OF THE BLACK-BILLED MAGPIE, *Pica pica hudsonia* (Sabine, 1823) FROM NORTHERN UTAH

Authors: TODD, KENNETH S., ERNST, JOHN V., and HAMMOND, DATUS M.

Source: Bulletin of the Wildlife Disease Association, 3(3) : 112-113

Published By: Wildlife Disease Association

URL: <https://doi.org/10.7589/0090-3558-3.3.112>

The BioOne Digital Library (<https://bioone.org/>) provides worldwide distribution for more than 580 journals and eBooks from BioOne's community of over 150 nonprofit societies, research institutions, and university presses in the biological, ecological, and environmental sciences. The BioOne Digital Library encompasses the flagship aggregation BioOne Complete (<https://bioone.org/subscribe>), the BioOne Complete Archive (<https://bioone.org/archive>), and the BioOne eBooks program offerings ESA eBook Collection (<https://bioone.org/esa-ebooks>) and CSIRO Publishing BioSelect Collection (<https://bioone.org/csiro-ebooks>).

Your use of this PDF, the BioOne Digital Library, and all posted and associated content indicates your acceptance of BioOne's Terms of Use, available at www.bioone.org/terms-of-use.

Usage of BioOne Digital Library content is strictly limited to personal, educational, and non-commercial use. Commercial inquiries or rights and permissions requests should be directed to the individual publisher as copyright holder.

BioOne is an innovative nonprofit that sees sustainable scholarly publishing as an inherently collaborative enterprise connecting authors, nonprofit publishers, academic institutions, research libraries, and research funders in the common goal of maximizing access to critical research.

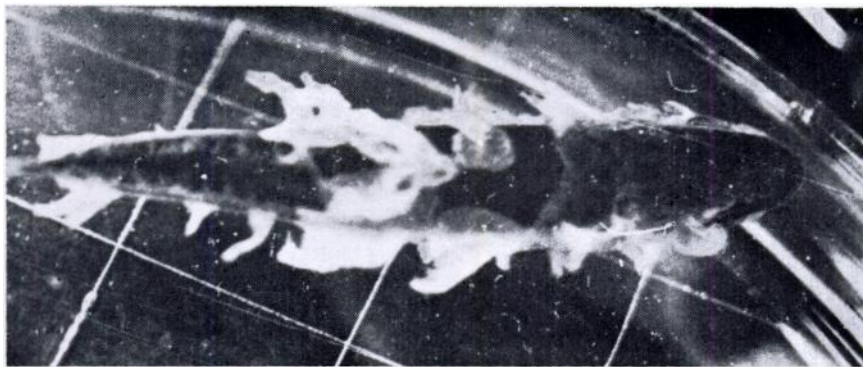


FIGURE 1. Small largemouth black bass with sloughing epithelium due to *Ophryoglena* sp.

appears to be much less plastic. The ciliates are opaque white and, other than the constant shape, their most striking features are the very conspicuous and numerous globules, about 7 - 12 μ in diameter in the cytoplasm. The cytostome, situated about 45 μ from the anterior end, is very conspicuous, unlike that in a mature *Ichthyophthirius*. The lower edge of the cytostome is thickened, obvious, and perhaps similar to the perforatorium of *Cryptocaryon*; the cilia here are 7 to 8 μ long, whereas the body cilia are about 4 μ long. There appears to be a cylindrical membrane of some sort in the "pharynx" which can be seen pulsating (like a clapper) at times. No cytophyge was seen. The macronucleus is large and oval. The cysts are about 90-95 μ in diameter with a cyst membrane ca. 3.5 μ thick. The

conspicuous globules (food vacuoles?) are still present.

This is the first report of *Ophryoglena* parasitizing fish. Other hymenostomes reported from fish include *Ichthyophthirius multifiliis*, a serious pathogen of fish, *Glaucoma* (Hoffman, Parasites of North American Freshwater Fishes, Univ. Calif. Press, 1967, in press) and *Tetrahymena* from European fish (Bykhovskaya-Pavlovskaya *et al.*, Key to Parasites of Freshwater Fish of the U. S.S.R., Eng. transl. TT64-11040, U.S. Dept. Commerce, 1964) and the sea-horse (Moewus, L., J. Protozool. 9, Suppl.: 13, 1962).

GLENN L. HOFFMAN

Eastern Fish Disease Laboratory
U. S. Bureau of Sport Fisheries and Wildlife
Leetown (P.O. Kearneysville), W. Va. 25430
12 May, 1967

**PARASITES OF THE BLACK-BILLED
MAGPIE, *Pica pica hudsonia* (Sabine, 1823)
FROM NORTHERN UTAH**

During March and May 1965, 14 Black-billed Magpies, *Pica pica hudsonia* (Sabine, 1823), were collected near Logan, Cache County, Utah. Of these, 11 (6 males and 5 females) were adults, and three were nestlings of undetermined sex approximately 3 weeks old. Within 24 hours after collection the intestinal

tract was removed, placed in saline solution, and opened along its entire length. The wall of the intestine and the intestinal contents were examined with a dissecting microscope for helminths. Nematodes were fixed in hot glycerine-alcohol and cleared in glycerine. Flatworms and acanthocephalans were fixed in AFA solution and stained with acetoorcein or Harris' hematoxylin. Contents of the large intestine were examined by

the modified Sheather's sugar flotation technique to detect coccidian oocysts and helminth ova. Feces containing oocysts were placed in 2.5% (w/v) potassium dichromate solution at room temperature to sporulate.

RESULTS

Oocysts of *Isospora lacazei* (Labbe, 1893) were present in the intestinal contents of all birds examined. The only other parasite found in nestlings was *Plagiorhynchus* sp. in the small intestine of two specimens. Detailed studies are needed to determine if this is a new species. Some of these specimens have been placed in the collection of Dr. Ralph W. Macy at Portland State College for further identification.

Anomotaenia constricta (Molin, 1858) was present in the small intestine of all adults, and *Hymenolepis farciminosa* (Goeze, 1782) was in the small intestine of two males. All of these specimens had mature proglottids.

Twenty-nine juvenile specimens of *Plagiorhynchus formosus* Van Cleave, 1918 were found attached to the small intestine of one female.

Specimens of *Capillaria anatis* (Dujardin, 1843) were present in the lower small intestine of three females and one male, and specimens of *Microtetrameres* sp. were found in the gastric gland pits of the proventriculus of one female. These resembled *M. corax* Schell, 1953, but because only females were recovered, positive identification could not be made. Specimens of *Acuaria* sp. were present under the koilin layer of the muscular ventriculus of one male and two females. These are being described as a new species in a separate paper.

DISCUSSION

No parasites have previously been reported from the magpie in Utah. The finding of *Plagiorhynchus formosus* represents a new host and geographical record. This parasite was originally described by Van Cleave (1918. Trans.

Amer. Microscop. Soc. 37: 19-47.) from the flicker, *Colaptes auratus*, and according to Schmidt and Olsen (1964. J. Parasitol. 50: 721-730) has been subsequently reported from 12 other species of birds. Travassos (1926. Mem. Inst. Oswaldo Cruz 19: 31-125.) assigned this genus to *Prosthynchus*; however, Schmidt and Kuntz (1966. J. Parasitol. 52: 520-527.) considered *Prosthynchus* to be a synonym of *Plagiorhynchus*.

All other parasites are also new records for Utah. *Isospora lacazei* and *Isospora* sp. have previously been reported from the European magpie, *P. p. pica* (Boughton, 1938. Ohio J. Sci. 38: 149-163; Scholtyssek, 1956. Die Vogelwelt 77: 161-175; and Yakimov and Gusev, 1936. Arch. Inst. Biol. Sao Paulo 7: 189-190), but *Isospora* has not been reported from *P. pica hudsonia*. The oocysts found in the present study fit the description of *I. lacazei* given by various authors. *Isospora rocha-limai* Yakimov and Gusev, 1936 was described from *P. p. pica*. Pellerdy (1965. Coccidia and coccidiosis, Akademia Kiado, Budapest) considered *Isospora* sp. Nemersei, 1949 to be synonymous with *I. rocha-limai*. Because the description of *I. rocha-limai* does not distinguish it from *I. lacazei*, and because of the widespread incidence of *I. lacazei* in passeriform birds, *I. rocha-limai* should probably be considered a synonym of *I. lacazei* until its status is clarified by cross-transmission studies.

Specimens of *P. formosus* were identified by Dr. Gerald D. Schmidt.

KENNETH S. TODD, JR.*

JOHN V. ERNST,

and DATUS M. HAMMOND

Department of Zoology,
Utah State University,
Logan, Utah
16 May, 1967

*Present address:
College of Veterinary Medicine
University of Illinois
Urbana, Illinois