

Mortality Associated with Renal Coccidiosis in Juvenile Wild Greylag Geese (*Anser anser anser*)

Author: Oksanen, Antti

Source: Journal of Wildlife Diseases, 30(4) : 554-556

Published By: Wildlife Disease Association

URL: <https://doi.org/10.7589/0090-3558-30.4.554>

BioOne Complete (complete.BioOne.org) is a full-text database of 200 subscribed and open-access titles in the biological, ecological, and environmental sciences published by nonprofit societies, associations, museums, institutions, and presses.

Your use of this PDF, the BioOne Complete website, and all posted and associated content indicates your acceptance of BioOne's Terms of Use, available at www.bioone.org/terms-of-use.

Usage of BioOne Complete content is strictly limited to personal, educational, and non-commercial use. Commercial inquiries or rights and permissions requests should be directed to the individual publisher as copyright holder.

BioOne sees sustainable scholarly publishing as an inherently collaborative enterprise connecting authors, nonprofit publishers, academic institutions, research libraries, and research funders in the common goal of maximizing access to critical research.

Mortality Associated with Renal Coccidiosis in Juvenile Wild Greylag Geese (*Anser anser anser*)

Antti Oksanen, National Veterinary and Food Research Institute, Regional Laboratory Oulu P.O. Box 517, FIN-90101 Oulu, Finland. Present address: Vetmest, Centre of Veterinary Medicine Tromsø, N-9005, Tromsø, Norway

ABSTRACT: Fourteen non-flying wild greylag (*Anser anser anser*) goslings were reported dead on the Bothnian Bay coast of Finland in July and August, 1992. Renal coccidiosis caused by *Eimeria truncata* was isolated from all three of the goslings necropsied.

Key words: *Eimeria truncata*, kidney, coccidia, greylag goose, *Anser anser anser*.

Renal coccidiosis caused by *Eimeria truncata* is a serious disease wherever domestic geese, *Anser anser domestica* are raised, causing heavy mortality among goslings, particularly in flocks crowded under poor hygienic conditions (Soulsby, 1982). This renal coccidium frequently has been discovered in various species of wild geese as well (Tuggle and Crites, 1984). Other renal coccidia have been reported in other waterfowl and waterbirds (Gajadhar et al., 1983; Leighton and Gajadhar, 1986; Gajadhar and Leighton, 1988), but the reports usually have been based on asymptomatic birds shot by hunters or collected for research purposes. Natural mortality in wild geese has been reported from the Scandinavian countries (Christiansen, 1952; Waldén, 1961).

The first observation of renal coccidiosis on the Finnish part of the Bothnian Bay coast was made on a small islet (65°07'N, 25°10'E) on 15 July 1992, when a fisherman captured a greylag (*Anser anser anser*) gosling being harassed by herring gulls (*Larus argentatus*). The bird was weak and died the next day. At necropsy it was emaciated, with a mass of 630 g, and had minor bruises in the head and neck regions, probably caused by the gulls. Gross examination did not reveal abnormalities in any of the organs, including the kidneys. For routine bacteriology, liver, heart and intestine samples were cultured on bromthymol blue lactose agar (Merck 1639; E.

Merck, Darmstadt, Germany) and caso agar (Merck 5458) supplemented with 5% bovine blood. All the plates were incubated at 37 C for two days. Specimens from the brain, lung, heart, liver, kidney, spleen and intestine were fixed in 10% neutral buffered formalin, embedded in paraffin, sectioned at 4 µm thickness and stained with hematoxylin and eosin (H&E). Bacteriological tests were negative. Based on histology, we diagnosed the occurrence of renal coccidiosis. Emaciation was considered the cause of death.

On 20 August 1992, 13 greylag goslings at varying stages of putrefaction were found on the very small island of Päänpäällinen, Finland (65°14'N, 24°55'E). They had died before flying, based on their juvenile wing feathers. This isolated island is about 200 m long, 10 to 20 m wide, less than 1 m high, and is vegetated with small willow bushes (*Salix* sp.), herbs (*Matricaria* sp., *Potentilla* sp.) and Gramineae (especially *Phragmites communis*). The vegetation, particularly *P. communis*, appeared to be overgrazed. The one bird necropsied (Fig. 1) was emaciated, with a total lack of fat and the alimentary canal almost empty. It had a body mass of 1,180 g. The only other finding was that the kidneys were enlarged many times normal, with a mass of 69 g and with white, dilated tubules. Direct smears of the ureter content contained masses of coccidian oocysts. Bacteriological and histological examinations were performed as described for the first bird found in July. No specific bacterial infection was found. Based on histological examination, we observed very severe destruction of the normal tubular structure of the kidneys (Fig. 2). There was a slight reaction, as inflammatory cells had accumulated in the interstitial tissue. Apart

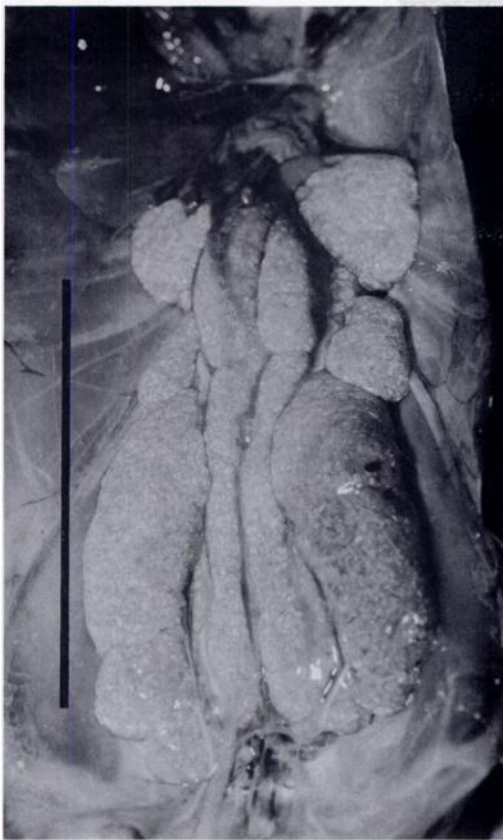

FIGURE 1. Renal coccidiosis (*Eimeria truncata*) in a greylag (*Anser anser anser*) gosling. The kidneys are greatly enlarged and pale. The bird is emaciated. Bar = 10 cm.

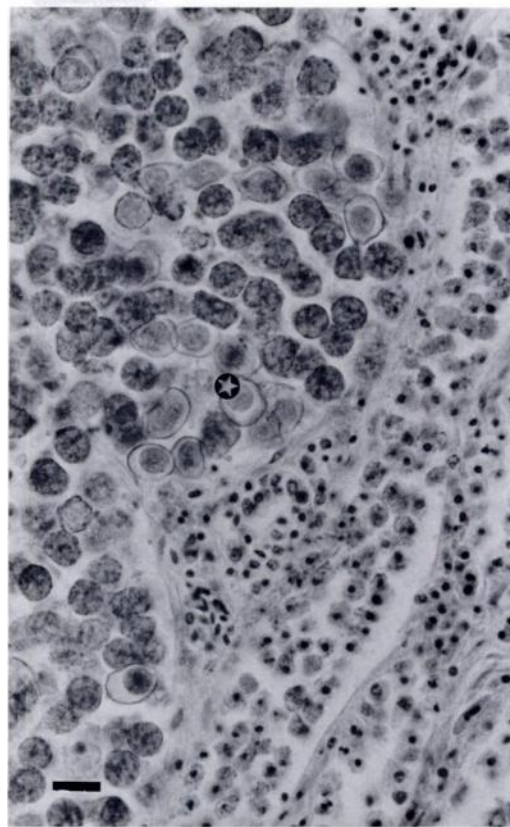


FIGURE 2. Histological section of the kidney from the bird in Figure 1 showing a dilated renal tubule containing gamonts and immature oocysts (●), H&E stain. Bar = 20 μ m.

from the coccidian oocysts, a large amount of material resembling urate crystals was evident in the collecting tubules. We diagnosed the cause of death as renal coccidiosis.

Only about 1% of oocysts harvested from the ureters and kidneys sporulated when placed in 2% potassium dichromate solution at 20 to 21C. Unsporulated and sporulated oocysts were morphologically consistent with descriptions of *E. truncata* (Christiansen, 1952; Gajadhar et al., 1983). A striking feature was folding and crimping of the walls of the sporulated oocysts in the sugar flotation fluid, which was not so often found with the unsporulated oocysts, as also reported by Christiansen (1952).

The only gosling still remaining on the

island on 30 August was necropsied. It was emaciated, weighing 995 g. Autolysis was widespread, but the kidneys were greatly enlarged, with a mass of 37 g, and were variegated with white matter. Direct kidney smears contained a large number of oocysts. The histological picture was almost the same as in the gosling from 20 August. Renal coccidiosis was again considered the cause of death.

The greylag goose population on the Finnish coast of the Bothnian Bay has increased greatly since the 1950's because of the strict regulation of shooting. As the number of suitable nesting sites is limited, the population density has increased on some small islands. The nesting season of 1992 was very warm initially but, after midsummer, the weather turned cool,

windy and rainy. The warm early summer may have led to a high number of goslings trying to feed on the overgrazed vegetation in later summer. Although only two of the 13 goslings reported dead on the island were examined, the consistent findings are evidence that the other 11 also may have died of renal coccidiosis. As the island is isolated, it is probable that all of them, and perhaps even more, hatched on the island. Overcrowding and the rainy weather may have led to the accumulation of large numbers of coccidian oocysts from softened excretions, and together with the inadequate nutrition, these may have contributed to the fatal coccidiosis.

Soon after the discovery of the outbreak, an expedition was sent to examine other known goose islands in the north-eastern part of the Bothnian Bay, but no dead goslings were found.

I thank E. Lindgren, P. Nieminen, P. Sergejeff and J. Ylönen for helping in investigating the outbreak and A. A. Gajadhar for valuable comments on the manuscript.

LITERATURE CITED

- CHRISTIANSEN, M. 1952. Nyrecocciidose hos vildtlevende andefugle (Anseriformes). *Eimeria somateriae* n. sp. hos ederfugl (*Somateria mollissima* (L)). [In Danish with English summary] *Nordisk Veterinaermedicin* 4: 1173-1191.
- GAJADHAR, A. A., AND F. A. LEIGHTON. 1988. *Eimeria wobeseri* sp. n. and *Eimeria goelandti* sp. n. (Protozoa: Apicomplexa) in the kidneys of herring gulls (*Larus argentatus*). *Journal of Wildlife Diseases* 24: 538-546.
- , R. J. CAWTHORN, G. A. WOBESER, AND P. H. G. STOCKDALE. 1983. Prevalence of renal coccidia in wild waterfowl in Saskatchewan. *Canadian Journal of Zoology* 61: 2631-2633.
- LEIGHTON, F. A., AND A. A. GAJADHAR. 1986. *Eimeria fraterculae* sp. n. in the kidneys of Atlantic puffins (*Fratercula arctica*) from Newfoundland, Canada: Species description and lesions. *Journal of Wildlife Diseases* 22: 520-526.
- SOULSBY, E. J. L. 1982. Helminths, arthropods and protozoa of domestic animals, 7th ed., Bailliere Tindall, London, England, 809 pp.
- TUGGLE, B. N. AND J. L. CRITES. 1984. Renal coccidiosis in interior Canada geese, *Branta canadensis interior* Todd, of the Mississippi Valley population. *Journal of Wildlife Diseases* 20: 272-278.
- WALDÉN, H. W. 1961. Observations on renal coccidia in Swedish anseriform birds, with notes concerning two new species, *Eimeria boschadis*, and *Eimeria christianseni* (Sporozoa, Telosporidia). *Arkiv för Zoologi* 15: 97-104.

Received for publication 2 March 1994.