

## **EXPERIMENTAL VITAMIN A DEFICIENCY IN MALLARDS (ANAS PLATYRHYNCHOS): LESIONS AND TISSUE VITAMIN A LEVELS**

Authors: Honour, Sandra M., Trudeau, Suzanne, Kennedy, Sean, and Wobeser, Gary

Source: Journal of Wildlife Diseases, 31(3) : 277-288

Published By: Wildlife Disease Association

URL: <https://doi.org/10.7589/0090-3558-31.3.277>

---

The BioOne Digital Library (<https://bioone.org/>) provides worldwide distribution for more than 580 journals and eBooks from BioOne's community of over 150 nonprofit societies, research institutions, and university presses in the biological, ecological, and environmental sciences. The BioOne Digital Library encompasses the flagship aggregation BioOne Complete (<https://bioone.org/subscribe>), the BioOne Complete Archive (<https://bioone.org/archive>), and the BioOne eBooks program offerings ESA eBook Collection (<https://bioone.org/esa-ebooks>) and CSIRO Publishing BioSelect Collection (<https://bioone.org/csiro-ebooks>).

Your use of this PDF, the BioOne Digital Library, and all posted and associated content indicates your acceptance of BioOne's Terms of Use, available at [www.bioone.org/terms-of-use](http://www.bioone.org/terms-of-use).

Usage of BioOne Digital Library content is strictly limited to personal, educational, and non-commercial use. Commercial inquiries or rights and permissions requests should be directed to the individual publisher as copyright holder.

---

BioOne is an innovative nonprofit that sees sustainable scholarly publishing as an inherently collaborative enterprise connecting authors, nonprofit publishers, academic institutions, research libraries, and research funders in the common goal of maximizing access to critical research.

## EXPERIMENTAL VITAMIN A DEFICIENCY IN MALLARDS (*ANAS PLATYRHYNCHOS*): LESIONS AND TISSUE VITAMIN A LEVELS

Sandra M. Honour,<sup>1</sup> Suzanne Trudeau,<sup>2</sup> Sean Kennedy,<sup>2</sup> and Gary Wobeser<sup>1</sup>

<sup>1</sup> Department of Veterinary Pathology, Western College of Veterinary Medicine,  
University of Saskatchewan, Saskatoon, Saskatchewan, Canada

<sup>2</sup> Environment Canada, Canadian Wildlife Service, National Wildlife Research Centre,  
Hull, Quebec, Canada

**ABSTRACT:** Captive mallards (*Anas platyrhynchos*), fed an all-grain diet for up to 5 months during the winters of 1991 to 1992 and 1992 to 1993, developed lesions of squamous metaplasia; some had no detectable hepatic vitamin A. Vitamin A deficiency in mallards was defined as hepatic levels of retinyl palmitate  $<2 \mu\text{g/g}$  liver. Lesions were found only in ducks with low levels of hepatic vitamin A, but not all ducks with these low levels of hepatic vitamin A had histological lesions. The prevalence of lesions in the esophagus was greatest cranially and caudally and less common in the central region. Palatine salivary glands rarely were affected. Mallards with liver stores  $>600 \mu\text{g}$  of hepatic retinyl palmitate per g liver, fed a diet deficient in vitamin A were unlikely to become deficient over a 5 month period. Birds fed an all-grain diet had significantly lower vitamin A concentrations in their liver compared to those fed an all-grain diet with vitamin A added. Liver weight, when corrected for body size, did not affect vitamin A concentration. Serum retinol levels were conserved over a large range of hepatic vitamin A levels but levels below  $300 \mu\text{g}$  retinol/l were useful in detecting vitamin A deficiency in captive mallards. Based on the findings, the presence of lesions provides a conservative measure of vitamin A status in ducks and tissue levels should be measured in instances when mallards have questionable vitamin A status.

**Key words:** Vitamin A deficiency, mallard, *Anas platyrhynchos*, hypovitaminosis A, retinol, retinyl palmitate, diet.

### INTRODUCTION

Vitamin A deficiency has been recognized in domestic poultry for many years but seldom has been detected in wild birds. Vitamin A deficiency has been diagnosed in birds on the basis of the presence of squamous metaplasia of the esophagus and other mucus-secreting glands. Wintering black ducks (*Anas rubripes*) in Massachusetts, (USA), with lesions associated with vitamin A deficiency were reported by Hagar (1950); also mallards (*Anas platyrhynchos*) found dead in winter near Gardiner Dam, Saskatchewan, Canada, had lesions consistent with vitamin A deficiency (Wobeser and Kost, 1991).

There has been a trend for mallards and other waterfowl to winter north of their traditional wintering grounds (Bellrose, 1976) in areas which have open water year-round. Vitamin A deficiency may occur in these birds because they feed almost exclusively on grain while other food sources

are not available for up to 5 mo of the winter (Jorde et al., 1983; Clark and Sugden, 1990). Grain, with the exception of yellow corn, contains only trace amounts of vitamin A or vitamin A precursors so these birds may be on a deficient diet for several months (Scott and Dean, 1991). Grain diets also may cause other nutritional problems; for example corn or soybean diets for 3 mo appeared nutritionally sub-optimal for maintenance of body weight by female mallards (Loesch and Kaminski, 1989). Daily intake of vitamin A is not required because vitamin A is stored, principally in the form of retinyl palmitate in the liver. However, the ability of ducks to survive over winter without a dietary source of vitamin A has not been evaluated.

Vitamin A deficiency in birds usually is diagnosed on the basis of gross and histologic lesions. Metaplasia of mucous surfaces of respiratory, digestive and repro-



ductive tracts in chickens with hypovitaminosis A has been described as beginning with degeneration of the lining epithelium and mucous glands, followed by replacement of original epithelium by stratified keratinized squamous epithelium (Jungherr, 1943). Squamous metaplasia transforms mucous glands of the esophagus to keratin filled, dilated cysts that are grossly visible as white plaques (Jungherr, 1943). Immune system malfunction has been associated with vitamin A deficiency in several species (Sijtsma et al., 1990; Tengerdy et al., 1990). Vitamin A deficient chickens have exhausted lymphoid cell stores and are unable to mount an effective immune response when challenged with infectious agents. Immunodysfunction may occur before other clinical signs of deficiency are evident (Bang et al., 1975; Nauss, 1984). Given the effect that vitamin A deficiency has on the immune system, and that damaged epithelial surfaces may provide a portal of entry for disease causing agents (Jungherr, 1943), there is a possible relationship between vitamin A status and susceptibility to disease.

Our objectives were to determine if vitamin A deficiency would occur in mallard ducks fed an *ad libitum* grain diet over a 5-mo period, develop a method for staging and scoring microscopic changes of vitamin A deficiency, determine if a decline in body condition and morphological changes occurred in vitamin A-deficient mallards, and determine the relationship between pathological lesions and hepatic and serum retinol and retinyl palmitate levels. Experiment 1 was designed as a trial to determine protocol and define vitamin A deficiency. Experiment 2 was designed to more closely simulate the winter conditions endured by wild mallards in Saskatchewan and to use ducks that had been fed a natural diet previous to the study. Experiment 3, run in conjunction to the second, brought mallards from a different source to increase the number of birds in this study. Pre-experimental diet and source of birds were confounders which

forced stratification of data from all three experiments for analysis.

#### MATERIALS AND METHODS

In Experiment 1, we obtained 54 captive-bred, male mallard ducks, supplied as young of the year (Whistling Wings Incorporated, Hanover, Illinois, USA), that were wing-banded and then held for acclimation for 7 days. The ducks were housed in indoor holding rooms at 15 C, and with 8 hr of artificial light per day for the entire study. The ducks had access to Number 2 grit and water for bathing and drinking. The diet used during acclimation was a commercial duck and goose grower ration formulated to contain 8,800 IU vitamin A/kg as fed (Federated Cooperative Ltd. No. 93104, Saskatoon, Saskatchewan) to which an increasing amount of pelleted wheat and barley (1:1 w/w) was added each day during the week. After 1 wk acclimation, birds were randomly divided into control and deficient diet groups. The control group was fed pelleted wheat and barley supplemented with 4,000 IU of vitamin A/kg of feed (Rovimix A 500 Type P, Hoffmann-La Roche, Mississauga, Ontario, Canada), *ad libitum*. The deficient diet group was fed pelleted wheat and barley without added vitamin A *ad libitum*. Six birds were sampled from each group by random selection every 21 days for a total of 84 days.

In Experiment 2, 31 female and 19 male mallards were obtained in Canada from a captive breeding study being run by the Canadian Wildlife Service (Saskatoon, Saskatchewan). The birds were the 4 to 5 mo-old offspring of captive reared mallards and had been housed in a large outdoor pen in a marsh environment. Natural foods available from the pen had been supplemented with barley and commercial poultry supplement (3:1) for 4 mo prior to transportation to new housing. Birds were banded and randomly divided into two groups containing approximately equal numbers of each sex. They were placed in two new, grass-bottomed 3 × 6 m outdoor enclosures, and were offered unprocessed wheat and barley, pelleted wheat and barley, and Number 2 grit *ad libitum* for 46 days prior to the study. The birds also had access to leafy green alfalfa hay during this period. On day 0 of Experiment 2 (2 November 1992), control birds were changed to a diet of pelleted wheat/barley (1:1 w/w) supplemented with 4,000 IU vitamin A/kg feed. As in Experiment 1, deficient diet birds were fed only the pelleted wheat and barley with no added vitamin A. No grass was available at this time and the leafy hay was removed from the pens. Birds were housed outdoors with ice-free water for swim-

ming and drinking. Birds were moved indoors during a severe cold period from 29 December 1992 (Day 57) to 10 January 1993 (Day 69) and then moved back outdoors. Birds were randomly sampled while controlling for sex. On day 0, and in the second, third, fourth and fifth months, four to six birds were to be sampled from each group. Unexpected deaths occurring in the second and third month of the study disallowed us from randomly sampling during these two months. During the remaining months, birds were sampled randomly.

Experiment 3 was run in conjunction with Experiment 2 but the mallards were from a different source. Twelve birds (5 to 6 mo-old males) were supplied by Kortright Waterfowl Park (Guelph, Ontario) and had been fed a commercial diet prior to being shipped. The mallards were randomly divided into control and deficient diet groups. The birds were fed the same pre-study diet as ducks from Experiment 2 for 17 days prior to the study. The deficient diet and control groups were fed the same rations as equivalent groups in Experiment 2 and two to three randomly chosen birds were killed at the same time intervals as birds from Experiment 2. Three birds from the deficient diet group died unexpectedly during the second and third months of the study and are included as the sample for that time period.

Vitamin A levels in feed were evaluated at the beginning and end of each study by Hoffmann-La Roche (Mississauga, Ontario, Canada), by thin layer chromatography. Beta carotene levels were determined by the Saskatchewan Feed Testing Laboratory, University of Saskatchewan, Saskatoon, Saskatchewan using the method of the Association of Official Analytical Chemists (1990).

Postmortem procedures were similar in all experiments. Sampled ducks were killed by carbon dioxide asphyxiation. Blood was collected by intracardiac puncture from birds immediately after respiration ceased. Blood was held at 37 C for several hours while protected from light, to allow proper clotting. Body weight of each bird was adjusted by adding the weight of the blood sample collected. The weight of food in the crop and proventriculus was subtracted from the total weight. In Experiments 2 and 3, the observed body score was recorded on a scale of 1 to 5; with 1 having no observable fat stores, 2 having some apparent abdominal fat pad, 3 having additional pericardial fat as well as subcutaneous fat, 4 having additional large amounts of fat in the peri-esophageal and tracheal regions, and 5 having fat stores in all the aforementioned locations, together with subcutaneous fat of >5 mm depth and fat apparent dorsal to the kidneys. The liver was removed,

weighed and a sample approximately 4 mm thick was collected from the cranial portion through all lobes of the liver of each duck and was wrapped in nonporous plastic, placed in a 20 ml scintillation vial and frozen in liquid nitrogen (−170 C). Samples subsequently were removed from liquid nitrogen and stored at −80 C until evaluated. A standardized body score (SBS) was created by dividing body weight by the sum of head-beak and keel lengths. This was done because body weight alone was not a good indicator of body condition due to a variation in skeletal size (Loesch and Kaminski, 1989). The right pectoral muscles were weighed after dissection from the sternum. The heart (Experiments 2 and 3 only), right kidney, and spleen were weighed. The head, beak, esophagus and trachea were removed and inspected for lesions. These tissues, together with the right kidney, were fixed for a minimum of 2 days in 10% phosphate buffered neutral formalin. The head, beak, esophagus and trachea then were placed in 20% formic acid for 48 hr to decalcify prior to trimming. Histological examination was performed on all ducks. Samples for histological examination were taken from the caudal pole of the kidney, a cross-section of the rostrum immediately caudal to the external nares and three cross-sections of the trachea and esophagus; one was just caudal to the oral-esophageal junction, another was just proximal to the syrinx or tracheal bifurcation and the third was taken at the midpoint between these two. Five-micron-thick paraffin-embedded sections, stained with hematoxylin and eosin were prepared. All histological sections were coded and examined microscopically without knowledge of the bird of origin. The number of glands in each section of the esophagus was counted. Glands were classified as normal, metaplastic or metaplastic and keratotic. Metaplasia was defined as those glands in which squamous cells were evident together with evidence of loss of mucous secreting cells and/or an increase in the number of basal cells. Keratosis was defined as those glands with metaplastic changes plus keratinized squamous cells visible in the lumen (Fig. 1). The prevalence of the changes in each section was recorded.

Retinoid analysis was similar for all experiments. Frozen liver and serum samples were transported on dry ice to the Environment Canada Biomarker Laboratory, Environment Canada, National Wildlife Research Centre in Hull, Quebec, for hepatic retinol (HROL) and retinyl palmitate (HRPT) and serum retinol (SROL) determination. Liver and serum samples were protected from white light ( $\lambda < 500$  nm) by using gold fluorescent lights and amber glassware; 300 to 500 mg samples of liver were dehydrated to a pink powder by grinding with

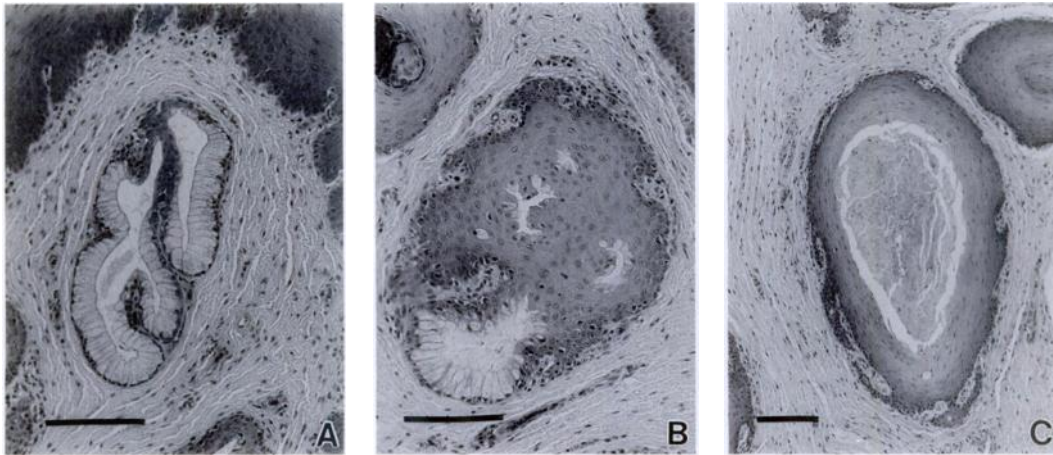


FIGURE 1. Esophageal glands of mallard ducks. A. normal; B. metaplastic; C. keratotic and dilated (H&E). Bar 100  $\mu$ .

anhydrous sodium sulphate. The internal standard, retinyl acetate (40 ng/20  $\mu$ l methanol), was added to the equivalent of 0.20 g of liver and the vitamin A compounds were extracted in 10 ml of a 1:9, dichloromethane : methanol solvent mixture in an amber colored vial. After centrifugation for 10 min at 600 rpm at 10 C, the supernatant was filtered through a 0.2  $\mu$ m Acrodisc LC13 PVDF filter (Gelman Sciences Ltd., Ann Arbor, Michigan, USA) and a 20  $\mu$ l aliquot was analyzed in duplicate by non-aqueous reverse-phase high performance liquid chromatography (HPLC). Separation of retinol, retinyl acetate and retinyl palmitate was achieved with a 15 cm long, 5  $\mu$ m ODS Zorbax column (Dupont, Wilmington, Delaware, USA) with 100% methanol at 1 ml/min for 5.5 min followed by a linear gradient which brought the mobile phase to 30% dichloromethane and 70% methanol within 0.5 min. This composition was held until the end of the run at a flow rate of 2.0 ml/min. With these conditions, retinol, retinyl acetate and retinyl palmitate had retention times of 3.1, 4.2, and 9.7 min, respectively. Retinoid compounds were detected with an ultraviolet-visible detector (326 nm) or a fluorescence detector with an excitation monochromator set at 336 nm and the emission monochromator set at 480 nm (EX: 336 nm; EM: 480 nm) (Olson, 1979). The minimum detection limits for retinol and retinyl palmitate in avian liver were 0.1 and 0.4  $\mu$ g/g of liver, respectively. Levels below detection limits were assigned a zero (0) value. The method used to determine retinol levels in serum was modified from Deleenheer and Nelis (1990). The internal standard, retinyl acetate, was added to 100  $\mu$ l of serum. The retinol-protein complex was dissociated by the addition of

200  $\mu$ l of acetonitrile. The retinol was extracted twice, using 4 ml and 1 ml of hexane, respectively. The organic and aqueous phases were separated by centrifugation. The combined organic phases were evaporated to dryness under a stream of nitrogen and the residue was reconstituted in 1 ml of methanol, and filtered through a 0.2  $\mu$ m Acrodisc LC13 PVDF filter; a 50  $\mu$ l aliquot was analyzed in duplicate by HPLC using a 15 cm long, 5  $\mu$ m ODS Zorbax column. With 100% methanol as the mobile phase and a flow rate of 1 ml/min, retinol and retinyl acetate have a retention time of 3.3 and 4.5 min respectively. Minimum detection limits for serum retinol were not a factor.

Values of hepatic vitamin A were approximated by converting HRPT to equivalent grams of retinol ( $\text{HRPT} \times 0.55 \text{ g retinol/g retinol palmitate}$ ) and then adding this value to HROL for a total vitamin A content per g liver in our ducks. This allowed comparison of our vitamin A values to levels determined historically by saponification techniques (1 IU vitamin A = 0.3 mg retinol) (Schoeff, 1983).

Birds unexpectedly found dead were tissue sampled and a routine postmortem examination was performed. Any abnormal lesions were cultured on 5% sheep blood agar and MacConkey agar plates (PML Microbiologicals, Richmond, British Columbia, Canada) and incubated aerobically at 37 C. Bacteria isolated were identified on the basis of morphology and biochemical reactions (Carter and Cole, 1990).

Statistical analyses were performed on each experiment separately using Statistix 4.0 (Analytical Software, St. Paul, Minnesota, USA). All data were tested for abnormal distribution using the Wilk-Shapiro test. Many samples failed to

TABLE 1. Vitamin A content of diets (IU/kg, wet weight) fed to captive mallards. Experiment 1, September to December 1991. Experiments 2 and 3, November 1992 to April 1993.

		Initial vitamin A <sup>a</sup>	Final vitamin A <sup>b</sup>
Experiment 1	Control diet	4,040	1,780
	Deficient diet	194	126
Experiments 2 and 3	Control diet	4,640	1,460
	Deficient diet	461	298
	Hay	710 <sup>c</sup>	NT <sup>d</sup>
	Wheat/barley	557	NT <sup>d</sup>

<sup>a</sup> At beginning of trial.<sup>b</sup> At completion of trial.<sup>c</sup> Not including beta carotene.<sup>d</sup> NT = not tested.

meet the parametric assumption of normality but this can be due to the limitation of this test with small sample sizes (Shapiro and Wilk, 1965). We have reported means, standard deviation and significance, using parametric tests, of all continuous data except vitamin A values. Because of low numbers and abnormal distribution of vitamin A levels in both diet groups, we have reported the median and range for all vitamin A values and analyzed all vitamin A values non-parametrically using the median test (Zar, 1984). One way analysis of variance (ANOVA) was used to test the effect of diet, sex and unexpected deaths on standardized body score, body weight, and organ weights of each sample day. Kruskal-Wallis one way analysis was used to test the effect of diet on observed body score and vitamin A levels (Zar, 1984). Two way ANOVA was performed to test the effect of diet and time on measured parameters over the course of each experiment (Zar, 1984). Linear correlations were performed to determine relationships of HRPT to HROL and SROL. Natural log transformation of the SROL and HRPT levels was required to achieve a good linear correlation (Zar, 1984). Hepatic retinyl palmitate levels had 0.5 added to them before the log transformation to correct for the error associated with including the natural log of zero (Zar, 1984). To determine if liver size had an effect on vitamin A concentrations, a multiple regression, in which liver weight was regressed on body weight and the sum of head-beak plus keel lengths, was performed (Zar, 1984). The residual values from this regression were compared to the vitamin A concentrations.

## RESULTS

Vitamin A in the feed used in each experiment decreased in concentration from the beginning to the end of each experi-

mental period (Table 1). There was no detectable beta carotene in the experimental diets but the pre-experimental hay used in Experiments 2 and 3 had 16.3 mg/kg.

In Experiment 2, six deficient diet birds, one prestudy bird, and four control birds died. The prestudy bird was a male that had been attacked repeatedly by other birds. It had bruising, feather loss, and poor body condition. One deficient diet male mallard, found dead on day 33 presumably drowned after being caught in the floating water heater. From 22 to 30 December 1992 (day 49 to 57), four deficient diet and four control birds died. Several birds had linear hyperkeratosis of the distal esophagus associated with a superficial infection by *Candida* sp. and no other specific findings. *Staphylococcus aureus* was isolated from two birds but the cause of death in all birds appeared to be exposure, as frostbite was the most common lesion observed and only commensal organisms were isolated. Not all birds were able to remain in the warmer water during the extremely cold weather (−30 to −38 C plus windchill); subsequently all birds were moved indoors until temperatures returned to −10 to −25 C. One deficient diet bird and two control birds were euthanized by carbon dioxide asphyxiation on 11 January 1993 (Day 69) because of frostbitten extremities suffered during the cold weather. Unexpected mortality also occurred in Experiment 3 during the cold weather when two deficient diet group

TABLE 2. Hepatic retinyl palmitate ( $\mu\text{g/g}$  liver) and retinol ( $\mu\text{g/g}$  liver) levels in mallard ducks sampled in Experiment 1, September 1991 to December 1991 ( $n = 6$  ducks/group).

Day	Group	Hepatic retinyl palmitate			Hepatic retinol		
		Median	Range	$P^a$	Median	Range	$P^a$
0	Prestudy	567	366–1,267		3.75	3.42–5.13	
21	Deficient diet	637	384–759	0.20	3.19	1.07–6.76	0.14
	Control	739	282–976		5.56	1.92–14.10	
42	Deficient diet	591	216–937	0.055 <sup>b</sup>	4.37	1.41–6.07	0.80
	Control	925	629–1,034		3.98	1.94–6.95	
63	Deficient diet	494	16–911	0.52	4.08	0.00–5.61	0.33
	Control	545	310–1,051		4.43	2.23–12.84	
84	Deficient diet	437	207–725	0.0065 <sup>c</sup>	2.75	1.11–7.75	0.034 <sup>c</sup>
	Control	914	636–1,120		7.85	4.89–18.62	

<sup>a</sup> Probability of deficient and control groups on that day being from the same population using the median test.

<sup>b</sup> Borderline significance, parametric analysis of variance  $P = 0.025$ .

<sup>c</sup> Significant differences between the control and deficient diet groups on this day.

birds died. One additional bird from the deficient diet group in Experiment 2 died on day 25 from an undetermined cause. There was no significant difference in HRPT levels among birds on similar diets found dead and those killed because of frostbite and randomly sampled birds in either experiment ( $P = 0.56$ ); however, the birds found dead had significantly lower observed body score ( $P = 0.0003$ ), and standardized body score ( $P = 0.0004$ ). The birds that died unexpectedly and those that were euthanized were included in the analysis of the data set as a December and January sample when evaluating HRPT and HROL, but not body weight, observed body score, standardized body score or organ weights. Because blood was not obtained from birds that died unexpectedly, only euthanized birds were included in the December and January evaluation of SROL.

When evaluating possible differences between sexes, control and deficient diet groups were analyzed separately. Controlling for diet group, there was no difference detected between males and females in Experiment 2 in standardized body score (deficient diet,  $P = 0.39$ ; control,  $P = 0.21$ ), observed body score (deficient diet,  $P = 0.44$ ; control,  $P = 0.53$ ), HRPT (deficient diet,  $P = 0.26$ ; control,  $P$

$= 0.43$ ) or SROL (deficient diet,  $P = 0.29$ ; control,  $P = 0.075$ ). Even though the sample size was small, we do not believe that these probabilities warrant stratification of males and females and have chosen to evaluate them as one population.

The levels of HRPT in ducks in Experiment 1 ranged from 16 to 1,267  $\mu\text{g/g}$  liver (Table 2) while levels of HRPT in ducks in Experiment 2 ranged from non-detectable to 134.5  $\mu\text{g}$  HRPT/g (Table 3). Birds in Experiment 3 had HRPT that ranged from 32 to 1,222  $\mu\text{g/g}$ . The sample sizes in Experiment 3 were too small to compare statistically but the levels of HRPT were comparable to those of birds in Experiment 1 (results not shown).

Hepatic retinyl palmitate and HROL levels of the deficient diet group on day 84 in Experiment 1 were significantly lower than those of the control group (HRPT,  $P = 0.0065$ ; HROL,  $P = 0.025$ ), while levels of HRPT and HROL of the deficient diet group for each sample day in Experiment 2 were significantly lower than those of the corresponding control group (HRPT,  $P$  ranges from  $<0.0001$  to 0.021; HROL,  $P < 0.0001$  to 0.014). The SROL levels in Experiment 1 did not vary between groups (Table 4) (smallest  $P = 0.15$ ) but in Experiment 2 the SROL levels in the deficient diet group were significantly lower



TABLE 3. Hepatic retinyl palmitate ( $\mu\text{g/g}$  liver) and retinol ( $\mu\text{g/g}$  liver) in mallard ducks in Experiment 2, November 1992 to April 1993.

Day	Diet	Birds sampled	Hepatic retinyl palmitate			Hepatic retinol		
			Median	Range	$P^*$	Median	Range	$P^*$
0 <sup>b</sup>	Prestudy	10 (4) <sup>c</sup>	11.5	0.9–134.5		0.3	0.1–1.0	
50 to 69 <sup>d</sup>	Deficient diet	7 (1)	0	0–1.7	0.0037 <sup>e</sup>	0	0–0.1	0.0050 <sup>e</sup>
	Control	6 (3)	12.7	7.4–18.2		0.7	0.5–0.8	
91	Deficient diet	4 (3)	0	0–0.8	0.013 <sup>e</sup>	0.8	0–0.1	0.013 <sup>e</sup>
	Control	5 (2)	21.3	5.9–28.8		1.0	0.4–1.4	
119	Deficient diet	5 (2)	0	0–0	0.0053 <sup>e</sup>	0	0–0	0.0069 <sup>e</sup>
	Control	5 (2)	10.35	6.6–25.5		0.4	0.2–1.1	
153	Deficient diet	4 (1)	0.73	0.6–2.4	0.021 <sup>e</sup>	0	0–0	0.014 <sup>e</sup>
	Control	4 (0)	12.4	6.5–29.8		0.7	0.4–1.3	

\* Probability of deficient and control diet groups in that month being from the same population using the median test.

<sup>b</sup> One bird found dead one day prior to study day zero has been included.

<sup>c</sup> Total birds evaluated (number of males).

<sup>d</sup> For d 50 to 69 sample, nine birds died and two were euthanized because of frozen feet.

<sup>e</sup> Total birds evaluated (number of males).

than the control group on all sample days except the December and January sample ( $n = 3$ ) ( $P = 0.21$ , December and January; remaining days  $P \leq 0.021$ ) (Table 5).

Levels of HRPT had good to moderate correlation with levels of HROL (Experiment 1,  $r = 0.65$ ; Experiments 2 and 3,  $r = 0.81$ ). Serum retinol levels were maintained until HRPT levels were very low (Fig. 2). The relationship of SROL levels to HRPT was curvilinear. The correlation coefficient of the natural log of SROL and the natural log of (HRPT + 0.5) was 0.80.

Squamous metaplasia was not detected

in any control birds or in the deficient diet ducks from Experiment 1 or Experiment 3. In Experiment 2, of the deficient diet group, five of seven mallards had squamous metaplasia in the esophagus after 2 mo, three of five after 3 mo, four of five after 4 mo and 3 of 4 after 5 mo. Lesions ranged from mildly affected glands with metaplasia, to glands that were dilated with keratin, bacteria, and cellular debris. Mallards fed the deficient diet in Experiment 2 developed lesions primarily in the cranial esophagus, with a lower occurrence caudally and even lower centrally (Fig. 3).

TABLE 4. Mean and standard deviation for body measurements and serum retinol of ducks fed either a deficient or control diet in Experiment 1, January to April 1992 ( $n = 6$  for each sample).

Day	Group	Body weight (g)	Liver weight (g)	Head-beak length (mm)	Keel length (mm)	Serum retinol ( $\mu\text{g/l}$ )
0	Prestudy	1,033 $\pm$ 79	25.6 $\pm$ 4.1	NA <sup>a</sup>	107 $\pm$ 6	874 $\pm$ 213
21	Deficient diet	1,257 $\pm$ 72	27.5 $\pm$ 2.8	116 $\pm$ 4	111 $\pm$ 4	1,000 $\pm$ 194
	Control	1,219 $\pm$ 128	24.7 $\pm$ 3.6	113 $\pm$ 3	109 $\pm$ 2	982 $\pm$ 186
42	Deficient diet	1,176 $\pm$ 150	17.0 $\pm$ 2.9	113 $\pm$ 4	107 $\pm$ 5	828 $\pm$ 126
	Control	1,160 $\pm$ 113	16.8 $\pm$ 2.0	112 $\pm$ 2	107 $\pm$ 4	848 $\pm$ 219
63	Deficient diet	1,193 $\pm$ 150	16.4 $\pm$ 2.8	113 $\pm$ 4	104 $\pm$ 3	789 $\pm$ 247
	Control	1,200 $\pm$ 94	14.3 $\pm$ 1.7	113 $\pm$ 5	108 $\pm$ 7	967 $\pm$ 173
84	Deficient diet	1,149 $\pm$ 104	15.7 $\pm$ 1.4	112 $\pm$ 2	107 $\pm$ 3	857 $\pm$ 71
	Control	1,308 $\pm$ 83	16.7 $\pm$ 0.2	113 $\pm$ 3	108 $\pm$ 4	911 $\pm$ 70

<sup>a</sup> Data not available.



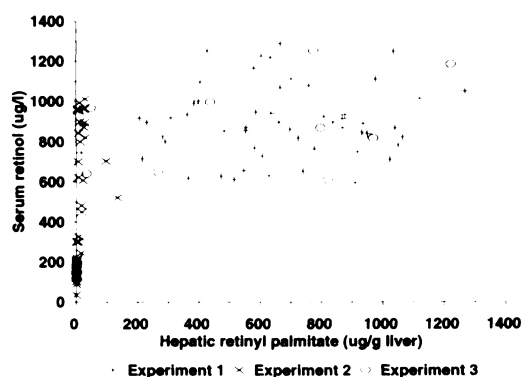


FIGURE 2. Relationship between serum retinol and hepatic retinyl palmitate levels in mallard ducks from all three experiments ( $n = 97$ ).

Squamous metaplasia of the palatine salivary glands was rare and only occurred in birds that had lesions in all three sections of the esophagus. No lesions were detected in the trachea or ureter of any bird. Metaplastic changes of esophageal mucosal glands were more common than keratotic changes and keratotic changes were seen only in birds that had squamous metaplasia in the same section. Lesions were detected grossly only in those birds with a high degree of keratosis. The level of HRPT was less than  $2 \mu\text{g/g}$  in all but one bird with esophageal lesions, but four (29%) of 14 ducks with no detectable HRPT levels had no lesions (Table 6). There was no

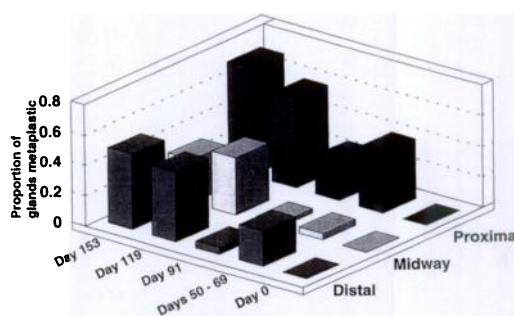


FIGURE 3. Distribution and intensity of metaplastic esophageal lesions observed in deficient mallards in Experiment 1.

correlation between SROL level and histological lesions.

Correlations were performed to determine if there was a relationship of non-invasive measurements to vitamin A levels. There was poor to moderate linear correlation between HRPT and body weight (Experiment 1,  $r = 0.28$ ; Experiment 2,  $r = 0.53$ ), standardized body score (Experiment 1,  $r = 0.15$ ; Experiment 2,  $r = 0.31$ ), liver weight (Experiment 1,  $r = 0.007$ ; Experiment 2,  $r = -0.26$ ), kidney weight (Experiment 1,  $r = 0.11$ ; Experiment 2,  $r = -0.19$ ) or observed body score (Experiment 2,  $r = 0.071$ ). There was no apparent relationship between liver vitamin A concentration and standardized body score (results not shown).

TABLE 5. Mean and standard deviation of body measurements in mallard ducks in Experiment 2, November 1992 to April 1993.

Day	Diet	Birds sampled	Body weight (g)	Liver weight (g)	Head-beak length (mm)	Keel length (mm)	Serum retinol ( $\mu\text{g/l}$ )
0	Prestudy	10	$1,119 \pm 191$	$18.0 \pm 3.4$	$112 \pm 4$	$104 \pm 5$	$391 \pm 218$
	Deficient diet	7	$885 \pm 150$	$25.1 \pm 6.2$	$109 \pm 4$	$95 \pm 6$	35 <sup>a</sup>
50 to 69	Control	6	$887 \pm 154$	$27.7 \pm 10.0$	$112 \pm 4$	$99 \pm 11$	$389 \pm 62^b$
	Deficient diet	4	$1,037 \pm 63$	$18.2 \pm 3.3$	$111 \pm 7$	$103 \pm 7$	$208 \pm 69$
91	Control	5	$1,060 \pm 84$	$18.8 \pm 3.4$	$112 \pm 5$	$103 \pm 6$	$849 \pm 132$
	Deficient diet	5	$960 \pm 121$	$17.8 \pm 5.2$	$112 \pm 5$	$99 \pm 9$	$127 \pm 32$
119	Control	5	$1,074 \pm 70$	$20.6 \pm 2.2$	$113 \pm 4$	$106 \pm 3$	$811 \pm 138$
	Deficient diet	4	$1,040 \pm 93$	$22.5 \pm 3.8$	$111 \pm 5$	$101 \pm 3$	$161 \pm 14$
153	Control	4	$1,016 \pm 18$	$16.1 \pm 0.7$	$110 \pm 1$	$101 \pm 2$	$967 \pm 50$

<sup>a</sup> Based on a sample of one bird.

<sup>b</sup> Based on a sample of two birds.

There was significantly ( $P = 0.015$ ) lower body weight in the deficient diet group as compared with the control on day 84 of Experiment 1 (Table 4). There was a significant weight gain in ducks in Experiment 1 ( $P = 0.0081$ ) but there was no difference between the two diet groups. There was no significant difference in body weight of birds in Experiment 2 when the December and January sample was removed (Table 5). Body condition scores and standardized body scores followed the same pattern. In Experiment 2, there was a significant difference between diet groups in kidney weight (results not shown) in March ( $P = 0.013$ ) and liver weight in April ( $P = 0.016$ ) (Table 5). The liver and kidney weights of birds in Experiment 1 were significantly ( $P = 0.04$ ) greater on days 0 and 21 than on days 42, 63 and 84. This change in mean organ weights did not parallel the changes seen in body weight. In Experiment 2, the mean liver weight of the December and January sample was significantly higher than that of all the other sampling days ( $P = 0.04$ ). This higher liver weight corresponded with a decrease in body weight for the same December and January sample (Table 5).

#### DISCUSSION

Mortality among the deficient diet group in Experiment 3 was greater than in the control group. Because of lack of significance found in Experiment 2 and the small sample size in Experiment 3, the higher mortality seen in the deficient diet group in Experiment 2 was not believed to be an effect of diet.

Commercially available domestic duck rations typically are formulated with 8,800 IU vitamin A/kg feed. The control diet was formulated with 4,000 IU vitamin A/kg of feed based on National Research Council recommendations (Scott and Dean, 1991). The levels of vitamin A in the control diets decreased by half over the course of these experiments. The difference in vitamin A content in diets appeared to have contributed to the difference in HROL,

TABLE 6. Two by two table comparing the frequency of occurrence of histological lesions to levels of hepatic retinyl palmitate (HRPT) greater than or less than 2  $\mu\text{g}$  HRPT/g of liver. Data from all three experiments included.

	<2 $\mu\text{g}$ HRPT/g liver	$\geq 2 \mu\text{g}$ HRPT/g liver	Total
Histological lesion present	15	1	16
No lesion present	5	95	100
Total	20	96	116

HRPT, and SROL levels found between diet groups. The mean vitamin A content of the liver of control birds from all three experiments did not decrease significantly throughout the course of the study; thus, the vitamin A content of the control diet (1,780 to 4,040 IU/kg) probably was sufficient for maintaining vitamin A stores. The failure of levels of HRPT to significantly increase even in birds with low levels, such as those in Experiment 2, is evidence that the control diet had no excess of vitamin A for repletion of storage levels. Although ducks on deficient diets in Experiment 2 and on day 84 of Experiment 1 were significantly different from controls in HRPT, HROL and SROL, there was no evidence of a steady decline in these vitamin A levels. We believe that the absence of a temporal trend could be due to a combination of great variation in vitamin A stores among individuals in our study, and small sample sizes that may mask small changes at low concentrations.

None of the birds in Experiments 1 or 3 developed lesions associated with vitamin A deficiency, and HRPT levels remained above levels considered deficient in these birds. These groups of mallards were fed a diet high in vitamin A prior to the study; thus the storage level of vitamin A present in the liver prior to winter may be very important in determining the ability of an individual to maintain HRPT levels over winter on a diet deficient in vitamin A. Based on Experiments 1 and 3, hepatic stores of approximately 600  $\mu\text{g}$

HRPT/g or greater in autumn may be sufficient for overwintering mallards feeding on all grain diets for 5 mo. Because birds in Experiment 3 had levels of HRPT and HROL similar to the birds in Experiment 1, changes in housing environment probably were not the major factor causing birds in Experiment 2 to become deficient. This was further supported by the fact that Experiment 2 birds (day 0) had low levels of HRPT prior to being fed the trial diet, while levels at the start of Experiments 1 and 3 were higher. One bird on day 0 of Experiment 2, had an HRPT level of 0.9  $\mu\text{g/g}$  liver. This bird was not abnormal in any of the other measurements and was considered to be part of the population. Thus we inferred that the prestudy diet in Experiment 2 could be deficient in vitamin A, possibly due to failure to feed on hay that contained beta carotene. The ducks were fed the prestudy diet from 15 September to 3 November 1992 (46 days) and before that had access to a more natural diet. It was difficult to determine the time required for mallards to become deficient when feeding solely on grain, as this will depend on the vitamin A stores of individual ducks which in turn will depend on food preferences and availability.

Jungherr (1943) reported lesions of squamous metaplasia of the esophagus in chicks fed suboptimal levels of vitamin A for 4 to 6 wk. He measured total vitamin A liver levels and compared these to the occurrence of lesions. The results were similar to ours in that some chicks with low levels of hepatic vitamin A did not have lesions, while some individuals with higher levels of hepatic vitamin A had lesions. He also found that lesions of the nasal cavity became apparent in chickens with vitamin A levels of 30 to 50 IU/g liver. We did not detect lesions in the nasal cavity of any of the ducks. Chickens with severe morphologic lesions had less than 15 IU vitamin A/g liver (Jungherr, 1943). Lesions occurred in our experimental ducks with hepatic vitamin A concentrations of less than 1.3  $\mu\text{g}$  vitamin A/g liver (0.44 IU

vitamin A/g liver). Friedman et al. (1991) found that chicks "depleted" of vitamin A, yet having had no lesions associated with vitamin A deficiency, had 7  $\mu\text{g}$  vitamin A/g (2.3 IU/g) liver; chicks that were "sufficient" had 48  $\mu\text{g}$  vitamin A/g (16 IU/g) liver, and chicks with "excess" vitamin A had 750  $\mu\text{g}$  vitamin A/g (250 IU/g) liver.

We defined a deficient state in mallards as a bird with  $<2 \mu\text{g}$  HRPT/g liver because this was the level at which a significant proportion of birds had squamous metaplasia in the esophagus. Determining the level of vitamin A that represents a deficient state in a species is difficult, as subtle pathophysiological changes may not be obvious to the investigator. Consequently, the level we considered deficient may have been too low. We did not attempt to determine the level of vitamin A required in mallards to prevent pathophysiological changes to the immune or reproductive systems. Sijtsma et al. (1990) used the point at which serum vitamin A has fallen to half the normal levels to define deficiency. It would be ideal to define deficiency as a level of liver vitamin A at which serum levels can no longer be maintained. Neither of these points can be determined from our data, because of small sample size and individual variation; however, in our experiments, SROL levels did not decline until there was a very low level of HRPT.

Serum retinol below 300  $\mu\text{g/l}$  was predictive of less than 2  $\mu\text{g}$  HRPT/g liver in mallards. With data from all three experiments, SROL  $<300 \mu\text{g/l}$  had a positive predictive value of 81%, negative predictive value of 99%, accuracy of 96%, sensitivity of 92% and a specificity of 96% (Smith, 1991). Thus, serum retinol was a good screening and diagnostic test for vitamin A deficiency at a level of 2  $\mu\text{g}$  HRPT/g liver but, as previously discussed, this definition of vitamin A deficiency may be too conservative.

We recognize the problem in comparing the occurrence of histological lesions to levels of HRPT  $<$  or  $\geq 2 \mu\text{g/g}$  liver because this definition of deficiency ( $<2$

μg/g) was determined by comparing the occurrence of histological lesions to it (Table 6). Admitting this weakness, the high degree of specificity (99%) of the histological evaluation of the esophagus makes it a good diagnostic test; however, based on its moderate degree of sensitivity (75%) (Smith, 1991), we believe that histopathology was a poor screening test at these conservative levels (<2 μg HRPT/g liver) of deficiency. The progression of lesions in the esophagus is evidence that the most sensitive section to evaluate would be the very cranial portion of the esophagus. Since squamous metaplasia was not always visible grossly, histological evaluation was required. Lesions of keratinization were found only in ducks with no measurable hepatic vitamin A.

The change in liver weight that occurred in Experiment 1, without an effect seen between diets nor a similar direction of change in body weights, may have altered the levels of vitamin A concentration per gram of liver. If liver weight decreased while vitamin A content remained constant, the net effect would have been an increase in vitamin A concentration. In Experiment 2, the liver weight of the ducks from the December and January sample comprised a greater proportion of the standardized body score of the ducks. These birds were the individuals with large livers compared to their Standardized Body Score and low vitamin A concentration. This change in liver weight probably was due to fat mobilization during the stress of the cold period. A large liver due to fat infiltration would tend to reduce vitamin A levels/g of liver. We could not determine whether the low concentration of vitamin A was due to a change in liver size or to decreased vitamin A intake, but doubling of liver weight would only halve the vitamin A concentration, therefore, liver weight should not be a major confounder and we believe that conclusions based on hepatic vitamin A concentration still are valid.

None of the non-invasive measures

(weight or condition indices) correlated well with the vitamin A status of captive mallards. Based on the results from these trials with captive mallards, ducks in good bodily condition will not necessarily have sufficient vitamin A stores.

#### ACKNOWLEDGMENTS

Special thanks to Kim Williams for performing the vitamin A analysis, Doug Yungblut, and Jorge Castillo from Hoffmann-La Roche for arranging the evaluation of the vitamin content of the feed, and to Luella Bartsch and Lynn Bernges for their histology specimen preparation.

#### LITERATURE CITED

- ASSOCIATION OF OFFICIAL ANALYTICAL CHEMISTS. 1990. Carotenes and Xanthophylls in dried plant materials and mixed feeds Section 970.64. In Official methods of analysis, 15th ed. Association of Official Analytical Chemists, Washington, D.C., pp. 1048.
- BANG, F. B., B. G. BANG, AND M. FOARD. 1975. Acute Newcastle disease virus infections of the upper respiratory tract of the Chicken, II. The effect of diets deficient in vitamin A on the pathogenesis of the infection. American Journal of Pathology 78: 417-424.
- BELLROSE, F. C. 1976. Mallard. In Ducks, geese and swans of North America. Stackpole Books, Harrisburg, Pennsylvania, pp. 229-243.
- CARTER, G. R., AND J. R. COLE. 1990. Diagnostic procedures in veterinary bacteriology and mycology, 5th ed. Academic Press Incorporated, San Diego, California, 620 pp.
- CLARK, R. G., AND L. G. SUGDEN. 1990. The importance of agricultural foods in the annual diet of mallard (*Anas platyrhynchos* L.) and sandhill crane (*Grus canadensis* L.). In Granivorous birds in the agricultural landscape, J. Pinowski and J. D. Sumner-Smith (eds.). Intercol, Warszawa, Poland, pp. 317-331.
- DELEENHEER, A. P., AND H. J. NELIS. 1990. High-performance liquid chromatography of retinoids in blood. Methods in Enzymology 189: 50-59.
- FRIEDMAN, A., A. MEIDOVSKY, G. LEITNER, AND D. SKLAN. 1991. Decreased resistance and immune response to *Escherichia coli* infection in chicks with low or high intakes of vitamin A. Journal of Nutrition 121: 395-400.
- HAGAR, J. A. 1950. Black duck mortality in the Parker River region, winter of 1949-50. Massachusetts Division of Fisheries and Game, Amherst, Massachusetts, pp. 17.
- JORDE, D. G., G. L. KRAPU, AND R. D. CRAWFORD. 1983. Feeding ecology of mallards wintering in

- Nebraska. The Journal of Wildlife Management 47: 1044-1053.
- JUNGHER, E. 1943. Nasal histopathology and liver storage in subtotal vitamin A deficiency of chickens. Bulletin Number 250, University of Connecticut, University of Connecticut Press, Storrs, Connecticut, 36 pp.
- LOESCH, C. R., AND R. M. KAMINSKI. 1989. Winter body-weight patterns of female mallards fed agricultural seeds. The Journal of Wildlife Management 53: 1081-1087.
- NAUSS, K. M. 1984. Influence of vitamin A status on the immune system. In Vitamin A deficiency and its control, J. C. Bauernfeind (ed.). Academic Press, Inc., New York, New York, pp. 208-243.
- OLSON, J. A. 1979. A simple dual assay for vitamin A and carotenoids in human liver. Nutrition Reports International 19: 807-813.
- SCHOEFF, L. 1983. Vitamin A. American Journal of Medical Technology 49: 447-452.
- SCOTT, M. L., AND W. F. DEAN. 1991. Vitamin allowances for ducks. In Nutrition and management of ducks. M. L. Scott (publ.), Ithaca, New York, 177 pp.
- SHAPIRO, S. S., AND M. B. WILK. 1965. An analysis of variance test for normality (complete samples). Biometrika 52: 591-611.
- SIJTSMA, S. R., J. H. W. M. ROMBOUT, C. E. WEST, AND A. J. VANDER ZIJPP. 1990. Vitamin A deficiency impairs cytotoxic T lymphocyte activity in Newcastle disease virus-infected chickens. Veterinary Immunology and Immunopathology 26: 191-201.
- SMITH, R. D. 1991. Evaluation of diagnostic test. In Veterinary clinical epidemiology, a problem-oriented approach. Butterworth-Heinemann, Stoneham, Massachusetts, pp. 29-44.
- TENDERDY, R. P., N. G. LACETERA, AND C. F. NOCKELS. 1990. Effect of beta carotene on disease protection and humoral immunity in chickens. Avian Diseases 34: 848-854.
- WOBESER, G., AND W. KOST. 1991. Starvation, staphylococcosis and vitamin A deficiency among mallards overwintering in Saskatchewan. Journal of Wildlife Diseases 28: 215-222.
- ZAR, J. H. 1984. Biostatistical analysis, 2nd ed. Prentice Hall, Englewood Cliffs, New Jersey, 718 pp.

*Received for publication 11 January 1994.*