

## **EXPERIMENTAL INFECTIONS OF SARCOCYSTIS SPP. IN ROCKY MOUNTAIN ELK (CERVUS ELAPHUS) CALVES**

Authors: Foreyt, William J., Baldwin, Thomas J., and Lagerquist, John E.

Source: Journal of Wildlife Diseases, 31(4) : 462-466

Published By: Wildlife Disease Association

URL: <https://doi.org/10.7589/0090-3558-31.4.462>

---

The BioOne Digital Library (<https://bioone.org/>) provides worldwide distribution for more than 580 journals and eBooks from BioOne's community of over 150 nonprofit societies, research institutions, and university presses in the biological, ecological, and environmental sciences. The BioOne Digital Library encompasses the flagship aggregation BioOne Complete (<https://bioone.org/subscribe>), the BioOne Complete Archive (<https://bioone.org/archive>), and the BioOne eBooks program offerings ESA eBook Collection (<https://bioone.org/esa-ebooks>) and CSIRO Publishing BioSelect Collection (<https://bioone.org/csiro-ebooks>).

Your use of this PDF, the BioOne Digital Library, and all posted and associated content indicates your acceptance of BioOne's Terms of Use, available at [www.bioone.org/terms-of-use](http://www.bioone.org/terms-of-use).

Usage of BioOne Digital Library content is strictly limited to personal, educational, and non-commercial use. Commercial inquiries or rights and permissions requests should be directed to the individual publisher as copyright holder.

---

BioOne is an innovative nonprofit that sees sustainable scholarly publishing as an inherently collaborative enterprise connecting authors, nonprofit publishers, academic institutions, research libraries, and research funders in the common goal of maximizing access to critical research.

## EXPERIMENTAL INFECTIONS OF *SARCOCYSTIS* SPP. IN ROCKY MOUNTAIN ELK (*CERVUS ELAPHUS*) CALVES

William J. Foreyt, Thomas J. Baldwin, and John E. Lagerquist

Department of Veterinary Microbiology and Pathology, Washington State University,  
Pullman, Washington 99164, USA

Correspondence to: Dr. W. J. Foreyt, Department of Veterinary Microbiology and Pathology,  
Washington State University, Pullman, Washington 99164-7040

**ABSTRACT:** Four 4-mo-old elk calves (*Cervus elaphus*) obtained from northeastern Oregon (USA) each were inoculated orally with 250,000 sporocysts of *Sarcocystis* spp., including *S. sybillensis* and *S. wapiti*. Three similar elk calves of comparable ages and weights served as uninoculated controls maintained with the inoculated elk during the experimental period between September and December 1993. Body weights were evaluated at 0 and 90 days postinoculation (PI); packed cell volumes of whole blood were evaluated at 0, 30, and 60 days PI, and numbers of sarcocysts in histologic sections from 11 selected tissues were evaluated at 90 days PI. Significant differences in blood packed cell volumes were not detected between groups ( $P > 0.05$ ). Except for weight gain, elk remained healthy. Mean ( $\pm$  SE) weight gain of inoculated elk ( $27.1 \pm 1.6$  kg) was significantly ( $P < 0.05$ ) less than that of controls ( $40.2 \pm 4.9$  kg). Mean ( $\pm$  SE) number of sarcocysts in tissues of inoculated ( $114.4 \pm 25.7$  cm<sup>2</sup>) and controls ( $4.5 \pm 1.4$  cm<sup>2</sup>) differed significantly ( $P < 0.05$ ). Heart, esophagus and skeletal muscle contained the most sarcocysts. No sarcocysts were detected in brain, spinal cord, or testicles. Histologically, mononuclear myositis and myocarditis, with numerous intralesional sarcocysts were seen. Less severe, but widespread inflammation occurred in brain, spinal cord, and optic nerve. Mortality and anemia were not seen, but weight gain depression was detected in the inoculated elk over the 90 day experimental period.

**Key words:** *Sarcocystis wapiti*, *S. sybillensis*, *Sarcocystis* spp., elk, *Cervus elaphus*, pathogenicity, experimental infection.

### INTRODUCTION

*Sarcocystis* spp. are apicomplexan protozoa that typically have a two host life cycle; the sarcocyst stage is commonly in muscles of herbivore intermediate hosts, and the oocyst stage is in the small intestine of carnivore definitive hosts; oocysts or sporocysts are passed in the feces. Nearly 100% of the Rocky Mountain elk (*Cervus elaphus*) in the northwestern United States have *Sarcocystis* spp. in skeletal and cardiac muscle (Lagerquist and Foreyt, 1993). At least two species of *Sarcocystis* (*S. wapiti* and *S. sybillensis*) occur in elk in North America (Dubey et al., 1989).

Among cattle, *Sarcocystis cruzi* is a recognized pathogen and causes anemia, myositis and death (Foreyt, 1986; Dubey et al., 1989). However, the effects of *Sarcocystis* spp. infection in elk essentially are unknown. Our objective was to determine the effects of experimentally induced *Sarcocystis* spp. infections in elk.

### MATERIALS AND METHODS

Seven Rocky Mountain elk calves, six males and one female, were used between September and December 1993. Five 3 to 12-days-old males were obtained from the U.S. Forest Service, La Grande, Oregon (USA) (45°35'N, 118°10'W), a male calf < 7-days-old was obtained from the Washington Department of Fish and Wildlife near Wenatchee, Washington (USA) (47°25'N, 120°35'W), and one 14-day-old female calf was obtained from a zoo in Spokane, Washington (47°40'N, 117°40'W) during June and July 1993. In July 1993, all seven calves were moved from a private rearing facility to Washington State University, Pullman, Washington, and housed in an indoor and outdoor facility with a concrete floor. Ad libitum alfalfa hay, alfalfa pellets, mineralized salt and water were provided, and straw for bedding was placed in the indoor area. Calves were bottle-raised on commercial milk replacer (Merrick's Kid Replacer, Middleton, Wisconsin, USA) until released into a 2 ha pasture at 2 mo of age.

Weaned elk calves were approximately 4 mo old and clinically healthy at the initiation of this experiment. A fecal sample for parasitology was obtained from the rectum of each elk and ex-

amined by a sugar flotation technique (specific gravity of 1.27) as modified by Foreyt (1994), and the Baermann technique (Foreyt, 1994).

Approximately 15 kg of skeletal muscles from a 2-yr-old male elk that had been maintained in captivity at WSU and euthanized with a shot to the head from a high powered rifle, was fed to five mixed-breed domestic dogs. Additional pieces of skeletal and cardiac muscles were fixed in 10% neutral buffered formalin, embedded in paraffin, sectioned at 5  $\mu$ m, stained with hematoxylin and eosin, and evaluated histologically for sarcocysts. Additional muscle specimens were prepared for electron microscopy by the methods of Foreyt (1989), and viewed using a transmission electron microscope (Hitachi H600, Hitachi, Santa Clara, California, USA). Feces from each dog were collected before the dogs first were fed elk meat; no oocysts or sporocysts were detected. Feces were collected daily for 21 days after feeding the meat, and evaluated for oocysts with a sugar fecal flotation technique (specific gravity of 1.27) as modified by Foreyt (1994). Briefly, oocysts and sporocysts were separated from feces by mixing feces with tap water and filtered sequentially through two sieves with openings of 500 and 250  $\mu$ m, respectively. Oocysts and sporocysts were concentrated by placing the fecal filtrate in 800 ml glass beakers, allowing contents to settle for at least 1 hr, decanting two-thirds of the supernatant and replacing the supernatant with fresh tap water. This procedure was repeated six times until the supernatant was clear. Number of sporocysts per ml of solution was determined by thoroughly mixing the solution and evaluating five separate 1-ml aliquots using Foreyt's (1994) fecal flotation technique.

All elk calves were 15-wk-old, except number 4 (11-wk-old) on the day of inoculation. The elk were divided into two treatment groups; four elk (numbers 1, 3, 5 and 7) each received approximately 250,000 sporocysts administered orally using a dosing syringe, and three elk (numbers 2, 4 and 6) were uninoculated controls. All elk were maintained on the same pasture, and were observed daily for signs of disease. On days 0, 30, 60, and 90, all elk were immobilized with approximately 50 mg of xylazine (Mobay Corporation, Shawnee, Kansas, USA) administered intramuscularly, weighed on a livestock scale (Adrian J. Paul Co., Inc., Duncan, Oklahoma, USA); 3 ml of blood then were collected from the jugular vein with a 10 cc syringe and 18 ga needle, and placed in a 10 ml Vacutainer (Becton Dickinson, Rutherford, New Jersey, USA) tube containing sodium heparin. Approximately 40  $\mu$ l of blood was drawn into a microhematocrit capillary tube, centrifuged at 11,500 rpm for two min, and the packed

cell volume (PCV) determined using a hematocrit tube reader (International Equipment Company, Boston, Massachusetts, USA). Immobilized elk were given 10 mg of yohimbine hydrochloride (Antagonil, Wildlife Laboratories, Fort Collins, Colorado, USA) intravenously to reverse the effects of xylazine. On experimental day 90, elk were euthanized with a shot to the neck from a high powered rifle. At necropsy, the following tissues were collected and placed in 10% neutral buffered formalin: deltoid, gluteus, and psoas muscles, esophagus, heart, tongue, muscular diaphragm, brain, spinal cord, eye, and testicle ( $n = 6$  males). Tissues were prepared for histology and electron microscopy by the methods described. Numbers of sarcocysts were counted in a 1 cm<sup>2</sup> section from each tissue, and tissues were evaluated histopathologically. Cross sections of 100 sarcocysts in skeletal muscles were measured. The sarcocysts were identified by morphology, based on the descriptions of Dubey et al. (1989). Identifications of *Eimeria* spp. oocysts and helminthoera were based on published descriptions of eggs, oocysts, and larvae (Foreyt, 1994). Data were evaluated with the Mann-Whitney rank sum test (Ott, 1984).

## RESULTS

Based on morphology, sarcocysts originally fed to the dogs were morphologically compatible with *S. sybillensis* and *S. wapiti*. Oocysts and sporocysts were detected in four of five dogs 11 days after ingesting infected meat, indicating a prepatent period of 11 days. No diarrhea or depression was observed in the dogs.

All elk survived the 90-day experiment and were clinically healthy throughout the experiment. At the initiation of the experiment, the following parasite eggs and oocysts were detected in low numbers (< 30 per gram of feces) by fecal examination: *Trichuris* sp. ( $n = 4$  positive), *Capillaria* sp. ( $n = 5$  positive), and *Eimeria* spp. (all positive). Lungworm larvae were not detected. Neither mean ( $\pm$  SE) weights nor PCVs of inoculated elk differed significantly ( $P > 0.05$ ) from those of control elk throughout the experiment, but the mean weight gain of inoculated elk ( $27.1 \pm 1.6$  kg) was significantly ( $P < 0.05$ ) less than that of controls ( $40.2 \pm 4.9$  kg) (Table 1). All inoculated elk had significantly ( $P <$

TABLE 1. Summary of total weights (kg), weight gains and packed cell volumes (%) for three non-inoculated elk calves, and four elk calves inoculated with 250,000 sporocysts of *Sarcocystis* spp.

	Total weight		Weight gain		Packed cell volume	
	Inoculated (n = 4)	Controls (n = 3)	Inoculated (n = 4)	Controls (n = 3)	Inoculated (n = 4)	Controls (n = 3)
Day 0	69.9 (52.7-91.4)*	82.7 (64.1-96.4)	NA <sup>b</sup>	NA	35 (30-40)	35 (32-37)
Day 30	ND <sup>c</sup>	ND	NA	NA	32 (30-34)	32 (32-34)
Day 60	ND	ND	NA	NA	30 (32-36)	33 (31-34)
Day 90	97.0 (83.6-118.2)	122.9 (111.8-129.5)	27.1 <sup>d</sup> (23.2-30.9)	40.2 (30.9-47.7)	ND	ND

\* Mean (range).

<sup>b</sup> Not applicable.<sup>c</sup> Not done.<sup>d</sup> Significantly ( $P < 0.05$ ) lower than the group controls.

0.05) more sarcocysts in tissues examined ( $\bar{x} \pm \text{SE} = 114.4 \pm 25.7 \text{ cm}^2$ ) versus non-inoculated elk ( $4.5 \pm 1.4 \text{ cm}^2$ ) (Table 2). Sarcocysts were most numerous in heart, esophagus, and skeletal muscle (Table 2). Sarcocysts were not detected in brain, spinal cord or testicle. Mean ( $\pm \text{SE}$ ) size of 100 *Sarcocystis* spp. sarcocysts in muscle was  $72.3 \pm 5.9 \mu\text{m} \times 32.2 \pm 1.8 \mu\text{m}$ .

By subjective evaluation at necropsy, all elk were in good body condition with adequate amounts of body fat. Gross lesions were not observed, except occasional sarcocysts seen in the myocardium of two inoculated elk. Histologically, sections of heart and skeletal muscles were similar and characterized by mild to moderate mononuclear myositis, rare myofiber degeneration and numerous intrafiber sarcocysts (Fig. 1). Inflammatory cells were prominent around vessels, and rare myofibers were fragmented, pale staining, and had lost striations. Nuclei in degenerate fibers were enlarged and numerous. In one inoculated elk, occasional multinucleate giant cells were among the lymphocytes and histiocytes in the perimysium and endomysium. In the cerebellum, vessels were congested, and often surrounded by or associated with moderate numbers of lymphocytes. Foci of mononuclear leukocyte infiltrates were in the cerebellum and spinal cord. Multifocal, moderate sized infiltrates of lymphocytes and some macrophages were in the epineurium and extended into the optic nerve. In control elk, occasional sarcocysts were observed in cardiac and skeletal muscle. Multifocal perimysial eosinophilic infiltrates were observed in one elk.

Based on electron micrographs of several sarcocysts from skeletal muscle, most sarcocysts were compatible with immature *S. sybillensis* (Fig. 2), with fewer numbers of *S. wapiti*. Immature sarcocysts of *S. sybillensis* had thick walls (1 to 3  $\mu\text{m}$ ), merocyte and protrusions that were branched in the distal segments (Fig. 2). Sarcocysts of *S. wapiti* had thin undulating walls ( $< 1 \mu\text{m}$ ) with stubby projections.

TABLE 2. Mean number of sarcocysts of *Sarcocystis* spp. per cm<sup>2</sup> of tissue from control elk, and elk orally inoculated with 250,000 oocysts 90 days previously.

Tissue	Inoculated elk (n = 4)		Control elk (n = 3)	
	Mean	Range	Mean	Range
Deltoid	147.0*	72–224	2.0	0–6
Gluteus	140.0*	40–266	8.7	2–20
Psoas	143.0*	20–348	6.0	0–16
Esophagus	224.0*	2–640	7.3	0–18
Heart	276.0*	22–718	2.7	0–6
Tongue	157.0	16–396	2.0	0–6
Diaphragm	76.5	30–164	19.3	2–34
Brain	0		0	
Spinal cord	0 <sup>b</sup>		0	
Eye	33.5	0–74	1.3	0–4
Testicle	0 <sup>b</sup>		0	
Grand mean	144.4*	39.5–186.4	4.5	0.5–7.8

\* Significantly higher than the control group ( $P < 0.05$ ).

<sup>b</sup> n = 3.

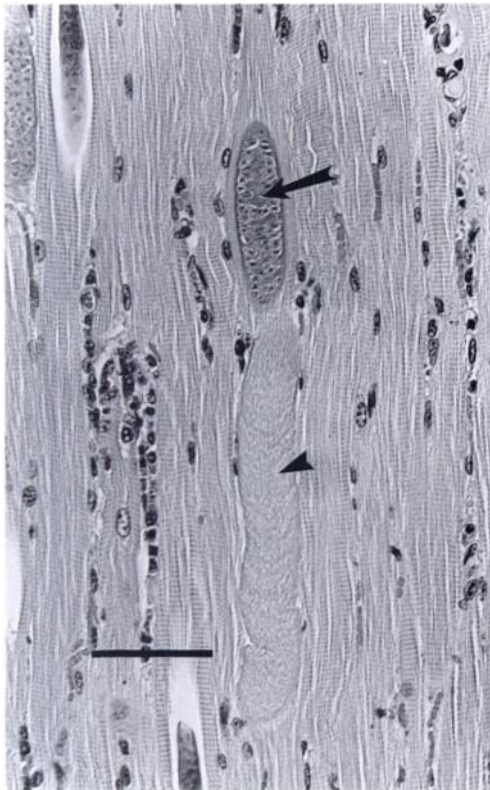


FIGURE 1. *Sarcocystis* sp. cyst (arrow) in muscle of the diaphragm. Scattered lymphocytes have infiltrated the endomysium, and one myofiber is degenerate with loss of striations (arrowhead). H&E stain. Bar = 50 μm.

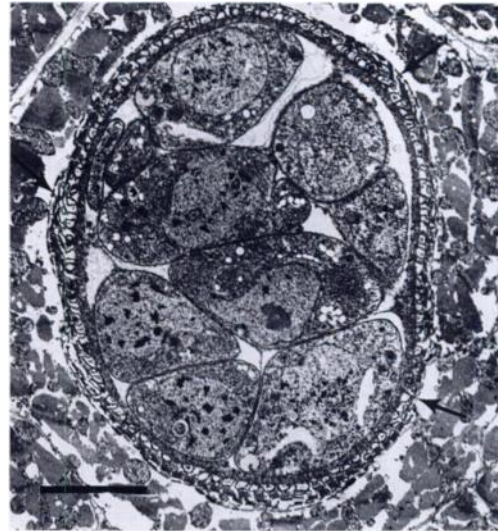


FIGURE 2. Transmission electron micrograph of an immature sarcocyst of *Sarcocystis sybillensis*. Note the thick cyst wall with protrusions and distally branched segments (arrows). Bar = 5 μm.

## DISCUSSION

Oral inoculation of 4-mo-old elk calves with 250,000 sporocysts of *Sarcocystis* spp. resulted in large numbers of sarcocysts in skeletal and cardiac muscle, but did not produce clinical disease as has been described in cattle, sheep, goats, and experimentally infected mule deer (*Odocoileus hemionus*) (Dubey et al., 1989). The only change detected was depressed weight gain.

*Sarcocystis wapiti* has a 10 to 12 day prepatent period (Speer and Dubey, 1982), and *S. sybillensis* has a 14-day prepatent period (Dubey et al., 1983). The oocysts passed at 11 days from four of the five dogs fed the original elk meat likely were *S. wapiti*. Most muscle sarcocysts examined were morphologically compatible with *S. sybillensis* and *S. wapiti*, but other species of *Sarcocystis* may have been in the inoculum, or the recipient elk at the time of inoculation.

Lesions in the tongue, esophagus, and heart were extensive, and may have caused clinical disfunction including poor apprehension of food and swallowing, or myo-

cardial function. Skeletal muscle lesions may have been asymptomatic, but muscle function was not evaluated.

Low numbers of sarcocysts in control elk were evidence of exposure to sporocysts before or after inoculation, or sporocysts that passed through inoculated animals, contaminating the pasture. Given the significant differences between sarcocyst numbers between inoculated and control elk, results likely were unaffected by the few sarcocysts in the noninoculated group. We propose that *Sarcocystis* spp. infections are not an important disease problem in young elk. Additional experimental monospecies infections, different numbers of sporocysts in the inoculum, and inoculation of elk of different ages will further our understanding of this prevalent parasite in elk populations.

#### ACKNOWLEDGMENTS

We thank John Cook and the U.S. Forest Service, Bruce Johnson, Walk in the Wild Zoo, and Washington Department of Wildlife personnel for their cooperation in providing the elk calves for this study. Partial funding for this research was provided by the Rocky Mountain Elk Foundation. The assistance of Kris Foreyt, Annie Foreyt, Russell Foreyt, Tenneille Ludwig and Cara

Shillington in bottle feeding elk calves is greatly appreciated.

#### LITERATURE CITED

- DUBEY, J. P., W. R. JOLLEY, AND E. T. THORNE. 1983. *Sarcocystis sybillensis* sp. nov. from the North American elk (*Cervus elaphus*). Canadian Journal of Zoology 61: 737-742.
- , C. A. SPEER, AND R. FAYER. 1989. Sarcocystosis of animals and man. CRC Press, Inc., Boca Raton, Florida, 215 pp.
- FOREYT, W. J. 1986. Evaluation of decoquinate, lasalocid, and monensin against experimentally induced sarcocystosis in calves. American Journal of Veterinary Research 47: 1674-1676.
- . 1989. *Sarcocystis* sp. in mountain goats (*Oreamnos americanus*) in Washington: Prevalence and search for the definitive host. Journal of Wildlife Diseases 25: 619-622.
- . 1994. Veterinary parasitology reference manual. Washington State University, Pullman, Washington, 178 pp.
- LAGERQUIST, J. E., AND W. J. FOREYT. 1993. Prevalence of *Sarcocystis* in elk (*Cervus elaphus*) in Oregon. Northwest Science 67: 196-198.
- OTT, L. 1984. An introduction to statistical methods and data analysis. Duxbury Press, Boston, Massachusetts, pp. 146-150.
- SPEER, C. A., AND J. P. DUBEY. 1982. *Sarcocystis wapiti* sp. nov. from the North American wapiti (*Cervus elaphus*). Canadian Journal of Zoology 60: 881-888.

Received for publication 7 November 1994.