



## **Myocardial Purkinje Degeneration and Necrosis with Fibrosis in Free-Ranging Black Rhinoceroses (*Diceros bicornis*) in Zimbabwe**

Author: Kock, N. D.

Source: Journal of Wildlife Diseases, 32(2) : 367-369

Published By: Wildlife Disease Association

URL: <https://doi.org/10.7589/0090-3558-32.2.367>

---

BioOne Complete ([complete.BioOne.org](https://complete.BioOne.org)) is a full-text database of 200 subscribed and open-access titles in the biological, ecological, and environmental sciences published by nonprofit societies, associations, museums, institutions, and presses.

Your use of this PDF, the BioOne Complete website, and all posted and associated content indicates your acceptance of BioOne's Terms of Use, available at [www.bioone.org/terms-of-use](http://www.bioone.org/terms-of-use).

Usage of BioOne Complete content is strictly limited to personal, educational, and non - commercial use. Commercial inquiries or rights and permissions requests should be directed to the individual publisher as copyright holder.

---

BioOne sees sustainable scholarly publishing as an inherently collaborative enterprise connecting authors, nonprofit publishers, academic institutions, research libraries, and research funders in the common goal of maximizing access to critical research.

## Myocardial Purkinje Degeneration and Necrosis with Fibrosis in Free-Ranging Black Rhinoceroses (*Diceros bicornis*) in Zimbabwe

N. D. Kock, Faculty of Veterinary Science, University of Zimbabwe, P.O. Box MP167, Mount Pleasant, Harare, Zimbabwe

**ABSTRACT:** Degeneration and necrosis of Purkinje fibers with fibrosis around Purkinje fibers were found in the hearts of three adult black rhinoceroses (*Diceros bicornis*) in Zimbabwe in 1989 and 1990, among 38 animals examined from 1988 to 1994. Causes of death were not apparently related to these changes, nor was there evidence of heart failure. The etiology of these changes is unknown.

**Key words:** Black rhinoceros, *Diceros bicornis*, myocardial degeneration.

Degeneration, necrosis, and mineralization of myocardial Purkinje fibers, with fibrosis around the affected fibers have been described in cattle intoxicated by organomercurial compounds (Robinson and Maxie, 1985). Instances of this particular lesion in other species are unknown. I report three cases in adult black rhinoceroses (*Diceros bicornis*).

**Case 1:** An aged, adult male black rhinoceros had rear leg lameness at the time of capture for translocation from the lower Zambezi Valley (29° to 30°E, 15° to 16°S). It did poorly in confinement; because it was unable to ambulate adequately; it could not eat or drink sufficiently. Dehydration became extreme, and was probably responsible for its death, a few days later, on 4 July 1989. A postmortem examination was performed 12 hr after death. Samples of heart, lung, liver, kidney, spleen, adrenal gland, and lymph node were fixed in 10% buffered formalin, sectioned at 5 to 7  $\mu\text{m}$ , and stained with hematoxylin and eosin (H&E). Chronic degenerative joint disease was diagnosed in the left stifle, and was suspected to be traumatic in origin. In addition, nests of Purkinje fibers sequestered by prominent fibrous connective tissue were seen regularly in the heart (Fig. 1), although signs of chronic heart failure were not seen in lung or liver.

**Case 2:** An adult female black rhinoc-

eros developed suppurative wounds in the groin, vulva, and mammary tissue after fighting with another rhinoceros 2 yr after translocation from the lower Zambezi Valley into the Midlands (29°30' to 30°E, 19° to 19°25'S) of Zimbabwe. The animal declined in condition and died a few weeks later, on 22 June 1990. Postmortem examination was performed about 24 hr after death, as described for Case 1, and gross findings included only adrenal cortical hyperplasia. Microscopically, similar degenerative changes were found in and around myocardial Purkinje fibers as described for Case 1, again without signs of heart failure. The cause of death was believed to be directly related to the infective wounds.

**Case 3:** Little history was provided on a third case, an adult black rhinoceros, which had been translocated from the lower Zambezi Valley into the Midlands a few years prior to death. Postmortem examination was performed on 23 October 1990, approximately 24 hr after death, as described for Case 1. In addition to lymphoid atrophy of the spleen and adrenal cortical hyperplasia, acute degenerative changes were seen in myocardial Purkinje fibers, characterized by cytoplasmic eosinophilia and vacuolation, as well as acute necrosis with fragmentation of cytoplasm and mineralization (Fig. 2). As in Cases 1 and 2, signs of chronic heart failure were not present. The absence of clinical details, however, make it possible that the acute myocardial changes were responsible for death.

These three cases come from 38 free-ranging black rhinoceroses from Zimbabwe that had been examined by the author from 1988 through 1994. In addition, three captive animals from Whip-

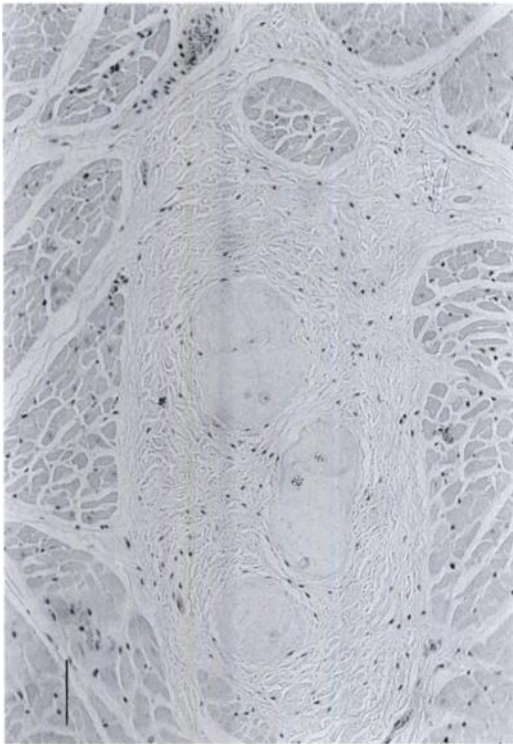


FIGURE 1. Nests of Purkinje fibers surrounded by mature fibrous connective tissue in the heart of a black rhinoceros (*Diceros bicornis*). H&E. Bar = 2.5mm.

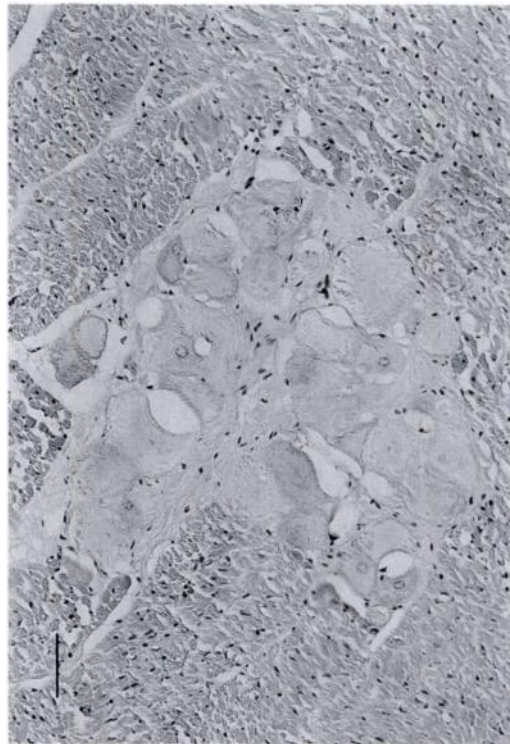


FIGURE 2. Purkinje fibers in the heart of a black rhinoceros (*Diceros bicornis*) showing signs of acute necrosis. Dark-staining fibers have fragmented cytoplasm and are partially mineralized. H&E. Bar = 2.5mm.

snade Wild Animal Park (Bedfordshire, England, United Kingdom), five and three free-ranging black rhinoceroses from Kenya and Namibia, respectively, were also without this lesion. Two of five free-ranging white rhinoceroses (*Ceratotherium simum*) from Kenya had similar Purkinjeal lesions, but were not included as case reports because details of the animals' deaths were not available. Six white rhinoceroses from Namibia and four from Zimbabwe were also without this lesion. All tissues had been fixed in formalin and evaluated as described previously.

It seems unlikely that the Purkinjeal changes reflect normal variation for black rhinoceroses, given they were found in only three of 49 cases. It is also unlikely the changes were age-related, given that only one of the cases occurred in an aged

animal. The other two were young adults. The 49 black rhinoceroses examined by the author represent an age span from that of a full term fetus to the aged adult reported here as Case 1.

Toxic plants and some chemical compounds have been associated with myocardial degeneration and necrosis in domestic animals (McEwan, 1964; Rogers et al., 1979), but reports of selective damage to myocardial Purkinje fibers are few. The cause of the changes described in these black rhinoceroses is not known, but they are similar to changes resulting from organomercurial intoxication in cattle (Robinson and Maxie, 1985). It is interesting that in Case 3, acute changes were discovered long after translocation, implying they occurred in the new habitat, and that in Case 1 chronic changes

were present in the natural habitat, before translocation.

I thank the University of Zimbabwe Research Board and International Wildlife Veterinary Services for financial support of this investigation. Thanks also go to the staff of the Faculty of Veterinary Science Paraclinical Studies Department for technical assistance, to Mr. David Tomu for photographic assistance, and to the field veterinarians and assistants for sample collection.

#### LITERATURE CITED

- MCEWAN, T. 1964. Isolation and identification of the toxic principle of *Gastrolobium grandiflorum*. *Nature* 201: 827.
- ROBINSON, W. G., AND M. G. MAXIE. 1985. The cardiovascular system. *In* Pathology of domestic animals, Vol. 3, 3rd ed. K. V. F. Jubb, P. C. Kennedy, and N. Palmer (eds.). Academic Press, London, England, p. 19.
- ROGERS, R. J., J. GIBSON, AND K. G. REICHMANN. 1979. The toxicity of *Cassia occidentalis* for cattle. *Australian Veterinary Journal* 55: 408-412.

*Received for publication 15 May 1995.*