



Hemolytic Anemia in Wild Seaducks Caused by Marine Oil Pollution

Authors: Yamato, Osamu, Goto, Ikuo, and Maede, Yoshimitsu

Source: Journal of Wildlife Diseases, 32(2) : 381-384

Published By: Wildlife Disease Association

URL: <https://doi.org/10.7589/0090-3558-32.2.381>

BioOne Complete (complete.BioOne.org) is a full-text database of 200 subscribed and open-access titles in the biological, ecological, and environmental sciences published by nonprofit societies, associations, museums, institutions, and presses.

Your use of this PDF, the BioOne Complete website, and all posted and associated content indicates your acceptance of BioOne's Terms of Use, available at www.bioone.org/terms-of-use.

Usage of BioOne Complete content is strictly limited to personal, educational, and non - commercial use. Commercial inquiries or rights and permissions requests should be directed to the individual publisher as copyright holder.

BioOne sees sustainable scholarly publishing as an inherently collaborative enterprise connecting authors, nonprofit publishers, academic institutions, research libraries, and research funders in the common goal of maximizing access to critical research.

Hemolytic Anemia in Wild Seaducks Caused by Marine Oil Pollution

Osamu Yamato, Ikuo Goto, and Yoshimitsu Maede, Laboratory of Medicine, Department of Veterinary Clinical Science, Graduate School of Veterinary Medicine, Hokkaido University, Sapporo 060, Japan

ABSTRACT: Clinico-pathological examinations were conducted on wild white-winged scoters (*Melanitta fusca*) contaminated with fuel oil (Bunker C oil) from a capsized cargo ship in February 1993 in Japan. The erythrocyte count, hemoglobin concentration and hematocrit value in the oiled seaducks all were decreased and numerous immature erythrocytes were observed in blood smears. In addition, hemosiderosis was observed in the liver, kidney, and lung of some birds. We propose that the seaducks suffered from hemolytic anemia induced by ingestion of oil, which occurs when the birds preen their oiled plumage.

Key words: Hemolytic anemia, hemosiderosis, Japan, marine oil pollution, *Melanitta fusca*, *M. nigra*, seaduck, white-winged scoter.

Oil pollution recently has become a serious hazard to waterfowl. Waterfowl can ingest oil when they preen their oiled plumage and when they eat oil-contaminated food or water (Hartung, 1963). The toxic effects of oil on birds have been experimentally studied. Oral doses of several petroleum products have produced various toxic changes affecting growth (Miller et al., 1978), reproduction (Holmes et al., 1978), osmoregulation (Crocker et al., 1975), steroid metabolism (Peakall et al., 1981), erythrocyte metabolism (Leighton et al., 1983), lymphocyte function (Leighton, 1986), and hepatic and renal functions (Hartung and Hunt, 1966). Based on these experimental studies, oil toxicity is a definite factor in the mortality of marine birds from oil pollution. However, there are few reports concerning the clinico-pathological findings of wild birds that become oiled.

On 26 January 1993, a cargo ship hit the rocks near Tomakomai Port (42°37'N, 141°35'E), Hokkaido, Japan, and 445.3 kl of fuel oil (Bunker C oil) spilled from the ship. Within 2 mo, local wildlife conservation officers and volunteers had collected 222 dead and 84 live oil-soaked seaducks. Of the 84 oiled birds, 32 birds re-

covered after treatment and were released. Our objective was to describe clinico-pathological observations of those wild seaducks poisoned by Bunker C oil.

Twenty-seven oil soaked seaducks, 15 white-winged scoters (*Melanitta fusca*), seven black scoters (*M. nigra*) and five oldsquaw (*Clangula hyemalis*), were admitted to the Veterinary Hospital of Hokkaido University, Sapporo, Japan, on 5 February 1993. These seaducks are common winter visitors to seacoasts and bays in Japan. Of these birds, 15 birds died soon after being admitted and were necropsied. The remaining 10 white-winged scoters (six males and four females) and two black scoters (one male and one female) were washed in five liters of 2% household neutral dish-washing detergent. They were dried by heated air and then housed in a nursing room. The birds were given water and fresh fish ad libitum. In addition, vitamin B complex consisting of 25 mg of thiamine hydrochloride, 25 mg of pyridoxine hydrochloride and 0.25 mg of cyanocobalamine (Vitamedin, Sankyo Company, Tokyo, Japan), and 50 mg of α -tocopherol (Juvela, Esai Co., Tokyo, Japan) also were administered orally every day in each ducks.

Blood samples were not collected from the seaducks when they were first presented to the Veterinary Hospital because much work was required for treatment of the seaducks, and we believed blood collection from the emaciated birds would be too make their stressful. On days 12 and 26 after the onset of treatment, about 3 ml of blood was withdrawn from the brachial vein into a syringe moistened with heparin. Red blood cell (RBC) count was calculated using a Thoma's hemocytometer (Kayagaki Co., Tokyo, Japan). Hematocrit (PCV) value was measured by the micro-

TABLE 1. Hematological and biochemical data of white-winged scoters (*Melanitta fusca*) poisoned by crude oil, February 1993, Japan.

Parameter	Day 12 (n=10) Mean (SD)	Day 26 (n=10) Mean (SD)
Erythrocyte count ($\times 10^6/\mu\text{l}$)	2.59 (0.53)	3.46 (0.32) ^a
Hematocrit value (%)	32.1 (2.9)	41.5 (3.7) ^a
Hemoglobin (g/dl)	8.2 (1.5)	12.3 (1.8) ^a
Polychromatic erythrocyte (%)	14.4 (3.4)	1.1 (0.5) ^a
Serum total protein (g/dl)	6.2 (0.5)	7.3 (0.7) ^a
Glucose (mg/dl)	135 (56)	196 (40) ^b
Aspartate aminotransferase (IU/l)	39 (18)	27 (11)
Alanine aminotransferase (IU/l)	81 (31)	50 (17) ^b
Alkaline phosphatase (IU/l)	703 (631)	228 (153) ^b
Blood urea nitrogen (mg/dl)	5.7 (1.2)	4.1 (1.8)

^a Significant ($P < 0.01$) difference between Day 12 and Day 26.^b Significant ($P < 0.05$) difference between Day 12 and Day 26.

hematocrit method and hemoglobin (Hb) concentration by the cyanmethemoglobin method (Jain, 1986). Polychromatic erythrocytes were evaluated in blood smears stained with Giemsa's stain, and expressed

as a percentage of the cells by examination of more than 500 RBCs. Serum total protein was determined by a protein refractometer (Hitachi Company, Tokyo, Japan). Glucose concentration, aspartate aminotransferase (AST), alanine aminotransferase (ALT), alkaline phosphatase (ALP) and blood urea nitrogen (BUN) in the serum were analyzed with a Cobas Mira autoanalyzer (Hoffmann-La Roche Co, Basel, Switzerland).

For histopathological study, tissue samples were fixed in 10% buffered formalin and embedded in paraffin, cut at 3 to 4 μm , and stained with hematoxylin and eosin. Selected tissue sections also were stained using Prussian blue (ferric ferrocyanide; Wako Pure Chemical Industries Ltd, Osaka, Japan) stain (Benevenga et al., 1976). Statistical significance was determined using the one-sample t -test (Cressie et al., 1984).

The RBC counts, PCV values, and Hb concentrations in the white-winged scoters all were significantly higher on day 26 than on day 12 (Table 1). In the blood smears, a number of polychromatic erythrocytes were observed on day 12 (Fig. 1a), but hardly observed on day 26 (Fig. 1b).

Concentrations of serum total protein and blood glucose in the white-winged scoters were significantly increased, and the values of ALT and ALP were signifi-

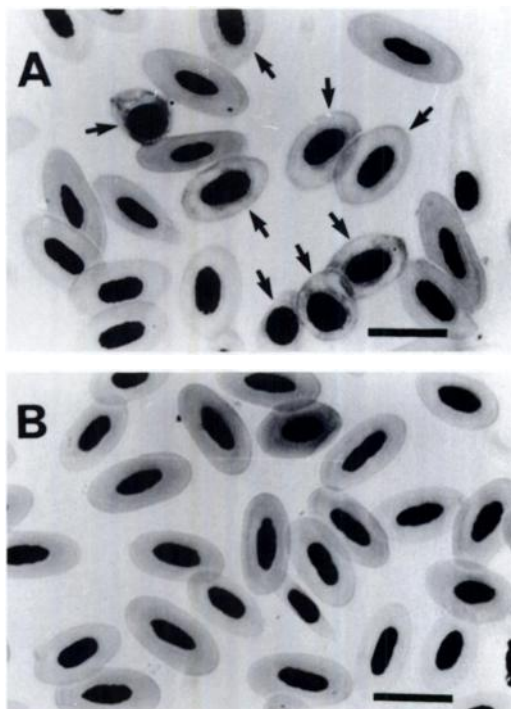


FIGURE 1. Blood smears of an oiled white-winged scoter on day 12 (a) and day 26 (b). Many polychromatic cells (arrows) are seen in a, but not found in b. Giemsa stain. Bar = 5 μm .

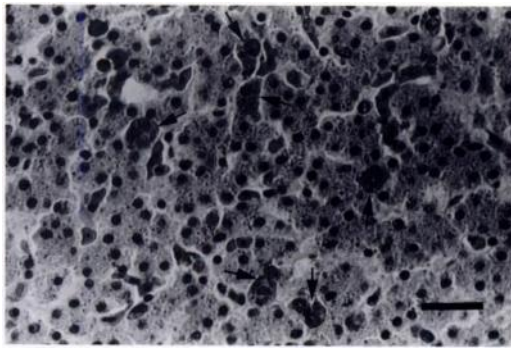


FIGURE 2. A marked deposition of hemosiderin in the liver of an oiled black scoter. Kupffer cells are filled with hemosiderin (arrows). Hemosiderin pigments also are seen within liver cells. H&E stain. Bar = 10 μ m.

cantly decreased during the treatment. The hematological changes in two black scoters were similar to those in the white-winged scoters (data not shown).

At necropsy, there were no significant gross findings; however, the livers of three of 15 ducks were tinged with dark green. There was no evidence of external or internal hemorrhage. There was a marked deposition of hemosiderin in the liver in all birds examined. Kupffer cells in the liver had a golden-brown pigment, which also was present in the cytoplasm of liver cells (Fig. 2). The pigment gave a positive reaction with Prussian blue stain, indicating hemosiderin (Benevenga et al., 1976). Hemosiderin also was found in the spleen and kidney, and sometimes in the lung. Hyaline droplets occasionally were seen in the cytoplasm of the renal proximal tubule cells.

Although normal levels for the RBC count, PCV value, and Hb concentration in these birds are unknown, the values obtained on day 12 were significantly lower than those on day 26 in the white-winged scoters. On day 26, serum total protein and glucose concentrations were increased in association with a recovery of appetite when compared with those on day 12, indicating a recovery of those birds to normal condition on day 26. Thus, we believe the birds had developed anemia when they

were admitted to the hospital. In addition, many polychromatic erythrocytes, immature cells, were seen on blood smears stained with Giemsa's stain on day 12, indicating elevated erythropoiesis in response to the anemia in the birds (Hawkey and Dennett, 1989). The marked hemosiderin deposition in the liver in all necropsied birds also was evidence for hemolysis in these birds. Based on these observations, we believed the birds examined suffered from hemolytic anemia (Leighton et al., 1983).

In the present study, the levels of serum ALT and ALP in the oiled birds on day 12 were significantly higher than those on day 26. In general, increased levels of both ALT and ALP in the blood are a sign of liver disease in most mammals (Kaneko, 1989). In birds, however, these enzymes are not specific indicators of liver damage (Lumeij, 1994). Most past studies on the toxicity of petroleum products to waterfowl were experimental works, in which effects of oil on various organs in experimentally fed birds were examined. To our knowledge, however, reports of clinicopathological findings in birds suffering from oil pollution in the wild are rare.

Leighton et al. (1983) reported that Heinz body hemolytic anemia occurred in herring gulls (*Larus argentatus*) and Atlantic puffins (*Fratercula arctica*) administered crude oil (10–20 ml/kg/day) for 4 or 5 days. Their results provide evidence that some oxidants contained in crude oil might damage erythrocytes of oiled birds, because Heinz body formation in erythrocytes is the result of oxidation of hemoglobin in response to various oxidants (Nagel and Ranney, 1973).

Our results support the report by Leighton et al. (1983) that the primary target of oil toxicity in the birds was the peripheral red blood cells.

ACKNOWLEDGMENTS

Thanks are extended to Dr. K. Baba in the Baba Veterinary Hospital in Kawasaki, Japan, and all members of the Hokkaido Wildlife Con-

servation office for advising us about the care and treatment of the oiled birds.

LITERATURE CITED

- BENEVENGA, N. J., M-H. YEN, AND J. J. LALICH. 1976. Growth depression and tissue reaction to the consumption of excess dietary methionine and S-methyl-L-cysteine. *Journal of Nutrition* 106: 1714-1720.
- CRESSIE, N. A., L. J. SHEFFIELD, AND H. J. WHITFORD. 1984. Use of the one sample *t*-test in the real world. *Journal of Chronic Diseases* 37: 107-114.
- CROCKER, A. D., J. CRONSHAW, AND W. N. HOLMES. 1975. The effect of several crude oils and some petroleum distillation fractions on intestinal absorption in ducklings (*Anas platyrhynchos*). *Environmental Physiology and Biochemistry* 5: 92-106.
- HARTUNG, R. 1963. Ingestion of oil by waterfowl. *Michigan Academy of Science, Arts, and Letters* 68: 49-55.
- , AND G. S. HUNT. 1966. Toxicity of some oils to waterfowl. *The Journal of Wildlife Management* 30: 564-570.
- HAWKEY, C. M., AND DENNETT, T. B. (EDITORS). 1989. *Comparative veterinary haematology*. Wolfe Publication Ltd., London, United Kingdom, pp. 9-57.
- HOLMES, W. N., K. P. CAVANAUGH, AND J. CRONSHAW. 1978. The effects of ingested petroleum on oviposition and some aspects of reproduction in experimental colonies of mallard ducks (*Anas platyrhynchos*). *Journal of Reproduction and Fertility* 54: 335-347.
- JAIN, N. C. 1986. *Schalm's veterinary hematology*, 4th ed. Lea and Febiger, Philadelphia, Pennsylvania, pp. 41-45.
- KANEKO, J. J. 1989. *Clinical biochemistry of domestic animals*, 4th ed. Academic Press, Inc., San Diego, California, pp. 381-385.
- LEIGHTON, F. A. 1986. Clinical, gross, and histological findings in herring gulls and Atlantic puffins that ingested Prudhoe Bay crude oil. *Veterinary Pathology* 23: 254-263.
- , D. B. PEAKALL, AND R. G. BUTLER. 1983. Heinz-body hemolytic anemia from the ingestion of crude oil: A primary toxic effect in marine birds. *Science* 220: 271-273.
- LUMEIJ, J. T. 1994. Avian clinical enzymology. *Seminars in Avian and Exotic Pet Medicine* 3: 14-24.
- MILLER, D. S., D. B. PEAKALL, AND W. B. KINTER. 1978. Ingestion of crude oil: Sublethal effects in herring gull chicks. *Science* 199: 315-317.
- NAGEL, R. L., AND H. M. RANNEY. 1973. Drug-induced oxidative denaturation of hemoglobin. *Seminars in Hematology* 10: 269-278.
- PEAKALL, D. B., J. TREMBLAY, W. B. KINTER, AND D. S. MILLER. 1981. Endocrine dysfunction in seabirds caused by ingested oil. *Environmental Research* 24: 6-14.

Received for publication 10 April 1995.