

Polycystic kidney disease in a raccoon (*Procyon lotor*)

Authors: Hamir, Amir N., and Klein, Lin

Source: Journal of Wildlife Diseases, 32(4) : 674-677

Published By: Wildlife Disease Association

URL: <https://doi.org/10.7589/0090-3558-32.4.674>

BioOne Complete (complete.BioOne.org) is a full-text database of 200 subscribed and open-access titles in the biological, ecological, and environmental sciences published by nonprofit societies, associations, museums, institutions, and presses.

Your use of this PDF, the BioOne Complete website, and all posted and associated content indicates your acceptance of BioOne's Terms of Use, available at www.bioone.org/terms-of-use.

Usage of BioOne Complete content is strictly limited to personal, educational, and non - commercial use. Commercial inquiries or rights and permissions requests should be directed to the individual publisher as copyright holder.

BioOne sees sustainable scholarly publishing as an inherently collaborative enterprise connecting authors, nonprofit publishers, academic institutions, research libraries, and research funders in the common goal of maximizing access to critical research.

Polycystic kidney disease in a raccoon (*Procyon lotor*)

Amir N. Hamir^{1,2} and Lin Klein,¹ ¹School of Veterinary Medicine, University of Pennsylvania, New Bolton Center, 382 West Street Road, Kennett Square, Pennsylvania 19348, USA ²Present address: Veterinary Diagnostic Laboratory, Oregon State University, 142 Magruder Hall, Corvallis, Oregon 97331, USA

ABSTRACT: During March 1988, a case of bilateral polycystic kidney disease (PKD) occurred in an aged raccoon (*Procyon lotor*) at a zoo in Wilmington, Delaware (USA). Prior to its death, the raccoon had no clinical signs. On necropsy there was bilateral enlargement of kidneys which, on cut sections, had many variable sized fluid-filled cystic cavities. Endometrial hyperplasia with presence of multiple variable-sized cysts were also seen in the uterus of this raccoon. Microscopical examinations were characteristic of an end-stage renal failure due to PKD. Neither PKD nor cystic endometrial hyperplasia appears to have been previously described in this species.

Key words: Polycystic kidney disease, cystic endometrial hyperplasia, renal failure, uremia, dystrophic mineralization, raccoon, *Procyon lotor*, case report.

Polycystic kidney disease (PKD) is a fairly common condition in humans (Gabow, 1993) and has infrequently been reported in a variety of domestic (Crowell et al., 1979; van den Ingh and Rothwizen, 1985; Reindel et al., 1988), laboratory (Fox et al., 1971; Andrews et al., 1979; Nauta et al., 1993), and wildlife species (Iverson et al., 1982). In humans, dogs and cats, PKD is considered to be heritable (Crowell et al., 1979; McKenna and Carpenter, 1980; Gabow, 1993) and is characterized by bilateral multiple cyst formations in differentiated kidneys.

We describe a case of bilateral polycystic kidneys and cystic endometrial hyperplasia in a raccoon (*Procyon lotor*). To our knowledge neither of these conditions have been documented in this species.

The subject was an aged female raccoon held in captivity at Brandywine Zoo, Wilmington, Delaware (USA) since 1977. On 22 March 1988 it was found dead. The animal was in a cage by itself and had appeared normal the previous day. No abnormal behavior had been noted in recent

weeks, and she had been consuming all of her normal diet.

On necropsy the carcass was in poor nutritional state as judged by the muscle mass. The gastrointestinal tract was empty. Both kidneys were markedly enlarged (approximately 9 cm by 6 cm; Fig. 1). On cut sections both contained variable sized (2 to 25 mm in diameter) fluid-filled cystic cavities in the cortical and medullary regions (Fig. 2). The uterine horns were slightly distended and turgid. A small fluid-filled cyst was present at the tip of the right horn.

Representative tissues of heart, lung, liver, gall bladder, kidney, pancreas, spleen, skin, skeletal muscles, stomach, intestines, mesenteric lymph node, eye, salivary gland, urinary bladder, trachea, thyroids, esophagus, aorta, adrenal glands, ovaries, uterus, brain and spinal cord were fixed in neutral buffered formalin, embedded in paraffin, sectioned at 5 μ m and stained with hematoxylin and eosin. Selected tissue sections of the uterus and stomach were also stained with McManus Periodic Acid Schiff (PAS) and von Kossa stains, respectively (Luna, 1968).

Microscopic lesions in the kidneys consisted of variable-sized cystic cavities in both the cortex and medulla. The cysts were lined by a layer of attenuated tubular epithelial cells and contained homogeneous proteinaceous material (Fig. 3). In a few cysts, eosinophilic granular material was seen. There was little relatively normal renal parenchyma present between the cysts. This tissue was infiltrated with moderate numbers of lymphocytes.

In several sections of the uterus, there was an extensive diffuse cystic proliferation of the endometrium. The cysts were variable in size (less than 1 mm in diam-

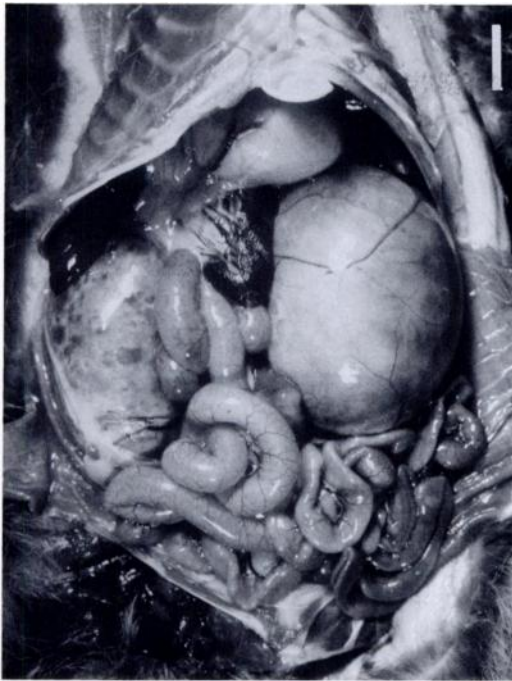


FIGURE 1. Abdominal organs of a raccoon showing bilaterally enlarged (polycystic) kidneys. Bar = 2 cm.

eter), and considerably smaller than in the kidneys, they also were lined by a layer of cuboidal to columnar cells. Some of the cysts contained eosinophilic, PAS-positive material.

Lesions in the gastrointestinal tract were confined to the stomach; the lamina propria had extensive multifocal mineralized areas. The mineral deposits were confirmed by von Kossa stain and were found to be more prominent around small capillaries.

There were multifocal mineralized areas in the walls of the blood vessels in the brain. The lesions were predominantly in the media and were found bilaterally in the areas of globus pallidus. The affected vessels were patent and there was no inflammatory cellular response to the mineralized foci.

The raccoon also had multifocal areas of lipid pneumonia (alveolar histiocytosis) and presence of moderate numbers of *Sarcocystis* sp.-like parasites in skeletal mus-

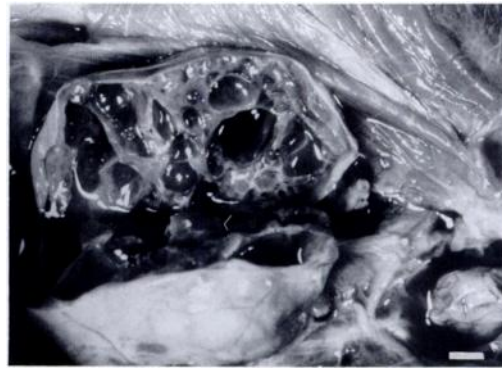


FIGURE 2. Left kidney of the raccoon shown in Figure 1 has been longitudinally cut to show many fluid-filled cystic cavities. Bar = 1 cm.

cles. These lesions are considered incidental background findings of free ranging raccoons in the eastern United States (Kirkpatrick et al., 1987; Hamir et al., 1996).

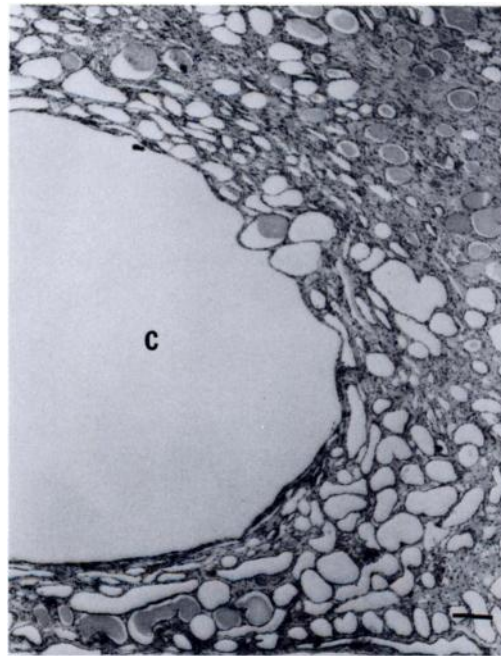


FIGURE 3. Photomicrograph of the polycystic kidney showing one large (C) and many small cystic cavities. The cysts are lined by a single layer of attenuated epithelial cells. There is homogeneous proteinaceous material in some of the small cysts. H&E stain. Bar = 110 μ m.

The cause of cachexia in this raccoon was attributed to uremia due to renal failure as a result of bilateral polycystic kidneys. In light of her previous days' normal behavior and appetite, the exact cause of death is somewhat perplexing. The mineralization of the gastric lamina propria was considered a secondary uremic lesion (Barker et al., 1993). However, the cerebro-vascular mineralization in globus pallidus has not been associated with renal failure in animals. This lesion appeared to have a different pathogenetic mechanism and although it has previously not been described in raccoons, a similar non-symptomatic condition has been documented in horses (Jubb and Huxtable, 1993).

In this adult raccoon, cystic changes were present not only in the kidneys, but also in the uterus. However, the changes observed in the uterus may be unrelated to the PKD. In this regard, the uterine changes described in this raccoon were very similar to a distinct syndrome in dogs and cats (cystic endometrial hyperplasia) which probably has a hormonal etiology (Kennedy and Miller, 1993). Cystic endometrial hyperplasia has not been documented in raccoons.

Polycystic kidney disease (PKD) is infrequently reported in domestic animals and has been reported in only one species of wild animal, the springbok (*Antidorcas marsupialis*) (Iverson et al., 1982). In the affected animals, the disease appears to have a heritable pattern. Extra-renal cystic lesions have also been described in other organs such as the liver and pancreas in animals with PKD (Reindel et al., 1988; Gabow, 1993).

In the United States polycystic kidney disease (PKD) is considered to be the third most common cause of renal failure in humans. One in every 800 individuals may have this condition (Hogewind et al., 1980). In humans PKD exists in two forms: autosomal dominant and autosomal recessive. The former is more common and is seen in adults. The latter form is uncommon, affects children, and is asso-

ciated with cystic changes in both the kidneys and in the liver (Iverson et al., 1982). In animals the hereditary pattern is not completely understood. However, in the dog and springbok it is believed to be of autosomal recessive type (McKenna and Carpenter, 1980; Iverson et al., 1982).

At this stage, since no other cases of PKD have been described in raccoons, the available information is insufficient to explain the mode of inheritance of PKD in raccoons. Further case reports of this disease in raccoons may help to elucidate not only the presence of lesions in different organs, but also the nature of inheritance of PKD in this species.

This study was supported in part by a grant from the Laboratory of Large Animal Pathology, University of Pennsylvania. The technical expertise of B. Lehmann and S. Hindmann is greatly appreciated.

LITERATURE CITED

- ANDREWS, P. L. R., O. ILLMAN, AND A. MELLERSH. 1979. Some observations of anatomical abnormalities in a population of 350 ferrets (*Mustela furo* L.). *Zeitschrift für Versuchstierkunde* 21: 346–351.
- BARKER, I. A., A. A. VAN DREUMEL, AND N. PALMER. 1993. The alimentary system. In *Pathology of domestic animals*, Vol. 2, 4th ed. K. V. F. Jubb, P. C. Kennedy, and N. Palmer (eds.). Academic Press, San Diego, California, pp. 1–318.
- CROWELL, W. A., J. J. HUBBELL, AND J. C. RILEY. 1979. Polycystic renal disease in related cats. *Journal of the American Veterinary Medical Association* 175: 286–288.
- FOX, R. R., W. L. KRINSKY, AND D. D. CARY. 1971. Hereditary cortical renal cysts in the rabbit. *Journal of Heredity* 62: 105–109.
- GABOW, P. A. 1993. Autosomal dominant polycystic kidney disease. *New England Journal of Medicine* 329: 332–342.
- HAMIR, A. N., C. A. HANLON, AND C. E. RUPPRECHT. 1996. Endogenous lipid pneumonia (multifocal alveolar histiocytosis) in raccoons (*Procyon lotor*). *Journal of Veterinary Diagnostic Investigation* 8: 267–269.
- HOGEWIND, B. L., J. J. VELTKAMP, C. W. KOCH, AND J. DEGRAEFF. 1980. Genetic counseling for adult polycystic kidney disease: Ultrasound a useful tool in pre-symptomatic diagnosis? *Clinical Genetics* (Copenhagen) 14: 61–72.
- IVERSON, W., G. FETTERMAN, E. JACOBSON, J. OLSEN, D. SENIOR, AND E. SCHOBERT. 1982. Poly-

- cystic kidney and liver disease in springbok: 1. Morphology of the lesions. *Kidney International* 22: 146–155.
- JUBB, K. V. F., AND C. R. HUXTABLE. 1993. The nervous system. *In* Pathology of domestic animals, Vol. 1, 4th ed. K. V. F. Jubb, P. C. Kennedy, and N. Palmer (eds.). Academic Press, San Diego, California, pp. 267–439.
- KENNEDY, P. C., AND R. B. MILLER. 1993. The female genital system. *In* Pathology of domestic animals, Vol. 3, 4th ed. K. V. F. Jubb, P. C. Kennedy, and N. Palmer (eds.). Academic Press, San Diego, California, pp. 349–470.
- KIRKPATRICK, C. E., A. N. HAMIR, J. P. DUBEY, AND C. E. RUPPRECHT. 1987. Sarcocystis in muscles of raccoons (*Procyon lotor* L.). *The Journal of Protozoology* 34: 445–447.
- LUNA, L. G. 1968. Manual of histologic staining methods of the Armed Forces Institute of Pathology, 3rd. ed. McGraw-Hill Book Company, New York, New York, 258 pp.
- MCKENNA, S. C., AND J. L. CARPENTER. 1980. Polycystic disease of the kidney and liver in the Cairn terrier. *Veterinary Pathology* 17: 436–442.
- NAUTA, J., Y. OZANA, W. SWEENEY, J. RUTLEDGE, AND E. ARNER. 1993. Renal and biliary abnormalities in a new murine mode of autosomal recessive polycystic kidney disease. *Pediatric Nephrology* 7: 146–172.
- REINDEL, J., T. MULLANEY, P. D. METZAT, AND E. MILLER. 1988. Polycystic disease of neonatal piglets. *Laboratory Investigation* 58: 1–76.
- VAN DEN INGH, T. S. G. A. M., AND J. ROTHWIZEN. 1985. Congenital cystic disease of the liver in seven dogs. *Journal of Comparative Pathology* 95: 405–414.

Received for publication 12 February 1996.