

Luteinized Ovarian Cysts in Mediterranean Striped Dolphins

Authors: Munson, Linda, Calzada, Nuria, Kennedy, Seamus, and Sorensen, Thomas B.

Source: Journal of Wildlife Diseases, 34(3) : 656-660

Published By: Wildlife Disease Association

URL: <https://doi.org/10.7589/0090-3558-34.3.656>

The BioOne Digital Library (<https://bioone.org/>) provides worldwide distribution for more than 580 journals and eBooks from BioOne's community of over 150 nonprofit societies, research institutions, and university presses in the biological, ecological, and environmental sciences. The BioOne Digital Library encompasses the flagship aggregation BioOne Complete (<https://bioone.org/subscribe>), the BioOne Complete Archive (<https://bioone.org/archive>), and the BioOne eBooks program offerings ESA eBook Collection (<https://bioone.org/esa-ebooks>) and CSIRO Publishing BioSelect Collection (<https://bioone.org/csiro-ebooks>).

Your use of this PDF, the BioOne Digital Library, and all posted and associated content indicates your acceptance of BioOne's Terms of Use, available at www.bioone.org/terms-of-use.

Usage of BioOne Digital Library content is strictly limited to personal, educational, and non-commercial use. Commercial inquiries or rights and permissions requests should be directed to the individual publisher as copyright holder.

BioOne is an innovative nonprofit that sees sustainable scholarly publishing as an inherently collaborative enterprise connecting authors, nonprofit publishers, academic institutions, research libraries, and research funders in the common goal of maximizing access to critical research.

Luteinized Ovarian Cysts in Mediterranean Striped Dolphins

Linda Munson,¹ Nuria Calzada,² Seamus Kennedy,³ and Thomas B. Sorensen,^{4,1} Department of Pathology, Microbiology, and Immunology, School of Veterinary Medicine, University of California, Davis, California 95616, USA; ² Department of Animal Biology, Faculty of Biology, University of Barcelona, 08028 Barcelona, Spain; ³ Department of Pathology, Veterinary Sciences Division, Department of Agriculture, Stormont, Belfast, Northern Ireland; and ⁴ Zoological Institute, University of Copenhagen, DK-2100 Copenhagen, Denmark.

ABSTRACT: The morbillivirus epizootic during 1990 to 1992 in Mediterranean striped dolphins (*Stenella coeruleoalba*) off the Mediterranean coast of Spain diminished these populations directly through mortalities, and indirectly through loss of normal fecundity. High levels of polychlorinated biphenyls (PCB's) also were detected in stranded animals. In addition to high numbers of abortions during the epidemic, unusual cystic structures were noted in the ovaries of several morbillivirus-infected dolphins with high PCB levels. These structures were identified as multiple luteinized cysts from their gross and histomorphologic characteristics. No morbillivirus antigens were detected in the lesions by immunohistochemistry. Because luteinized cysts occur when ovulation is impeded, either an effect of morbillivirus or PCB's on hypothalamic/pituitary function or an effect of PCB's on ovarian responsiveness are proposed as pathogenic mechanisms. These cysts may impede population recovery from the epidemic if similar cysts occurred on surviving dolphins.

Key words: Luteinized cyst, Mediterranean striped dolphin, morbillivirus, ovary, polychlorinated biphenyl, *Stenella coeruleoalba*.

The morbillivirus epidemic of 1990 to 1992 resulted in the stranding and death of over 1,000 Mediterranean striped dolphins (*Stenella coeruleoalba*) off the Spanish Mediterranean coast (Aguilar and Raga, 1993; Calzada et al., 1994). Most of the stranded dolphins also had high tissue concentrations of polychlorinated biphenyls (PCB), and the role of these environmental contaminants on the health of the dolphins remains unclear (Aguilar and Borrell, 1994). The epidemic occurred during the height of breeding season (September and October), and the impact on reproductive functions has not been fully assessed. During the epidemic, an abnormally high percentage of females had young corpora albicans and uterine distention suggestive of recent abortion, and un-

characteristically high numbers of dead fetuses were found (Calzada et al., 1996). Ovaries from several other females examined during necropsy had unusual cystic structures not previously observed in the ovaries of any healthy related *Stenella* spp. The purpose of this study was to characterize these ovarian structures and determine if these lesions were caused by morbillivirus infection of the ovary.

Ovaries of 56 sexually-mature female striped dolphins were collected in summer of 1990 and 1992. All dolphins in the study group had stranded during the epidemic and had high PCB levels (Aguilar and Borrell, 1994). The ages of dolphins were determined by counting growth layer groups in the dentine of decalcified and longitudinally-sectioned teeth. Each growth layer group was assumed to represent 1 yr (Calzada et al., 1994). Sexual maturity was determined by identifying corpora lutea and corpora albicans in serial sectioned fixed ovaries. From the population of 56 sexually mature females, the ovaries of four females had unusual cystic structures that were examined by histopathology. Dolphins with cysts were 14-, 14-, 18- and 19-yr-old. They were confirmed to have morbillivirus infection (Domingo et al., 1992), and were not pregnant. The stranding sites of these four dolphins were Castelldefells (41.17°N, 1.58°E), Salou (41.04°N, 1.08°E), Tarragona (41.07°N, 1.15°E) and Cartagena (37.36°N, 0.59°W). The ovaries of two healthy pregnant females also were included as examples of normal pregnancy corpora lutea.

For histopathology, formalin-fixed ovaries were deparaffinized in xylene, embedded in paraffin, sectioned at 7 µm, and stained with hematoxylin and eosin, Mas-

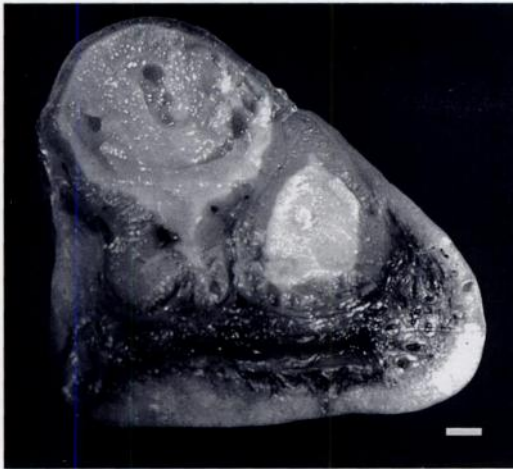

FIGURE 1. Ovary from a striped dolphin with two luteinized cysts. Bar = 3 mm.

son's trichrome, and periodic acid Schiff's reagent methods (Luna, 1992). The presence of morbillivirus antigen in tissues was assessed by immunohistochemistry using a previously published method (Kennedy et al., 1991), and a mouse monoclonal antibody (clone 1.3) against glycosylated hemagglutinin protein of phocine distemper virus as the primary antibody (Trudgett et al., 1991).

The unusual ovarian structures were large thick-walled cysts that ranged from 16 to 23 mm in diameter (Fig. 1). The 23 mm diameter cyst had an 18 mm diameter central cavity, in contrast to the corpora lutea from normal pregnant dolphins that were solid structures 24 to 26 mm in diameter. One dolphin had a single 23 mm diameter cyst, two dolphins had two cysts and one dolphin had four cysts. The cysts were located in the cortical parenchyma and were covered by ovarian stroma without an ovulation stigmata. The cyst lumina were round, lined with mottled gray-yellow soft tissue, and filled with grey gelatinous material. Histologically, the cysts were lined by a thick, disorganized, multicellular layer composed of elongate granulosa/theca cells with minimal luteinization (Fig. 2). The luteinized cells were arranged haphazardly and were divided into irregular lobules by dense fibrous septa

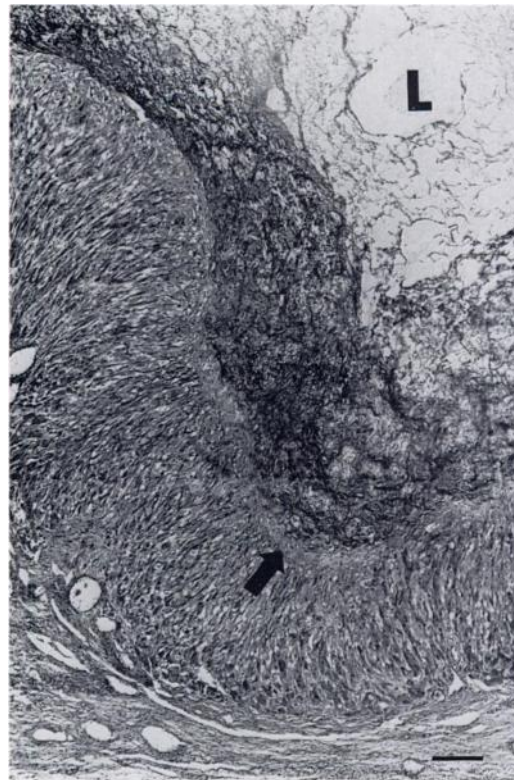


FIGURE 2. Histologic appearance of a luteinized cyst in the ovary of a striped dolphin. The cyst is lined by spindle-shaped granulosa/thecal cells with minimal luteinization that are separated from the lumen (L) by a mature fibrous band (arrow). Masson's trichrome stain. Bar = 30 μ m.

with minimal vascularization. The cyst lumina were filled with fibrillar proteinaceous fluid surrounded by a thick rim of mature fibrous connective tissue. In comparison, corpora lutea of normal dolphins had plump polygonal luteal cells with prominent intercellular vascularization surrounding a core of solid fibrous tissue. Ovaries with the cysts also had developing follicles, multiple corpora albica and no normal corpora lutea. Morbillivirus antigen was not detected in any ovary from the females with cysts.

The multiple cystic structures on the ovaries of the stranded dolphins were most compatible with luteinized follicular cysts (McEntee, 1990; Kennedy and Miller, 1993). The absence of an ovulation stigmata and presence of more than one struc-

ture in three of four females from a species that is monotocous (Marshall, 1984) indicates that these structures were abnormal. Morphologic characteristics that suggest that they are luteinized cysts and not cystic corpora lutea (CL) were the large expansive central cavity with a thick mature fibrous lining and the small, angular shape of the luteal cells. (Kennedy and Miller, 1993). The lack of concordance between the immaturity of the spindle-shaped luteal cells and maturity of the fibrous tissue lining of the central cavity indicated that these structures were not developing CLs. These cysts did not have features of cystic CLs which are characterized by a larger overall size, an irregular central cavity containing organizing loose fibrous tissue, and plump luteal cells (Van Lennep, 1950; Harrison and McBrearty, 1977; Kennedy and Miller, 1993). Although the dolphin cysts were similar to accessory corpora lutea (CL) that rarely have been observed in the ovaries of pregnant Odontocetes (Brodie, 1972) and Delphinids (Harrison and McBrearty, 1977; Marsh and Kasuya, 1984), none of the affected dolphins were pregnant.

In monotocous cetacean species, a single Graafian follicle ovulates resulting in a corpus luteum that may have a central cavity which usually becomes obliterated as it matures (Harrison and McBrearty, 1977; Harrison, 1981). In land mammals, if one or more Graafian follicles fails to ovulate, follicular cysts develop and luteinization of granulosa or thecal cells can ensue. Ovulation failure in land mammals is thought to be due to inadequate levels of luteinizing hormone (LH) or inappropriate timing of LH secretion from the pituitary (Youngquist, 1986).

The pathogenesis of the luteinized cysts in the dolphins also may be due to inadequate or untimely release of LH or lack of LH responsiveness in the follicle. LH release may have been affected by morbillivirus infection of the central nervous system, PCB toxicity, stranding stress, or poor nutritional status. All dolphins with

cysts were infected with morbillivirus, including viral infection of the central nervous system (Domingo et al., 1992; Duignan et al., 1992). The absence of viral antigens in the ovary of affected dolphins does not exclude the possibility that morbillivirus indirectly affected ovulation through infection of the hypothalamus or pituitary, thereby impeding gonadotrophin-releasing hormone (GnRH) or LH synthesis or release.

Another possible cause of the cysts in these dolphins was high systemic PCB levels (Aguilar and Borrell, 1994). Polychlorinated biphenyls and related xenobiotics act as estrogen agonists/antagonists (Gorospe and Reinhard, 1995) that could impair follicular development and positive feedback of estrogens on pituitary LH release (Mahony and Hodgen, 1995). Polychlorinated biphenyls affect fecundity in other species, including marine mammals (Reijnders, 1980; Golub et al., 1991; Gorospe and Reinhard, 1995), and reduced fertility has been proven experimentally in monkeys (Arnold et al., 1995), rodents (Marks et al., 1989; Golub et al., 1991), and rabbits (Lindenau et al., 1994). Unique isomers of PCB's accumulate in the follicular fluid of the ovary, resulting in reduced ovulation in rabbits (Lindenau et al., 1994). In teleosts fed PCB's, gonadal hormone levels were reduced and pituitary secretion was diminished (Thomas, 1990). Polychlorinated biphenyls therefore could contribute to the formation of luteinized follicles by altering follicular responsiveness directly or reducing pituitary secretion of LH. Polychlorinated biphenyls have been linked with declining reproductive function in seals at 701 $\mu\text{g/g}$ fat (range 87 to 1,447 $\mu\text{g/g}$ fat) (Reijnders, 1980), and mean levels ($\pm\text{SD}$) of PCB's were even greater in dolphins with luteinized cysts ($1,081.3 \pm 684.4$ $\mu\text{g/g}$ liver; $1,017.3 \pm 665.0$ $\mu\text{g/g}$ fat) than in the population as a whole (median, 778 $\mu\text{g/g}$ lipid basis) (Aguilar and Borrell, 1994).

The poor nutritional status of the infected dolphins also could potentially in-

terfere with normal pituitary LH release, leading to luteinized cyst formation. Poor nutritional status compromises normal hypothalamic and pituitary function (Dubey et al., 1986), and the morbillivirus-infected dolphins had lipid reserves that were estimated at 60% below normal (Aguilar and Raga, 1993). Stress from stranding also may have contributed to abnormal reproductive function, because experimentally-induced stress results in increased endogenous corticosteroids and decreased LH release in other species (Moberg, 1985). Luteinized and unluteinized follicular cysts have been reported on ovaries from other stranded and captured delphinids (Harrison and McBrearty, 1977; Harrison, 1981), supporting a possible role of stress.

The final outcome of the reproductive disorders that occurred in the Mediterranean dolphin population during the morbillivirus stranding has yet to be assessed. While these ovarian cysts are of no life-threatening consequence to individual dolphins, their significance to the population may be more portentous. Mediterranean striped dolphins are seasonal breeders with most breeding occurring during September and October (Forcada et al., 1994), precisely when the morbillivirus epidemic occurred (Forcada et al., 1994; Calzada et al., 1996). High numbers of abortions also were suspected (Calzada et al., 1996), and school size and structure which determine reproductive behavior were markedly altered (Forcada et al., 1994). If luteal cysts also occurred in surviving females, these females would be unlikely to produce offspring until the next breeding season, augmenting losses in the population. If morbillivirus caused these reproductive changes, population recovery might occur during the subsequent period of population immunity (Appel, 1987) if reproductive functions are restored. However, if PCB toxicity is the basis for the reproductive disorders observed during the Mediterranean dolphin strandings, continued reproductive problems are like-

ly, threatening long-term population recovery.

We thank T. Lipscomb and Y. Schulman for reviewing these cases, A. Trudgett for provision of the monoclonal antibody and D. Moffett for technical assistance. N. Calzada was funded by an FPI fellowship from the Ministry of Education and Science of Spain.

LITERATURE CITED

- AGUILAR, A., AND A. BORRELL. 1994. Abnormally high polychlorinated biphenyl levels in striped dolphins (*Stenella coeruleoalba*) affected by the 1990-1992 Mediterranean epizootic. *The Science of the Total Environment* 154: 237-247.
- , AND J. A. RAGA. 1993. The striped dolphin epizootic in the Mediterranean Sea. *Ambio* 22: 524-528.
- APPEL, M. J. G. 1987. Canine distemper virus. In *Virus infections in carnivores*, M. J. G. Appel (ed.). Elsevier Science Publisher, Amsterdam, The Netherlands, pp. 133-160.
- ARNOLD, D. L., F. BRYCE, P. F. MCGUIRE, R. STAPLEY, J. R. TANNER, E. WRENSHALL, J. MES, S. FERNIE, H. TRYPHONAS, AND S. HAYWARD. 1995. Toxicological consequences of aroclor 1254 ingestion by female rhesus (*Macaca mulatta*) monkeys. Part 2. Reproduction and infant findings. *Food and Chemical Toxicology* 33: 457-474.
- BRODIE, P. F. 1972. Significance of accessory corpora lutea in Odontocetes with reference to *Delphinapterus leucas*. *Journal of Mammalogy* 53: 614-616.
- CALZADA, N., C. H. LOCKYER, AND A. AGUILAR. 1994. Age and sex composition of the striped dolphin die-off in the western Mediterranean. *Marine Mammal Science* 10: 299-310.
- , A. AGUILAR, T. B. SORESENSEN, AND C. LOCKYER. 1996. Reproductive biology of the female Mediterranean striped dolphin (*Stenella coeruleoalba*) from the western Mediterranean. *Journal of Zoology (London)* 240: 581-591.
- DOMINGO, M., J. VISA, M. PUMAROLA, A. J. MARCO, L. FERRER, R. RABANAL, AND S. KENNEDY. 1992. Pathologic and immunocytochemical studies of morbillivirus infection in striped dolphins (*Stenella coeruleoalba*). *Veterinary Pathology* 29: 1-10.
- DUBEY, A. K., J. L. CAMERON, R. A. STEINER, AND T. M. PLANT. 1986. Inhibition of gonadotropin secretion in castrated male rhesus monkeys (*Macaca mulatta*) induced by dietary restriction: Analogy with the prepubertal hiatus of gonadotropin release. *Endocrinology* 118: 518-525.
- DUIGNAN, P. J., J. R. GERACI, J. A. RAGA, AND N. CALZADA. 1992. Pathology of morbillivirus in-

- fection in striped dolphins (*Stenella coeruleoalba*) from Valencia and Murcia, Spain. *Canadian Journal of Veterinary Research* 56: 242–248.
- FORCADA, J., A. AGUILAR, P. S. HAMMOND, X. PASTOR, AND R. AGUILAR. 1994. Distribution and numbers of striped dolphins in the western Mediterranean Sea after the 1990 epizootic outbreak. *Marine Mammal Science* 10: 137–150.
- GOLUB, M. S., J. M. DONALD, AND J. A. REYES. 1991. Reproductive toxicity of commercial PCB mixtures: LOAELs and NOAELs from animal studies. *Environmental Health Perspectives* 94: 245–253.
- GROSPE, W. C., AND R. REINHARD. 1995. Toxic effects on the ovary of the nonpregnant female. *In* Reproductive toxicology, 2nd ed., R. J. Witorsch (ed.). Raven Press, New York, New York, pp. 141–173.
- HARRISON, R. J. 1981. Ovarian characteristics, corpora lutea, and corpora albicantia in *Delphinus delphis* stranded on the Atlantic coast of France. *Aquatic Mammals* 8: 69–76.
- , AND D. A. MCBREARTY. 1977. Ovarian appearances in captive delphinids (*Tursiops* and *Lagenorhynchus*). *Aquatic Mammals* 5: 57–66.
- KENNEDY, P. C., AND R. MILLER. 1993. The female genital system. *In* Pathology of domestic animals, 4th ed., K. V. F. Jubb, P. C. Kennedy and N. Palmer (eds.). Academic Press Inc., New York, New York, pp. 349–470.
- KENNEDY, S., J. A. SMITH, P. F. CUSH, S. J. MCALISKEY, AND B. K. RIMA. 1991. Histopathology and immunohistochemical studies of distemper in harbor porpoises. *Veterinary Pathology* 28: 1–7.
- LINDENAU, A., B. FISCHER, P. SEILER, AND H. M. BEIER. 1994. Effects of persistent chlorinated hydrocarbons on reproductive tissues in female rabbits. *Human Reproduction* 9: 772–780.
- LUNA, L. G. 1992. Histopathologic methods and color atlas of special stains and tissue artifacts. Johnson Printers, Downers Grove, Illinois, 767 pp.
- MAHONY, M. C., AND G. D. HODGEN. 1995. Toxic effects on the hypothalamus-anterior pituitary-gonadal axis. Control of the male and female reproductive system, and related issues. *In* Reproductive toxicology, 2nd ed., R. J. Witorsch (ed.). Raven Press, New York, New York, pp. 195–213.
- MARKS, T. A., G. L. KIMMEL, AND R. E. STAPLES. 1989. Influence of symmetrical polychlorinated biphenyl isomers on embryo and fetal development in mice. *Fundamental and Applied Toxicology* 13: 681–693.
- MARSH, H., AND T. KASUYA. 1984. Changes in the ovaries of the short-finned pilot whale, *Globicephala macrorhynchus*, with age and reproductive activity. Report of the International Whaling Commission 6: 311–335.
- MARSHALL, F. H. A. 1984. Marshall's physiology of reproduction, Vol. 1, 4th ed. Churchill Livingstone Publisher, New York, New York, pp. 544–553.
- MCENTEE, K. 1990. Reproductive pathology of domestic mammals. Academic Press, Inc., San Diego, California, 401 pp.
- MOBERG, G. P. 1985. Influence of stress on reproduction: Measure of well-being. *In* Animal stress, G. P. Moberg (ed.). American Physiological Society, Bethesda, Maryland, pp. 245–267.
- REIJNERS, P. J. 1980. Organochlorine and heavy metal residues in harbour seals from the Wadden Sea and their possible effects on reproduction. *The Netherlands Journal of Sea Research* 14: 30–65.
- THOMAS, P. 1990. Teleost model for studying the effects of chemicals on female reproductive function. *Journal of Experimental Zoology* 4: 126–128.
- TRUDGETT, A., C. LYONS, M. J. WELSH, N. DUFFY, S. J. MCCULLOUGH, AND F. MCNEILLY. 1991. Analysis of a seal and a porpoise morbillivirus using monoclonal antibodies. *Veterinary Record* 128: 61.
- VAN LENNEP, E. W. 1950. Histology of the corpora lutea in blue and fin whale ovaries. *Koninklijke Nederlandse Akademie van Wetenschappen* 53: 593–599.
- YOUNGQUIST, R. S. 1986. Cystic follicular degeneration in the cow. *In* Current therapy in theriogenology 2, 2nd ed., D. A. Morrow (ed.). W. B. Saunders Co., Philadelphia, Pennsylvania, pp. 243–246.

Received for publication 27 August 1996.