

## **Uterine Adenocarcinoma in a Captive Sika Deer**

Authors: Robert, N., and Posthaus, H.

Source: Journal of Wildlife Diseases, 35(1) : 141-144

Published By: Wildlife Disease Association

URL: <https://doi.org/10.7589/0090-3558-35.1.141>

---

The BioOne Digital Library (<https://bioone.org/>) provides worldwide distribution for more than 580 journals and eBooks from BioOne's community of over 150 nonprofit societies, research institutions, and university presses in the biological, ecological, and environmental sciences. The BioOne Digital Library encompasses the flagship aggregation BioOne Complete (<https://bioone.org/subscribe>), the BioOne Complete Archive (<https://bioone.org/archive>), and the BioOne eBooks program offerings ESA eBook Collection (<https://bioone.org/esa-ebooks>) and CSIRO Publishing BioSelect Collection (<https://bioone.org/csiro-ebooks>).

Your use of this PDF, the BioOne Digital Library, and all posted and associated content indicates your acceptance of BioOne's Terms of Use, available at [www.bioone.org/terms-of-use](http://www.bioone.org/terms-of-use).

Usage of BioOne Digital Library content is strictly limited to personal, educational, and non-commercial use. Commercial inquiries or rights and permissions requests should be directed to the individual publisher as copyright holder.

---

BioOne is an innovative nonprofit that sees sustainable scholarly publishing as an inherently collaborative enterprise connecting authors, nonprofit publishers, academic institutions, research libraries, and research funders in the common goal of maximizing access to critical research.

## Uterine Adenocarcinoma in a Captive Sika Deer

N. Robert<sup>1</sup> and H. Posthaus,<sup>1,2</sup> <sup>1</sup>Institute for Animal Pathology, Berne University, P.O. Box 2735, 3001 Berne, Switzerland; <sup>2</sup>Corresponding author (e-mail: posthaus@itpa.unibe.ch).

**ABSTRACT:** A uterine adenocarcinoma with widespread visceral implantation and lymphatic metastases is described in a 4-yr-old captive nulliparous sika deer (*Cervus nippon*). The tumor was histologically characterized by proliferation of irregularly shaped acini and tubules lined by single- or multi-layered pleomorphic epithelial cells, which were sometimes multinucleated and contained PAS positive mucin. The neoplastic tissue was invasive and showed a marked desmoplastic reaction. A relationship between the tumor and a hormonal imbalance could not be ruled out. This is the first report of a tumor of the reproductive tract in a cervid.

**Key words:** Adenocarcinoma, case report, *Cervus nippon*, sika deer, uterus.

Uterine adenocarcinoma is primarily a human neoplasm and is rarely described in animals, except in older rabbits and in cattle (Elsinghorst et al., 1984; McEntee, 1990; Kennedy and Miller, 1993). In the cow, it is rarely identified clinically, being found usually in slaughtered cows at abattoirs. Most affected cows are  $\geq 6$ -yr-old, but uterine neoplasms are occasionally found in 2- to 5-yr-old animals (Migaki et al., 1970). Tumors of the female genital system are rarely reported in wild ungulates: an uterine adenocarcinoma in a black rhinoceros (*Diceros bicornis*) (Wallach and Boever, 1983), a squamous cell carcinoma of the cervix in a blackbuck (*Antelope cervicapra*) (Sundberg and McDonald, 1984), and a metastatic adenocarcinoma of the mammary gland in a Pere David's deer (*Elaphurus davidianus*) (Veatch and Carpenter, 1993) have been described, but no reports of neoplasms of the reproductive tract in cervids were found. There is a single report of a squamous cell carcinoma of the skin in a sika deer (*Cervus nippon*) (Ensley and Janssen, 1980). Herein we report a case of an uterine adenocarcinoma in a sika deer.

A captive 4-yr-old female sika deer died at the Tierpark Roggenhausen (Switzer-

land; 46°57'N, 70°26'E) after being observed to have a decreased appetite for the previous few months. Mucous secretion from the vagina also had been noticed. This deer had never produced any offspring. It was slightly emaciated and weighed 53 kg.

At necropsy a large amount of serosanguinous liquid with some fibrin was present in both the abdominal and the thoracic cavity. The uterine body and the proximal part of both horns were massively, irregularly thickened and were adherent to the mesometrium and adjacent peritoneum. The thickness of the uterine wall decreased towards the distal end of the horns. The lumina of the uterine horns were slightly dilated and contained a cloudy yellow mucus. The thickened uterus was firm and the cut surface was mottled gray to yellow with multiple small hemorrhagic foci. Scirrhous neoplastic tissue infiltrated all layers of the uterine wall. Multiple ulcerations were visible on the endometrial surface of the left horn.

Irregular multinodular neoplastic proliferations, partly coalescing and varying in size from few millimeters up to 5 cm in diameter, were scattered throughout the parietal and visceral pleura and peritoneum, omentum and mesentery. The peritoneal surfaces in the vicinity of the uterus were most extensively affected. These metastases were similar to the proliferative tissue in the uterus in consistency and color. On the cut surface, these neoplastic lesions were seen to infiltrate into the lung, liver and spleen, and into the muscle layers of the fore stomachs and the diaphragm. Multinodular lesions also were growing throughout the wall of the urinary bladder causing a compression of the vesicular hilus. The medial iliac and sacral lymph nodes, and the cranial sternal

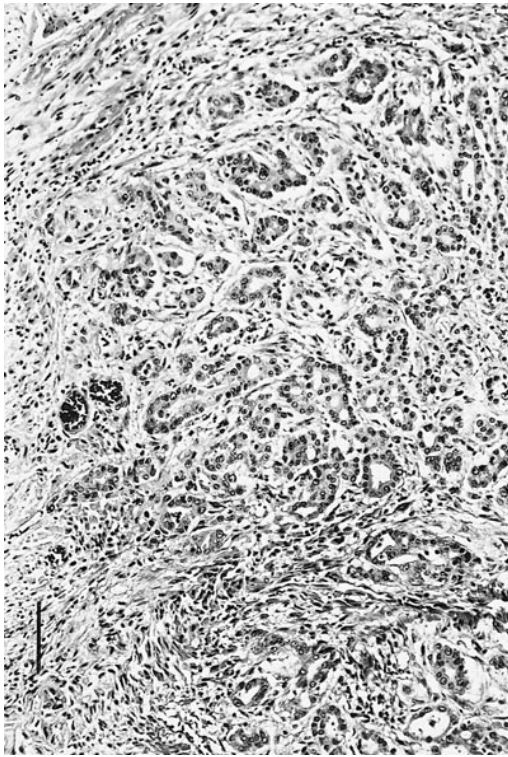


FIGURE 1. Neoplastic tissue in the endometrium of a sika deer with uterine adenocarcinoma showing loss of regular glandular architecture and proliferation of irregular shaped acini and tubules. H&E. Bar = 24  $\mu$ m.

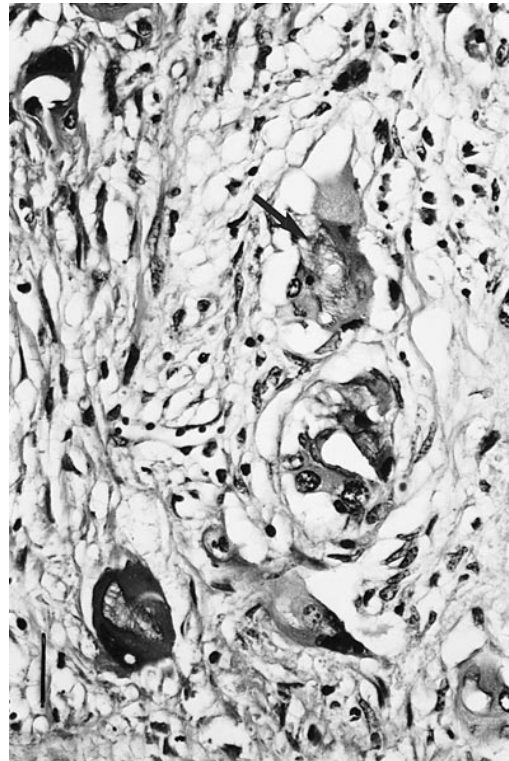


FIGURE 2. Pleomorphic neoplastic cells with mucin production ( $\uparrow$ ) and pleomorphic vesicular nuclei of the uterus in a sika deer with adenocarcinoma. H&E. Bar = 30  $\mu$ m.

lymph node were irregularly enlarged with roughened to nodular surfaces.

Various tissues, including uterus, ovaries, urinary bladder, and lymph nodes, were fixed in 10% neutral buffered formalin, embedded in paraffin, sectioned at 4  $\mu$ m and stained with hematoxylin and eosin, periodic-acid-Shiff and Van Gieson's stains (Böck, 1989). Histologically, the normal endometrial glands had a regular glandular structure and were lined by single layers of columnar epithelial cells with basal nuclei. In the neoplastic tissue the regular glandular architecture was lost and there was a proliferation of irregularly shaped acini and tubules which varied considerably in size (Fig. 1). The lumina of these neoplastic glands were sometimes considerably enlarged and contained cellular debris or PAS positive mucin. Glandular

lumina were lined most often by irregular single-layered cuboidal or columnar cells but the epithelium sometimes appeared multi-layered and displayed multinucleated cells. The neoplastic cells were variably large and pleomorphic with abundant cytoplasm and sometimes contained PAS positive mucin (Fig. 2). The nuclei were large, pleomorphic and vesicular, and some contained one or more prominent nucleoli. Mitotic figures were not numerous. Invasive nests and cords of poorly differentiated glandular structures extended through the myometrium and were surrounded by collagenous connective tissue (Fig. 3) with multifocal calcifications. Metastatic emboli were seen in the blood and lymphatic vessels in the perimetrium. The metastatic lesions were morphologically similar to the uterine tumors, were highly invasive into the sur-



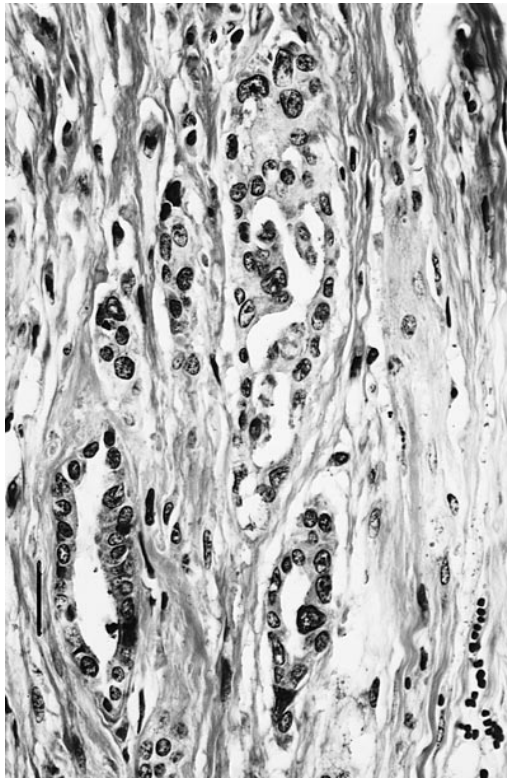


FIGURE 3. Invasive nests and cords of poorly differentiated glandular structures in the myometrium of the uterus in a sika deer with uterine adenocarcinoma. H&E. Bar = 30  $\mu$ m.

rounding parenchyma, were poorly demarcated and were accompanied by an abundant collagenous stroma.

Histology of the ovaries revealed the presence of few primary follicles in both glands, a mature tertiary follicle and atretic follicles on one side, and a corpus luteum on the other side.

Based on the extensive involvement of the uterus and the histological findings, the neoplasm was diagnosed as a primary adenocarcinoma of the uterus with multiple implantation sites and lymphatic metastases. The gross appearance of the tumor and the distribution of the metastases in the sika deer are comparable to those described in the cows. In cows, most uterine adenocarcinomas are found in the horns or body and are usually solitary. These tumors seem to arise from the deep

endometrial glands, invade the myometrium and perimetrium, and tend to have an extensive desmoplastic reaction. Both metastases via lymphatics and implantation metastases on the peritoneal surfaces, especially near the uterus, are frequently described (Migaki et al., 1970).

In women, uterine adenocarcinomas often develop on a background of prolonged oestrogen stimulation and may be related to obesity and anovulatory cycles (Crum, 1994). This relation between sex hormones, especially oestrogens, and endometrial carcinoma also is described in the rabbit (Elsinghorst et al., 1984). In the study of uterine adenocarcinoma in slaughtered cows reported by Migaki (1970), there is no description of the ovaries of the affected cows and no mention about a possible hormonal pathogenesis of the uterine neoplasms. The ovaries in the sika deer showed various stages of follicular development; however, a hormonal imbalance can not be ruled out. First breeding age in captive female sika deer is reached in the second year of life but this animal never produced any offspring. Due to the extensive involvement of the uterus, it seems obvious that the tumor was causing infertility. However the question about a possible primary hormonal imbalance as a predisposition to the development of the adenocarcinoma can not be answered.

#### LITERATURE CITED

- BÖCK, P. 1989. *Romeis mikroskopische Technik*. 17th Edition. Urban und Schwarzenberg, München, Germany, 697 pp.
- CRUM, C. P. 1994. Female genital tract. In Robbins pathologic basis of disease, 5th Edition. R. S. Cotran, V. Kumar, and S. L. Robbins (eds.). W.B. Saunders Company, Philadelphia, Pennsylvania, pp. 1033–1088.
- ELSINGHORST, T. A., H. J. TIMMERMAN, AND H. G. HENDRICKS. 1984. Comparative pathology of endometrial carcinoma. *The Veterinary Quarterly* 6: 200–208.
- ENSLEY, P. K., AND D. L. JANSSEN. 1980. Squamous cell carcinoma in an Indochina sika deer. *Journal of the American Veterinary Medical Association* 177: 932.
- KENNEDY, P. C., AND R. B. MILLER. 1993. The female genital system. In *Pathology of domestic*

- animals. 4th ed., K. V. F. Jubb, P. C. Kennedy, and N. Palmer (eds.). Academic Press, Inc., San Diego, California, pp. 349–470.
- MCENTEE, K. 1990. Reproductive pathology of domestic mammals. Academic Press, Inc., San Diego, California, 401 pp.
- MIGAKI, G., A. M. CAREY, R. U. TURNQUEST, AND F. M. GARNER. 1970. Pathology of bovine uterine adenocarcinoma. *Journal of the American Veterinary Medical Association* 157: 1577–1584.
- SUNDBERG, J. P., AND S. E. McDONALD. 1984. Squamous cell carcinoma of the cervix in a blackbuck. *Journal of the American Veterinary Medical Association* 185: 1445–1446.
- VEATCH, J. K., AND J. W. CARPENTER. 1993. Metastatic adenocarcinoma of the mammary gland in a Pere David's deer. *Journal of Veterinary Diagnostic Investigation* 5: 639–640.
- WALLACH, J. D., AND W. J. BOEVER. 1983. Perissodactyla, Proboscidae and Hippopotamidae. *In* Diseases of exotic animals: Medical and surgical management, J. D. Wallach, and W. J. Boever (eds.). W.B. Saunders Company, Philadelphia, Pennsylvania, pp. 814–815.

*Received for publication 1 February 1998*