BioOne COMPLETE

ATRIAL SEPTAL DEFECTS IN FLORIDA PANTHERS

Authors: Cunningham, Mark W., Dunbar, Mike R., Buergelt, Claus D., Homer, Bruce L., Roelke-Parker, Melody E., et al.

Source: Journal of Wildlife Diseases, 35(3) : 519-530

Published By: Wildlife Disease Association

URL: https://doi.org/10.7589/0090-3558-35.3.519

BioOne Complete (complete.BioOne.org) is a full-text database of 200 subscribed and open-access titles in the biological, ecological, and environmental sciences published by nonprofit societies, associations, museums, institutions, and presses.

Your use of this PDF, the BioOne Complete website, and all posted and associated content indicates your acceptance of BioOne's Terms of Use, available at www.bioone.org/terms-of-use.

Usage of BioOne Complete content is strictly limited to personal, educational, and non - commercial use. Commercial inquiries or rights and permissions requests should be directed to the individual publisher as copyright holder.

BioOne sees sustainable scholarly publishing as an inherently collaborative enterprise connecting authors, nonprofit publishers, academic institutions, research libraries, and research funders in the common goal of maximizing access to critical research.

Downloaded From: https://complete.bioone.org/journals/Journal-of-Wildlife-Diseases on 19 Apr 2024
Terms of Use: https://complete.bioone.org/terms-of-use

Journal of Wildlife Diseases, 35(3), 1999, p. 519–530
© Wildlife Disease Association 1999

ATRIAL SEPTAL DEFECTS IN FLORIDA PANTHERS

Mark W. Cunningham,[1,3,9] Mike R. Dunbar,[1,2] Claus D. Buergelt,[3] Bruce L. Homer,[3] Melody E. Roelke-Parker,[1,4] Sharon K. Taylor,[5] Robert King,[6] Scott B. Citino,[7] and Carolyn Glass[1,8]

[1] Florida Game and Fresh Water Fish Commission, Wildlife Research Laboratory, 4005 South Main Street, Gainesville, Florida 32601, USA
[2] Present address: U.S. Fish and Wildlife Service, Sheldon-Hart Mountain Refuge Complex, P.O. Box 111, Lakeview, Oregon 97630, USA
[3] Department of Pathobiology, College of Veterinary Medicine, University of Florida, Gainesville, Florida 32611, USA
[4] Present address: National Cancer Institute, Laboratory of Genomic Diversity, Box B, Frederick, Maryland 21702, USA
[5] Florida Game and Fresh Water Fish Commission, 566 Commercial Boulevard, Naples, Florida 34104, USA
[6] Department of Small Animal Clinical Sciences, College of Veterinary Medicine, University of Florida, Box 100-126, Gainesville, Florida 32611, USA
[7] White Oak Conservation Center, 3823 Owens Road, Yulee, Florida 32097, USA
[8] Deceased
[9] Corresponding author (e-mail: markwc@nersp.nerdc.ufl.edu)

ABSTRACT: Ostium secundum atrial septal defects (ASDs) were observed in six (3 M, 3 F) of 33 (20 M, 13 F) (18%) Florida panthers (*Puma concolor coryi*) necropsied by veterinary pathologists between 1985 and 1998. A seventh ASD was found in a female panther necropsied in the field and is included in the pathological description but not the prevalence of ASDs in Florida panthers. One panther (FP205) with severe ASD also had tricuspid valve dysplasia (TVD). Atrial septal defects and/or TVD are believed to have caused or contributed to the deaths of three (9%) Florida panthers in this study. Mean diameter ± SD of ASDs was 9.0 ± 4.7 mm (range 3 to 15 mm). Gross pathological changes attributed to ASDs/TVD in severely affected panthers (ASD ≥ 10 mm) (n = 4) included mild right ventricular dilatation (n = 3) and hypertrophy (n = 2), mild to severe right atrial dilatation (n = 2), and acute pulmonary edema (n = 3). Panthers with mild ASDs (ASD ≤ 5 mm) (n = 3) had no other detectable gross pathological changes associated with the ASDs. Histological examination of lungs of three panthers with severe ASDs revealed mild to moderate dilatation with fibrosis and smooth muscle atrophy of the tunica media of medium to large caliber arteries (n = 2), interstitial and/or pleural fibrosis (n = 2), perivascular fibrosis (n = 1), and acute to chronic edema (n = 3). Twenty-six necropsied panthers were examined one or more times while living; medical records were retrospectively evaluated. Antemortem radiographic, electrocardiographic, and echocardiographic examinations were performed on two panthers with severe ASDs (FP20 and FP205). Thoracic radiographic abnormalities in both included right heart enlargement, and in FP205 (severe ASD and TVD), mild pulmonary overperfusion. Electrocardiographic examination of FP205 revealed a right ventricular hypertrophy pattern, while FP205 had a normal electrocardiogram. Echocardiographic examination of FP20 revealed marked right atrial dilatation; a bubble contrast study indicated regurgitation across the tricuspid valve. Echocardiographic abnormalities in FP20 included right atrial and ventricular dilatation, atrial septal drop-out, and severe tricuspid regurgitation; non-selective angiography revealed significant left to right shunting across the ASD. All panthers with severe ASDs ausculted (n = 3) had systolic right or left-sided grade I–V/VI murmurs loudest at the heart base. All male panthers with ASDs (n = 3) (100%) and 9 of 17 (53%) male panthers without ASDs in this study were cryptorchid.

Key words: Atrial septal defect, cardiac measurements, cougar, felid, *Puma concolor coryi*, Florida panther, heart murmur, ostium secundum, pathology, puma, tricuspid valve dysplasia.

INTRODUCTION

The Florida panther (*Puma concolor coryi*) is an endangered subspecies of cougar numbering 30 to 50 individuals inhabiting the Big Cypress and Everglades ecosystems of southern Florida (USA) (Belden, 1986). This isolated population has a low genetic diversity (O'Brien et al., 1990) and is subject to inbreeding (Roelke et al., 1993; Maehr, 1997), the consequences of which are believed to include poor seminal traits (Barone et al., 1994), cryptorchidism, and atrial septal defects (ASDs) (Roelke et al., 1993). Roelke et al. (1993) reported that ASDs caused the deaths of two Florida panthers.

Without intervention the Florida panther was predicted to become extinct with-

Downloaded From: https://complete.bioone.org/journals/Journal-of-Wildlife-Diseases on 19 Apr 2024
Terms of Use: https://complete.bioone.org/terms-of-use

in 25 to 40 yr (Seal and Lacy, 1989). However, in 1995 eight female cougars (*P. concolor stanlyana*) from Texas (USA) were released into southern Florida as part of a genetic restoration program (Seal, 1994). The resultant introgression was designed to restore the genetic diversity to levels comparable to other North American *P. concolor* subspecies and to lower the incidence of congenital anomalies in the panther population. Baseline data collected from panthers prior to introgression will assist researchers in evaluating the recent genetic introgression (Dunbar et al., 1997). The objective of this retrospective study was to describe the pre-introgression prevalence, pathology, and clinical signs of ASDs in Florida panthers and to examine methods for the diagnosis of ASD in the field.

METHODS AND MATERIALS

Thirty-three (20 male [M], 13 female [F]) of 77 Florida panther carcasses collected from peninsular southern Florida (south of 27°00′N) or captive locations between October 1985 and December 1998 were completely necropsied by veterinary pathologists. An additional free-ranging Florida panther (PCO192) that had an ASD but was incompletely necropsied, was included in the pathological description of ASD but not the prevalence calculation. Other Florida panthers necropsied in the field (for which records are incomplete) were not included in this study. Of 28 free-ranging Florida panthers necropsied by pathologists (including PCO192), 20 had been radio-instrumented and were collected upon detection of a mortality signal. Seven free-ranging panthers not radio-instrumented died of vehicular trauma and were collected opportunistically from the roadside; one neonatal kitten was found dead outside a den site. Of six captive panthers necropsied, four were initially captured at 6 mo to 1 yr of age as part of a captive breeding program, and two were captured following vehicular collision and were unreleasable due to injuries. Captive panthers were held at White Oak Conservation Center (WOCC; Yulee, Florida) and duration of captivity was 1 to 10 yr. Necropsies were performed at the University of Florida Veterinary Medical Teaching Hospital (VMTH; Gainesville, Florida) (n = 31), Southeastern Cooperative Wildlife Disease Study (SCWDS; College of Veterinary Medicine, University of Georgia, Athens, Georgia, USA) (n = 1), and University of Miami (UM; Comparative Pathology Laboratory, Miami, Florida) (n = 1). PCO192 was necropsied in the field and the intact heart was examined by a pathologist at VMTH. For histologic examination, multiple tissues, including heart, lung, liver, kidney, spleen, and brain from three panthers with severe ASD's (PCO192, FP20, and FP205) were fixed in 10% neutral buffered formalin, embedded in paraffin, sectioned at 5 to 6 μm and stained with hematoxylin and eosin. Additionally, sections of lung were stained using Masson's trichrome and Verhoeff-Van Gieson techniques for detection of collagen, smooth muscle cells and elastin fibers (Luna, 1968). For this study, ASDs ≥ 10 mm diameter were considered severe, ≤5 mm mild. Degree of gross cardiac hypertrophy and dilatation was determined subjectively by the pathologist. Where data were available, diagnoses were also supported by retrospective evaluation of heart weight, thickness of the left and right ventricular free walls, and the circumferences of the heart valves based on published criteria (Liu, 1983; Turk et al., 1983). The following cardiac measurements were recorded for panthers with severe ASDs: right (RVT) and left ventricular free wall thickness (LVT) (FP's 20, 47, and 205); pulmonic (P) and aortic valve circumference (A), right (RAV) and left atrioventricular valve circumference (LAV) (FP20 and FP205); and heart weight (HW) (FP20). These measurements were also recorded for panthers with mild ASDs. Cardiac measurements for panthers without ASDs depicted in Table 1 (n =

TABLE 1. Ratios of cardiac parameters in adult and juvenile (age ≥ 6 mo) Florida panthers (n = 13) without atrial septal defects necropsied 1985–1998.

	Mean	SD[a]
HW/BW[b]	4.85	0.93
A/P[c]	0.97	0.17
A/LAV[d]	0.62	0.24
A/RAV[e]	0.51	0.14
P/LAV	0.67	0.24
P/RAV	0.55	0.18
LAV/RAV	0.85	0.16
LVT/RVT[f]	2.89	0.59

[a] Standard Deviation.
[b] Heart weight (g)/Body weight (kg), n = 14.
[c] Aortic valve circumference (A)/pulmonic valve circumference (P).
[d] Left atrioventricular valve circumference (LAV).
[e] Right atrioventricular valve circumference (RAV).
[f] Left ventricular thickness/right ventricular thickness.
[g] LVT = left ventricular thickness.
[h] RVT = right ventricular thickness.

Downloaded From: https://complete.bioone.org/journals/Journal-of-Wildlife-Diseases on 19 Apr 2024
Terms of Use: https://complete.bioone.org/terms-of-use

13) ranged in age from 6 mo to 14 yr ($\bar{x} \pm SD = 5.7 \pm 4.0$ yr) and body weight from 11.8 to 59 kg ($\bar{x} \pm SD = 39.8 \pm 13.3$ kg). Florida panthers whose hearts were not examined by a pathologist and/or whose carcass condition did not allow thorough gross examination were not included in this study. Carcass condition ranged from fresh to moderately autolyzed. No cougars introduced as part of the genetic restoration program or their progeny were included in this study.

Free-ranging panthers were captured using techniques described by Maehr et al. (1991) and McCown et al. (1990) and anesthetized with ketamine hydrochloride (Ketaset®, Fort Dodge Laboratories, Inc., Fort Dodge, Iowa, USA) and tiletamine hydrochloride and zolazepam hydrochloride (Telazol®, Fort Dodge Laboratories, Inc.) at approximate initial dosages of 9 mg/kg (range = 7–9 mg/kg) and 2 mg/kg (range = 0.9–2 mg/kg) respectively (Roelke, 1990; S. Taylor, unpubl.). Drug dosages were based on estimated weights, body condition, and capture conditions. Captive panthers were similarly immobilized, then intubated and maintained on isoflurane (AErrane®, Anaquest, Madison, Wisconsin, USA) or halothane (Halocarbon Laboratories, River Edge, New Jersey, USA). Sedatives occasionally used in free-ranging and captive panthers during anesthesia included midazolam (Versed®, Roche Laboratories, Mutely, New Jersey) and diazepam (Valium®, Roche Laboratories).

Medical records of panthers necropsied in this study were retrospectively evaluated for results of radiographic, electrocardiographic, echocardiographic, and auscultatory examinations. Radiographic (thorax), electrocardiographic, and echocardiographic examinations of FP20 and FP205 were performed at Miami Metro-Zoo (MMZ; Miami) and VMTH respectively. Non-selective angiography of FP205 was also performed at VMTH (M. Roelke, R. King, and J. A. Abbott, unpubl.). Cardiac auscultation was performed on one or more occasions and results were recorded for 15 of 27 panthers without ASDs, all panthers with mild ASDs, and three of four panthers with severe ASDs. Panthers were auscultated under field conditions only ($n = 13$), hospital conditions only ($n = 3$), and both field and hospital conditions ($n = 5$). Auscultations were performed by veterinarians of the Florida Game and Fresh Water Fish Commission (FGFWFC; Gainesville, Florida), MMZ, WOCC, and VMTH. Murmur intensities were graded from I (least severe) to VI (most severe) (Ware, 1995). Panthers were ausculted when in right or left lateral recumbency. Multiple auscultations were performed during anesthesia although times were not recorded.

The scrotal and inguinal areas of males were palpated (live animals) or dissected (at necropsy) to determine the number of descended testes. Males presenting with either 1 or 2 undescended testes were considered to be cryptorchid.

Genetic analysis of 26 of the 33 examined panthers was determined by mitochondrial DNA restriction fragment length polymorphism (mtDNA RFLP) ($n = 26$), allozyme electrophoresis ($n = 25$), and minisatellite analysis (also known as DNA fingerprints) ($n = 16$) as described by O'Brien et al. (1990) and Roelke et al. (1993). These analyses utilized soluble proteins and/or DNA extracted from leukocytes, erythrocytes, fibroblast tissue culture, or organs which were obtained from panthers at capture or necropsy. Signature alleles (for allozymes and mtDNA RFLP) and minisatellite banding patterns were used to determine whether the individual was an 'authentic' Florida panther or showed evidence of hybridization with a Central or South American puma (integrade) (O'Brien et al. 1990). The mitochondrial haplotype of all seven panthers with ASDs and 19 panthers without ASDs also was determined (the maternally inherited mtDNA haplotype partially defines hybrid status). Allozyme analysis which included the loci informative of hybridization (APRT) was performed on six of the seven panthers with ASDs (FPs 12, 20, 38, 47, 52, and 205) and 19 of the remaining 27 panthers without ASDs. Minisatellite diversity was determined for four of seven panthers with ASDs (FP's 12, 20, 38, and 205) and 12 of 24 panthers without ASDs.

A Fisher's exact test was used to examine the distribution of panthers with and without ASDs with respect to their ancestry and prevalence of cryptorchidism (SAS Institute, Inc., 1990). Differences were considered significant if $P \leq 0.05$.

RESULTS

Brief case histories of panthers with severe ASDs are as follows. FP20 (M) was hospitalized at MMZ for approximately 2 mo following vehicular trauma. A cardiac murmur was detected and the heart subsequently evaluated while in captivity. Approximately 1 yr after release, radio-telemetry data indicated the panther to be in the same location for at least 2 days. Biologists were able to approach to within 2 m before the panther moved off; the panther

Downloaded From: https://complete.bioone.org/journals/Journal-of-Wildlife-Diseases on 19 Apr 2024
Terms of Use: https://complete.bioone.org/terms-of-use

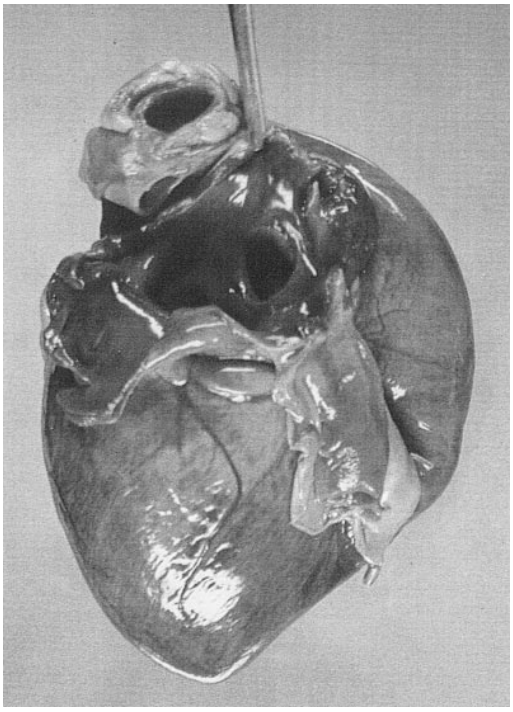

FIGURE 1. A 15 mm atrial septal defect in a Florida panther.

was found dead the next day. During captivity FP20 had severely damaged his canine teeth which may have hindered his ability to capture prey; his weight dropped from 63 to 48 kg between release and death (Roelke, 1990). FP205 (F) had a severe heart murmur when captured as a juvenile for captive breeding. Surgery was performed at VMTH approximately 1.5 yr later to correct the ASD; however, the panther died immediately following surgery. FP47 (M) (Fig. 1) was a juvenile that is believed to have died of cardiac failure during a fight with an adult male panther. Necropsy revealed that the wounds sustained during the fight were extensive but relatively superficial and were not believed to have contributed to his death. PCO192 (F) died of vehicular trauma.

Ostium secundum ASDs were observed in six (3 M, 3 F) of 33 (18%) Florida panthers necropsied at VMTH, SCWDS, or UM. A seventh panther (F) with severe ASD was necropsied in the field. One panther with a severe ASD (FP205) also had tricuspid valve dysplasia (TVD). Severe ASDs (FPs 20, 47, 205) and TVD (FP205) are believed to have caused or contributed to the deaths of three panthers (9% of panthers completely necropsied). Three ASDs were mild with a $\bar{x} \pm$ SD diameter of 4.0 ± 0.8 mm (range = 3 to 5 mm) and four severe ($\bar{x}$ = 12.75 ± 2.3, range = 10 to 15 mm). Mean diameter for severe and mild ASDs combined was 9.0 ± 4.7 mm. Sex, age, ASD diameter, and major gross and microscopic changes for panthers with ASDs are listed in Table 2. Ratios of cardiac parameters from panthers without ASDs are listed in Table 1. In three of four panthers with severe ASDs, there was gross evidence supporting subjective diagnoses of mild right ventricular dilatation (FPs 20, 47, 205) and mild to severe right atrial dilatation (FP47, FP205). In FP20 and FP47 the RVT was 0.30 cm compared to a mean thickness of 0.46 ± SD 0.06 cm for panthers without ASD; the LVT/RVT ratio was 4.33 and 3.33 respectively, compared to a mean LVT/RVT ratio of 2.89 ± SD 0.59 for panthers without ASDs. Additionally, the LAV/RAV ratios for FP20 and FP205 were 0.62 and 0.55 respectively compared to a mean LAV/RAV ratio of 0.85 ± SD 0.16 for panthers without ASDs. Finally, the A/P ratio for FP20 was 0.5, compared to a mean of 0.97 ± SD 0.17 in panthers without ASDs. FP205 (severe ASD and TVD) also had evidence of right ventricular hypertrophy with a RVT of 0.6 cm. Panthers with mild ASDs had no other gross pathological changes due to cardiac abnormalities.

Lungs from three panthers (PCO192, FP20, FP47) were wet and gelatinous (edematous). Several pathologic changes were noted in lungs of the three panthers examined histologically (Table 2). These changes included dilatation of medium to large caliber arteries, associated with variable replacement of smooth muscle of the tunica media with fibrous connective tissue and an increased prominence and disarray of elastin fibers (PCO192, FP20). In

Downloaded From: https://complete.bioone.org/journals/Journal-of-Wildlife-Diseases on 19 Apr 2024
Terms of Use: https://complete.bioone.org/terms-of-use

TABLE 2. Sex, age, atrial septal defect (ASD) diameter, and synopsis of gross and microscopic pathology of Florida panthers with atrial septal defects 1985–1998.

					Gross pathology			Microscopic pathology—lung			
Degree of ASD	Panther	Sex	Age[a] (yr)	ASD diameter (mm)	Pulmonary edema	Right cardiac ventricular dilatation	Right cardiac atrial dilatation	Edema	Arterial medial atrophy and fibrosis	Interstitial fibrosis	Pleural fibrosis
Mild	12	M	12.5	5	no	no	no	ND[b]	ND	ND	ND
	38	F	8	3	no	no	no	ND	ND	ND	ND
	52	F	3.5	4	no	no	no	ND	ND	ND	ND
Severe	PCO192[c]	F	0.75	15	moderate	no	no	moderate	mild, multifocal	no	moderate
	20[d]	M	5	11	moderate	mild	no	moderate	moderate	no	no
	47	M	1.5	15	moderate	mild	mild	ND	ND	ND	ND
	205[e]	F	2	10	no	mild	severe	moderate	no	mild[f]	moderate

[a] Age at death.
[b] Histopathology not performed.
[c] Not examined while living.
[d] Also had microscopic evidence of acute, locally extensive pulmonary hemorrhage.
[e] Captive since 9-mo of age; also had tricuspid valve dysplasia and microscopic evidence of acute marked hepatic congestion.
[f] Associated with mild perivascular fibrosis.

one panther with pulmonary interstitial fibrosis (FP205), there was a mild increase in collagen around medium to large caliber arteries and veins. There was also mild alveolar histiocytosis and the stroma around large vessels and bronchioles was loosely arranged, indicative of subacute to chronic edema. FP20 had evidence of acute, locally extensive pulmonary hemorrhage. In panthers with gross evidence of pulmonary edema (PCO192, FP20), the alveoli contained amorphous eosinophilic material. In right ventricular myocardial fibers of FP205, there were one or two variably sized discrete cytoplasmic vacuoles, a mild increase in the diameter of scattered myofibers, and mild multifocal karyomegaly and brick-shaped nuclei. FP205 also had acute marked centrilobular to midzonal hepatic congestion with mild to moderate individual hepatocellular necrosis.

Mean ± SD age at death for panthers without ASDs, with mild ASDs, and with severe ASDs was 5.5 ± 4.0, 8.0 ± 3.7, and 2.3 ± 1.6 yr, respectively. The ages of the two free-ranging panthers which died as a result of ASDs were 1.5 (FP47) and 5 (FP20) yr. With the exception of FP20, body weights for panthers with severe ASDs were within normal limits for their respective age class (D. Land, unpubl.).

Thoracic radiographic abnormalities in FP20 and FP205 included right heart enlargement, and in FP205, mild pulmonary overperfusion. Electrocardiographic findings in FP20 included a right ventricular hypertrophy pattern with right axis deviation (+260°) and a normal sinus rhythm, and in FP205, a normal sinus rhythm with no axis abnormalities. Echocardiography in FP20 revealed severe right atrial dilatation and a bubble contrast study indicated regurgitation across the tricuspid valve (M. Roelke and R. King, unpubl.). Echocardiographic abnormalities in FP205 included severe right atrial and moderate right ventricular dilatation, atrial septal drop-out, and severe tricuspid regurgitation. Non-selective angiography in the same panther

Downloaded From: https://complete.bioone.org/journals/Journal-of-Wildlife-Diseases on 19 Apr 2024
Terms of Use: https://complete.bioone.org/terms-of-use

revealed substantial left-to-right shunting (M. Roelke, R. King, and J. A. Abbott, unpubl.).

The detection of heart murmurs varied with the examining veterinarian, field conditions, and presence of other cardiac anomalies. Heart murmurs ranging in grade from I–V/VI were detected in 13 of 21 (62%) Florida panthers ausculted in this study. Eight of 15 (53%) panthers without ASDs or other known cardiac disease ausculted had systolic, primarily right-sided, grade I–II/VI murmurs. Two of three (67%) panthers with mild ASDs ausculted had systolic right-sided grade I–II/VI murmurs. All panthers with severe ASDs ausculted (n = 3) had systolic right or left-sided grade I–V/VI murmurs, loudest at the heart base. One of these (FP47) had a gallop rhythm when auscultated in the field at 6 mo of age, but not at 18 mo when ausculted by a different veterinarian. FP205 (severe ASD and TVD) had a holosystolic grade IV–V/VI murmur, loudest on the right side and FP20 (severe ASD and evidence of tricuspid insufficiency on echocardiographic exam) had a II–III/VI systolic ejection murmur loudest at the right or left heart base (depending on the examining veterinarian). Fourteen panthers (including PCO192) in this study were not ausculted or results were not recorded. There were no panthers in this study with evidence of heart disease other than that already described.

All male panthers with ASDs and nine of 17 (53%) male panthers without ASDs were cryptorchid; however, the difference in prevalence of cryptorchidism was not significant.

All panthers with ASDs had no evidence of subspecies hybridization based on mtDNA RFLP, allozyme APRT loci, and minisatellite diversity (considered 'authentic'). Genotyping of PCO192 was based solely on mtDNA. Among the 27 unaffected animals, 15 were 'authentic' panthers, four were intergrades, and eight were not analyzed (O'Brien et al., 1990; Roelke, 1990; Roelke et al., 1993; M. Roelke and S. O'Brien unpubl. data). There was no significant difference in the prevalence of ASDs among these categories.

DISCUSSION

Abnormal embryological development of the interatrial septum may result in three types of true ASDs: ostium secundum, ostium primum, and sinus venosus (Hamlin et al., 1963). These defects are differentiated by location with ostium secundum ASDs at or near the fossa ovalis, ostium primum ASDs low in the interatrial septum immediately adjacent to the atrioventricular valves, and sinus venosus ASDs dorsal and cranial to the fossa ovalis. Ostium secundum is the most common type of ASD in humans (Friedman, 1988). Patent foramen ovale is another form of interatrial communication and results from failure of the foramen ovale to close after birth; however, normal higher pressure in the left atrium keeps the foramen ovale functionally closed. Hemodynamics depend on the size of the defect and the presence of other cardiac malformations and/or secondary cardiopulmonary changes (Edwards, 1957; Friedman, 1988). In most cases higher left atrial pressure and lower right ventricular resistance result in left-to right shunting and subsequent volume overload to the right heart. Right heart enlargement may ensue. Domestic cats with ASDs may develop right-sided congestive heart failure, atrial arrhythmias, or rarely pulmonary hypertension (Brown, 1997). Pulmonary hypertension may lead to shunt reversal and cyanosis (Bonagura and Darke, 1995).

The prevalence of ASDs in necropsied panthers was 18%, well above the reported 1.9 to 2.8% prevalence of all congenital heart defects combined in domestic cats (Liu, 1977; Zook and Harpster, 1987). Further, the true prevalence of ASDs in Florida panthers may be higher as uncollared free-ranging panthers dying from ASDs are less likely to be collected compared to those dying from vehicular trauma.

Downloaded From: https://complete.bioone.org/journals/Journal-of-Wildlife-Diseases on 19 Apr 2024
Terms of Use: https://complete.bioone.org/terms-of-use

Despite other contributing factors, ASDs are suspected to have caused or directly contributed to the deaths of at least three Florida panthers. The ASD associated deaths of FP47 and FP20 probably resulted from volume overload to the right heart and subsequent overcirculation to the pulmonary vasculature. This could have been the result of exertion, most notably in the case of FP47 who apparently died during or shortly after a fight with another male. The average age at death of Florida panthers with severe ASDs was just over 2 yr. However, this figure is unreliable as the death of PCO192 was probably unrelated to the ASD (vehicular trauma) and the age at death of FP205 was undoubtedly affected by captivity and the attempt at surgical correction.

Atrial septal defect is rarely encountered as an isolated lesion in domestic cats (Brown, 1997), however, only FP205 had an additional defect (TVD). FP20 did show evidence of regurgitation across the tricuspid valve (bubble contrast study); however, TVD was not detected at necropsy. Clinical signs of ASDs are variable, and small defects may remain undetected in domestic cats (Brown, 1997). In a case report by Church and Allan (1990) a domestic cat with ASD and TVD was asymptomatic for 11 yr before acute onset of dyspnea. Atrial septal defects in domestic cats often result in right-sided heart failure (Brown, 1997); however, no evidence of ascites, hepatic chronic passive congestion, or pleural effusion were observed in panthers with ASDs in this study. Pulmonary hypertension may cause reversal of the shunt and cyanosis; however, in all examined panthers with severe ASDs, including FP205 (undergoing contrast angiography), no evidence of right-to-left shunting was observed.

Gross diagnoses of cardiac hypertrophy and dilatation in panthers with severe ASDs were primarily subjective though supported by comparisons of cardiac measurements of individual panthers with ASDs to the mean of those without ASDs (Table 1). Turk et al. (1983) identified criteria for right ventricular hypertrophy in dogs as ≥2 SDs above mean ratios of right ventricular weight to total body weight, total cardiac weight, and left ventricular and septal weights. In necropsied Florida panthers individual ventricular weights were not recorded; however, diagnosis of right ventricular hypertrophy in FP205 was supported by a relatively high RVT. Microscopic evidence of myofiber and nuclear changes in FP205 were also consistent with hypertrophy. FP205 also had gross evidence of right atrial and ventricular dilatation. Subjective diagnoses of gross right ventricular dilatation in FP20 and FP205 were supported by a relatively lower (although not ≥2 SDs below the mean) LAV/RAV ratio and in FP20 a relatively greater LVT/RVT ratio and lower A/P ratio (both ≥2 SDs from the mean). FP47 also had a comparatively high LVT/RVT ratio although not ≥2 SDs above the mean. Finally, FP20 and FP47 had relatively thinner right ventricular free walls compared to adult and juvenile panthers without ASDs. The right atrial and ventricular hypertrophy and/or dilatation in panthers with severe ASDs are thought to be compensatory mechanisms secondary to volume overload to the right heart due to the ASD and/or TVD/tricuspid insufficiency. It should be emphasized that these measurements were used to support what were primarily subjective diagnoses.

Pulmonary hypertension is a possible sequelae to ASD and associated microscopic changes in humans may include arterial medial hypertrophy, intimal arterial and arteriolar proliferation and sclerosis, lumenal obstruction, necrotizing arteritis (Edwards, 1957), and proliferation of longitudinal smooth muscle bundles and elastic fibers in small pulmonary arteries (Yamaki et al., 1986). However, dilatation of medium to large pulmonary arteries with atrophy and fibrosis of the tunica media seen in PCO192 and FP20 were consistent with lesions described in humans with ASDs and pulmonary hyperperfusion

Downloaded From: https://complete.bioone.org/journals/Journal-of-Wildlife-Diseases on 19 Apr 2024
Terms of Use: https://complete.bioone.org/terms-of-use

without hypertension (Edwards, 1957). The interstitial and perivascular fibrosis seen in FP205 was likely related to chronic edema and fibrin exudation (Dungworth, 1993). Pulmonary edema in PCO192, FP20, and FP205 was likely of hemodynamic origin. The significance of pleural fibrosis in PCO192 and FP205 is unknown.

Radiographic changes in dogs and cats with ASDs are uncommon but may include right heart enlargement and dilation of the pulmonary vessels (Burk and Ackerman, 1996). In this study, both panthers with severe ASDs radiographed (FP20 and FP205) had evidence of right heart enlargement, and in FP205, mild pulmonary overperfusion as evidenced by prominent pulmonary vasculature.

The ECGs in domestic cats with ASDs are frequently normal but may demonstrate right axis deviation, right bundle branch block, or a right atrial enlargement pattern (Brown, 1997). A right ventricular hypertrophy pattern (right axis deviation and deep S waves in leads I, II, III, and AVF) has been reported in dogs with ASD's (Hamlin et al., 1963). The ECG performed on FP20 was consistent with a right ventricular hypertrophy pattern while FP205 had no ECG abnormalities; the difference possibly related to the progression of pathological changes with age.

Echocardiography may reveal right atrial and ventricular enlargement as well as direct identification of the defect. However, defects <1 cm may be difficult or impossible to image (Burk and Ackerman, 1996). Doppler echocardiography has been effectively used to detect ventricular septal defects and ASDs of 2.5 to 3 mm in dogs (Sherman et al., 1987), and is considered the most sensitive and specific diagnostic tool for the detection and quantification of ASDs in dogs and cats (Burk and Ackerman, 1996). However, two-dimensional and color-flow Doppler echocardiographic examination failed to definitively diagnose a 10 mm ASD in FP205 during two separate examinations in a hospital setting. A two-dimensional echocardiographic examination of FP20 in a hospital setting also failed to detect a severe ASD. Concurrent TVD and/or tricuspid valve insufficiency may have complicated the detection of ASDs in both cases.

Heart murmurs in dogs with ASDs are described as those of relative pulmonic stenosis (an ejection murmur caused by a greater than normal volume of blood coursing through the pulmonic valve) with a split second heart sound, heard best at the left heart base (Hamlin et al., 1963). Tricuspid valve dysplasia produces a systolic regurgitant murmur, with maximum intensity over the midthorax near the right third to fifth intercostal spaces (Liu and Tilley, 1976). Heart murmurs in panthers with severe ASDs primarily were described as holosystolic, loudest at the heart base—right or left side depending on the ausculting veterinarian and the presence of regurgitation across the tricuspid valve.

The detection and grading of murmurs for panthers both with and without ASD appeared to depend more on the examining veterinarian than any other factor including location of examination (hospital or field setting). Patient position, level of anesthesia, time constraints, field conditions, and other factors during auscultation probably affected murmur detection but were rarely recorded. Degree of secondary cardiopulmonary changes affecting shunt hemodynamics may also have contributed to differences in murmur grades for panthers with severe ASDs. The heart murmurs due to ASDs in FP205 and FP20 were undoubtedly exaggerated by regurgitation across the tricuspid valves and tended to be loudest on the right side. The cause of murmurs in panthers without ASDs is unknown; however, Bush (1996) suggested that in some anesthetized animals, detection of heart murmurs may be associated with patient position. FP206 (without ASD) had a grade II/VI systolic right-sided murmur at 10 mo which was detectable when positioned in right lateral recumbency but not in left. Functional

Downloaded From: https://complete.bioone.org/journals/Journal-of-Wildlife-Diseases on 19 Apr 2024
Terms of Use: https://complete.bioone.org/terms-of-use

heart murmurs may be caused by anemia, bradycardia, or hyperthermia (Gompf, 1988). No panther examined in this study was severely anemic or bradycardic, and elevated temperatures in some panthers at the time of auscultation (due to exertion from capture) did not appear to increase the detection of murmurs. Soft systolic murmurs of grade I–II/VI may occur in normal domestic puppies and kittens <6-mo-old (Gompf, 1988). Although all panthers ausculted in this study were ≥6-mo-old, one panther without ASD had a grade II/VI murmur when ausculted at 6 and 10 mo, but had no murmur when examined by a different veterinarian at 1 yr.

Careful auscultation, and in suspected cases, portable ECG, radiography, and/or echocardiography may be used to evaluate Florida panthers for cardiac disease. Because of the high prevalence in Florida panthers, a severe ASD may be suspected in panthers with a heart base murmur of grade >II/VI (relative pulmonic stenosis) and split second heart sound. A right ventricular or atrial enlargement pattern and/or right bundle branch block on ECG may support the diagnosis. Radiographic evidence of right atrial and/or ventricular enlargement and prominent pulmonary vasculature may further support the diagnosis and confirmation may be attained by echocardiography. However, absence of detectable auscultative, ECG, radiographic, or echocardiographic abnormalities does not rule out ASD. Mild ASDs may be difficult or impossible to detect in the field and even severe cases may escape definitive diagnosis. Cost, field conditions, time constraints (anesthesia), and inconsistent results currently limit the practicality of field echocardiographic examination of Florida panthers.

Both autosomal recessive (Carleton et al., 1958) and dominant modes of inheritance for ASD have been observed in humans and the condition can recur through a number of generations (Howitt, 1961). In one study, children had at least a 37-fold greater chance of having an ASD if a parent had an ASD (Nora, 1968). Although suspected genealogy is yet to be proven by genetic analysis, radio-telemetry data suggest a familial tendency for ASDs in Florida panthers (Roelke et al., 1993; Maehr, 1997).

Badaruddoza et al. (1994) reported a higher prevalence of congenital heart disease, including ASDs, in inbred children versus non-bred children from the same population. Some breeds of domestic cats have a higher prevalence of cardiac defects—most likely the result of inbreeding (Liu et al., 1970). Rewell (1948) reported that three captive lion (*Panthera leo*) cubs died from ASDs and patent ductus arteriosus, and suggested this condition to be common in inbred lions. Roelke et al. (1993) suggested inbreeding as the underlying cause of ASDs in Florida panthers.

The release of Florida panther/captive puma hybrids into the free-ranging panther population between 1957 and 1967 (Vanas, 1976) has resulted in two distinct Florida panther genotypes (O'Brien et al., 1990). Panthers with genetic evidence of South American puma ancestry (intergrades) had a greater genetic diversity and fewer congenital anomalies than panthers retaining an 'authentic' genotype (Roelke et al., 1993). Indeed, the level of mitochondrial DNA variation, frequency of polymorphic allozyme loci, and average heterozygocity of allozyme loci are lower among 'authentic' Florida panthers than any other similarly studied feline except the cheetah (*Acinonyx jubatus*) (O'Brien, 1990; Newman et al., 1985; Roelke et al., 1993). Although only four Florida panther/South American puma intergrades were necropsied in this study, lack of ASDs among these lends support to a genetic basis for this anomaly. However, it should be noted that distribution of the two genotypes was geographically biased and that genotyping of one of the seven 'authentic' panthers with ASDs was restricted to the maternally inherited mtDNA (i.e., the genetics of the paternal contribution is unknown).

Nora (1968) suggested a multifactorial

Downloaded From: https://complete.bioone.org/journals/Journal-of-Wildlife-Diseases on 19 Apr 2024
Terms of Use: https://complete.bioone.org/terms-of-use

inheritance for the etiology of ASD in humans—a genetic predisposition, affected by a large number of genes, may work synergistically with low levels of environmental teratogens to cause ASDs. Environmental contaminants such as organic mercury (Roelke, 1990) and other heavy metals (Dunbar, 1994a), polychlorinated biphenyls, and organochlorines (Dunbar, 1994b; Facemire et al., 1995) have been found in high concentrations in some Florida panthers; however, their effect on the expression of ASDs is unknown. Atrial septal defects have also occurred in vitamin A deficient lions (Heywood, 1967); however, Dunbar et al. (1999) have presented data indicating Florida panthers are not vitamin A deficient.

Genetic research is necessary to help determine the role of heredity in the expression of ASDs in Florida panthers. Pedigree analysis may then identify those panthers most at risk and, combined with improved field diagnostics, may assist early diagnoses. Knowledge of the ASD status of individuals may assist wildlife managers with decisions concerning captive breeding, treatment and/or removal from the wild, or translocation. Future comparisons of the prevalence of ASDs and other congenital anomalies in 'non-introgressed' Florida panthers versus prevalences among F1 and greater generations of introgressed panthers may help evaluate the genetic restoration project.

ACKNOWLEDGMENTS

The authors thank D. Anderson, O. L. Bass, R. C. Belden, V. Giboldi, D. K. Jansen, K. Johnson, M. Lamm, E. D. Land, M. A. Lotz, D. S. Maehr, R. T. McBride, J. W. McCown, J. C. Roboski, J. C. Roof, D. Rotstein, and T. Ruth for capture and handling of live panthers and collection of dead panthers used in this study and S. Linda for statistical analysis. We also thank personnel of the VMTH Department of Pathobiology and SCWDS for assistance with necropsies, and E. D. Land for review of the manuscript. This project was funded in part by the FGFWFC federal grant-in-aid funds administered through the U. S. Fish and Wildlife Service under section 6 of the Endangered Species Act of 1973) (PL No. 93-205) and the Florida Nongame Wildlife Trust.

LITERATURE CITED

BADARUDDOZA, M. AFZAL, AND AKHTARUZZMAN. 1994. Inbreeding and congenital heart disease in a North Indian population. Clinical Genetics 45: 288–291.

BARONE, M. A., M. E. ROELKE, J. HOWARD, J. L. BROWN, A. E. ANDERSON, AND D. E. WILDT. 1994. Reproductive characteristics of male Florida panthers: Comparative studies from Florida, Texas, Colorado, Latin America, and North American zoos. Journal of Mammalogy 75: 150–162.

BELDEN, R. C. 1986. Florida panther recovery plan implementation—a 1983 progress report. *In* Cats of the world: Biology, conservation, and management, S. D. Miller and D. D. Everett (eds.). National Wildlife Foundation, Washington, D. C., pp. 159–172.

BONAGURA, J. D., AND P. G. G. DARKE. 1995. Congenital heart disease. *In* Textbook of veterinary internal medicine, S. J. Ettinger and E. C. Feldman (eds.). W. B. Saunders Co., Philadelphia, Pennsylvania, pp. 892–943.

BROWN, W. A. 1997. Congenital heart disease. *In* Consultations in feline internal medicine 3. J. R. August (ed.). W. B. Saunders Company, Philadelphia, Pennsylvania, pp. 263–272.

BURK, R. L., AND N. ACKERMAN. 1996. Small animal radiology and ultrasonography: A diagnostic atlas and text. W. B. Saunders Co., Philadelphia, Pennsylvania, 644 pp.

BUSH, M. 1996. Methods of capture, handling, and anesthesia. *In* Wild mammals in captivity: Principles and techniques. D. G. Kleiman, M. E. Allen, K. V. Thompson, and S. Lumpkin, (eds.). University of Chicago Press, Chicago, Illinois, pp. 25–40.

CARLETON, R. A., W. H. ABELMANN, AND E. W. HANCOCK. 1958. Familial occurrence of congenital heart disease. New England Journal of Medicine 259: 1237–1245.

CHURCH, D. B., AND G. S. ALLAN. 1990. Atrial septal defect and Eisenmenger's syndrome in a mature cat. Australian Veterinary Journal 67: 380.

DUNBAR, M. R. 1994a. Florida panther biomedical investigations. *In* Proceedings of the Florida panther conference. D. B. Jordan (ed.). U.S. Fish and Wildlife Service, Gainesville, Florida, pp. 342–392.

———. 1994b. Florida panther biomedical investigation, annual performance report. Endangered species project E-1-11 7506, Florida Game and Fresh Water Fish Commission, Tallahassee, Florida, 20 pp.

———, M. W. CUNNINGHAM, AND S. B. LINDA. 1999. Vitamin A concentrations in serum and liv-

Downloaded From: https://complete.bioone.org/journals/Journal-of-Wildlife-Diseases on 19 Apr 2024
Terms of Use: https://complete.bioone.org/terms-of-use

er from Florida panthers. Journal of Wildlife Diseases 35: In press.

———, P. NOL, AND S. B. LINDA. 1997. Hematologic and serum biochemical reference intervals for Florida panthers. Journal of Wildlife Diseases 33: 783–789.

DUNGWORTH, D. L. 1993. The respiratory system. *In* Pathology of domestic animals, K. V. F. Jubb, P. C. Kennedy, and N. Palmer (eds.). Academic Press, San Diego, California, pp. 539–699.

EDWARDS, J. E. 1957. Functional pathology of the pulmonary vascular tree in congenital cardiac disease. Circulation 15:164–196.

FACEMIRE, C. F., T. S. GROSS, AND L. J. GUILLETE, JR. 1995. Reproductive impairment in the Florida panther: Nature or nurture? Environmental Health Perspectives 103 (Suppl. 4): 79–86.

FRIEDMAN, W. F. 1988. Congenital heart disease in infancy and childhood. *In* Heart disease, a textbook of cardiovascular medicine, E. Braunwald (ed.). W. B. Saunders Co., Philadelphia, Pennsylvania, pp. 896–975.

GOMPF, R. E. 1988. The clinical approach to heart disease: History and physical examination. *In* Canine and feline cardiology, P. R. Fox (ed.). Churchill Livingstone, New York, New York, pp. 29–42.

HAMLIN, R. L., R. SMITH, AND D. L. SMETZER. 1963. Ostium secundum type interatrial septal defects in the dog. Journal of the American Veterinary Medical Association 143: 149–157.

HEYWOOD, R. 1967. Vitamin A in the liver and kidney of some felidae. British Veterinary Journal 123: 390–395.

HOWITT, G. 1961. Atrial septal defect in three generations. British Heart Journal 23: 494–496.

LIU, S. 1977. Pathology of feline heart disease. Veterinary Clinics of North America (Small Animal Practice) 7: 323–339.

———. 1983. Postmortem examination of the heart. Veterinary Clinics of North America: Small Animal Practice 13: 379–394.

———, R. J. TASHJIAN, AND A. K. PATNAIK. 1970. Congestive heart failure in the cat. Journal of the American Veterinary Medical Association 156: 1319–1330.

———, AND L. P. TILLEY. 1976. Dysplasia of the tricuspid valve in the dog and cat. Journal of the American Veterinary Medical Association 169: 623–630.

LUNA, L. G. 1968. Manual of histologic staining methods of the Armed Forces Institute of Pathology. McGraw-Hill Book Company, New York, New York, 251 pp.

MAEHR, D. S. 1997. The Florida panther: Life and death of a vanishing carnivore. Island Press, Washington, D.C., 261 pp.

———, E. D. LAND, AND J. C. ROOF. 1991. Social ecology of Florida panthers. National Geographic Research and Exploration 7: 414–431.

MCCOWN, J. W., D. S. MAEHR, AND J. ROBOSKI. 1990. A portable cushion as a wildlife capture aid. Wildlife Society Bulletin 18: 34–36.

NEWMAN, A., M. BUSH, D. E. WILDT, D. VAN DAM, M. T. FRANKENHUIS, L. SIMMONS, L. PHILLIPS, AND S. J. O'BRIEN. 1985. Biochemical genetic variation in eight endangered or threatened felid species. Journal of Mammalogy 66: 256–267.

NORA, J. J. 1968. Multifactorial inheritance hypothesis for the etiology of congenital heart diseases. Circulation 38: 604–617.

O'BRIEN, S. J., M. E. ROELKE, N. YUHKI, K. W. RICHARDS, W. E. JOHNSON, W. L. FRANKLIN, A. E. ANDERSON, O. L. BASS JR., R. C. BELDEN, AND J. S. MARTENSON. 1990. Genetic introgression within the Florida panther *Felis concolor coryi.* National Geographic Research 6: 485–494.

REWELL, R. E. 1948. Report of the pathologist for the year 1947. Proceedings of the Zoological Society of London 118: 501–514.

ROELKE, M. E. 1990. Florida panther biomedical investigation, final performance report. Endangered species project E-1-11 7506. Florida Game and Fresh Water Fish Commission, Tallahassee, Florida, 178 pp.

———, J. S. MARTENSON, AND S. J. O'BRIEN. 1993. The consequences of demographic reduction and genetic depletion in the endangered Florida panther. Current Biology 3: 340–350.

SAS INSTITUTE INC. 1990. SAS language: Reference, version 6, 1st Edition. SAS Institute Inc., Cary, North Carolina, 1042 pp.

SEAL, U. S. 1994. A plan for genetic restoration and management of the Florida panther (*Felis concolor coryi*). Report to the Florida Game and Fresh Water Fish Commission, Conservation Breeding Specialist Group, SSC/IUCN. White Oak Conservation Center, Yulee, Florida, 23 pp.

———, AND R. LACY. 1989. Florida panther (*Felis concolor coryi*) viability analysis and species survival plan. Report to the U.S. Fish and Wildlife Service. Captive Breeding Specialist Group, SSC/IUCN, Apple Valley, Minnesota, 208 pp.

SHERMAN, F. S., D. J. SAHN, L. M. VALDES-CRUZ, K. J. CHUNG, AND W. ELIAS. 1987. Two-dimensional Doppler color flow mapping for detecting atrial and ventricular defects. Studies in an animal model and in the clinical setting. Herz 12: 212–216.

TURK, J. R., M. A. M. TURK, AND C. R. ROOT. 1983. Necropsy of the canine heart: A simple technique for quantifying ventricular hypertrophy and valvular alterations. The Compendium on Continuing Education for the Practicing Veterinarian 5: 905–910.

VANAS, J. 1976. The Florida panther in the Big Cypress Swamp and the role of the Everglades Wonder Gardens in past and future captive breeding programs. *In* Proceedings of the Florida panther conference, P. C. H. Prichard (ed.).

Downloaded From: https://complete.bioone.org/journals/Journal-of-Wildlife-Diseases on 19 Apr 2024
Terms of Use: https://complete.bioone.org/terms-of-use

Florida Audubon Society and Florida Game and Fresh Water Fish Commission, Orlando, Florida, pp. 109–111.

WARE, W. A. 1995. Abnormal heart sounds and heart murmurs. *In* Textbook of veterinary internal medicine, S. J. Ettinger and E. C. Feldman (eds.). W. B. Saunders Co., Philadelphia, Pennsylvania, pp. 86–89.

YAMAKI, S., T. HORIUCHI, M. MIURA, Y. SUZUKI, E. ISHIZAWA, AND T. TAKAHASHI. 1986. Pulmonary vascular disease in secundum atrial septal defect with pulmonary hypertension. Chest 89: 694–698.

ZOOK, B. C., AND N. K. HARPSTER. 1987. The cardiovascular system. *In* Diseases of the cat: Medicine and surgery, J. Holzworth (ed.). W. B. Saunders Co., Philadelphia, Pennsylvania, pp. 863–869.

Received for publication 1 July 1998.

Downloaded From: https://complete.bioone.org/journals/Journal-of-Wildlife-Diseases on 19 Apr 2024
Terms of Use: https://complete.bioone.org/terms-of-use