



Mycoplasmosis Associated Perosis Type Skeletal Deformity in a Saker Falcon Nestling in Hungary

Authors: Erdélyi, K., Tenk, M., and Dán, Á.

Source: Journal of Wildlife Diseases, 35(3) : 586-590

Published By: Wildlife Disease Association

URL: <https://doi.org/10.7589/0090-3558-35.3.586>

BioOne Complete (complete.BioOne.org) is a full-text database of 200 subscribed and open-access titles in the biological, ecological, and environmental sciences published by nonprofit societies, associations, museums, institutions, and presses.

Your use of this PDF, the BioOne Complete website, and all posted and associated content indicates your acceptance of BioOne's Terms of Use, available at www.bioone.org/terms-of-use.

Usage of BioOne Complete content is strictly limited to personal, educational, and non - commercial use. Commercial inquiries or rights and permissions requests should be directed to the individual publisher as copyright holder.

BioOne sees sustainable scholarly publishing as an inherently collaborative enterprise connecting authors, nonprofit publishers, academic institutions, research libraries, and research funders in the common goal of maximizing access to critical research.

Mycoplasmosis Associated Perosis Type Skeletal Deformity in a Saker Falcon Nestling in Hungary

K. Erdélyi,^{1,5} M. Tenk,² and Á. Dán^{3,4} ¹ Departments of Wildlife Diseases, ² Bacteriology and ³ Immunology, Central Veterinary Institute, H-1149 Budapest, Tábornok u.2., Hungary; ⁴ Veterinary Medical Research Institute, Hungarian Academy of Sciences, H-1581 Budapest, P.O. Box 18, Hungary; and ⁵ Corresponding author (e-mail: erdelyi@indigo2.oai.hu)

ABSTRACT: A wild, 3-wk-old saker falcon (*Falco cherrug*) nestling showing uncoordinated movements and a perosis type tarsometatarsus deformity was found abandoned; it was euthanized a week later on 29 May 1997 after an unsuccessful attempt to rehabilitate it. Gross pathological findings included congestion of parenchymal organs and a lateral bowing of the left tarsometatarsal bone. Histopathology revealed initial interstitial hepatitis, focal catarrhal pneumonia, and dyschondroplasia in the epiphysis of the left tarsometatarsus. Mycoplasmas were isolated from the lungs, trachea, bone marrow and brain. A polymerase chain reaction (PCR) assay was performed for the detection of the mycoplasmal 16S rRNA gene. The resulting 262 base pair PCR product was sequenced and compared to the available mycoplasmal sequences but no identical corresponding sequences were found. However, 98% similarity was found to the *Mycoplasma buteonis* 16S rRNA and the isolate also was positive by immunoblotting against reference sera to the same species.

Key words: Case report, *Falco cherrug*, *Mycoplasma buteonis*, perosis, saker falcon.

Mycoplasmas have been isolated from birds of prey on several occasions (Furr et al., 1977; Bölske and Mörner, 1982; Poveda et al., 1990a, 1990b, 1994; Panangala et al., 1993) and some of these isolates were established as new species (Panangala et al., 1993; Poveda et al., 1994). A serological study conducted on a range of wild bird species detected seropositivity to *M. gallisepticum* in two species of birds of prey (Ziedler et al., 1995). The birds in these reports were all adults and pathological changes, if present, ranged from sinusitis to pneumonia and airsacculitis.

On 29 May 1997, a live 3-wk-old saker falcon (*Falco cherrug*) nestling was presented to the Wildlife Health department of the Central Veterinary Institute (Budapest, Hungary). Ornithologists of the Na-

ture Conservation Authority (Budapest, Hungary) had found the bird a week earlier, under a nest located in an agricultural area 60 km east of Budapest in Heves County, Hungary (47°40'N, 19°40'E). Their efforts to hand raise the obviously ill nestling had failed due to its worsening neurological symptoms and dyskinesia. Therefore, a detailed diagnostic procedure was requested.

After the clinical examination and a short observation period the bird was humanely killed by cervical dislocation. Blood was collected, and necropsy was performed immediately after death. Tissue samples were taken from the lungs, liver, heart, brain and the affected proximal epiphysis of the left tarsometatarsal bone and were fixed in 10% formaldehyde solution. The bone sample was decalcified in 15% EDTA solution. Routine histologic sections were prepared and stained with hematoxylin-eosine. Samples were taken aseptically from the liver, lungs, bone marrow, brain and trachea for bacterial and mycoplasma culture. All samples were homogenized in approximately 10 times volume of physiological buffered saline solution. The above organ samples were cultivated on 5% sheep blood agar (Merck, Darmstadt, Germany) at 37 C under both aerobic and anaerobic conditions, as well as on a Tryptic Soy Agar (DIFCO Laboratories, Detroit, Michigan, USA) based Haemophilus medium at 37C in 10% v/v CO₂. For mycoplasma isolation, 0.2 ml aliquots were transferred from each suspension into 2 ml of modified Hayflick's broth (Whitford et al., 1994) and were also plated directly onto modified Hayflick's agar medium (Whitford et al., 1994) and then

incubated at 37°C, in 5% v/v CO₂. The isolated mycoplasma strain was clone purified three times using disposable 0.2 µm Minisart membrane filters (Sartorius Corp., Edgewood, New York, USA).

A polymerase chain reaction (PCR) was performed on the isolated mycoplasma strain. A general mycoplasma primer pair designed by Van Kuppeveld et al. (1992) was used for the detection of the 16S ribosomal (r)RNA gene. One µl of broth culture was used as a DNA template. The PCR conditions were as described earlier by Kiss et al. (1997). The amplified DNA product was cloned and sequenced. It was recovered from low melting temperature agarose (Sigma, St Louis, Missouri, USA) with a phenol-based method described by Sambrook et al. (1989). The purified fragment was blunt ligated into the EcoRV site of the pBluescript SK plasmid (Stratagene, La Jolla, California, USA). The double stranded plasmid DNA was sequenced by the dideoxynucleotide chain termination method from both directions with the AL-Fexpress AutoRead Sequencing Kit (Amersham Pharmacia Biotech, Uppsala, Sweden) using Universal and Reverse primers. The sequence was analysed by programs of the Lasergene software package (DNASTAR Inc., Madison, Wisconsin, USA). A homology search of GenBank and EMBL databases with the BLAST search program (Altschul et al., 1990) was performed. Partial regions corresponding to our sequence were excised from the available mycoplasmal 16S rRNA sequences and were used to generate a multiple alignment.

On clinical examination the bird was in relatively good body condition, weighed 920 g and showed appropriate feathering for its age. Normal behavior patterns such as sleeping, curiosity, fear and begging for food were observed with one exception: when excited, the bird flexed its neck to the sternum with sudden, uncoordinated jerky movements. The left leg was rotated laterally and lacked muscle tone; its digits were limp and ataxic, but deep pain sen-

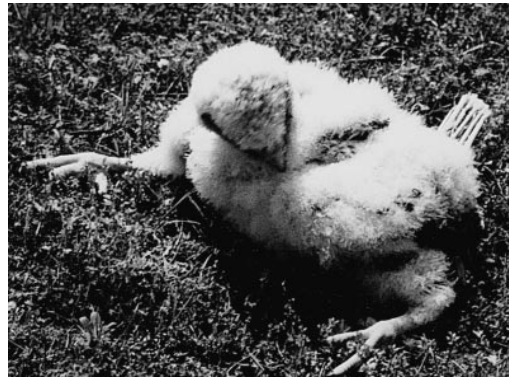


FIGURE 1. Paresis of the left leg and a perosis type tarsometatarsus deformity in a 3-wk-old saker falcon nestling.

sation was not affected (Fig. 1). The lower left eyelid was covered with flakes of dry ocular discharge. At necropsy the liver was slightly enlarged and congested, and there were several petechial hemorrhages on its surface. Lungs were congested and contained several distinctive greyish foci. The proximal epiphysis of the left tarsometatarsal bone was bowed laterally at an angle of approximately 30° (Fig. 2). There were no discernible macroscopic lesions in the air sacs or joints. Histopathological changes comprised a marked cerebellar edema with karyopycnosis and lysis of some neurons in the molecular layer; initial interstitial infiltration of the liver by heterophils; and an acute, in some areas subacute, focal catarrhal pneumonia characterized by accumulation of heterophils in the parabronchi and of mononuclear cells in interstitial areas around the blood vessels. There were subtle changes in the epiphysis cartilage of the tarsometatarsus with dystrophy and lysis of chondrocytes confined to areas surrounding nutritional blood vessels (Fig. 3). Dyschondroplasia could be detected in distal areas.

There was no significant growth of bacteria on the media used. However, after 24 hr of incubation several typical large, "fried-egg" shape colonies could be observed on all Hayflick's medium agar plates. Biochemical studies (Whitford et al., 1994) showed that the strain ferment-

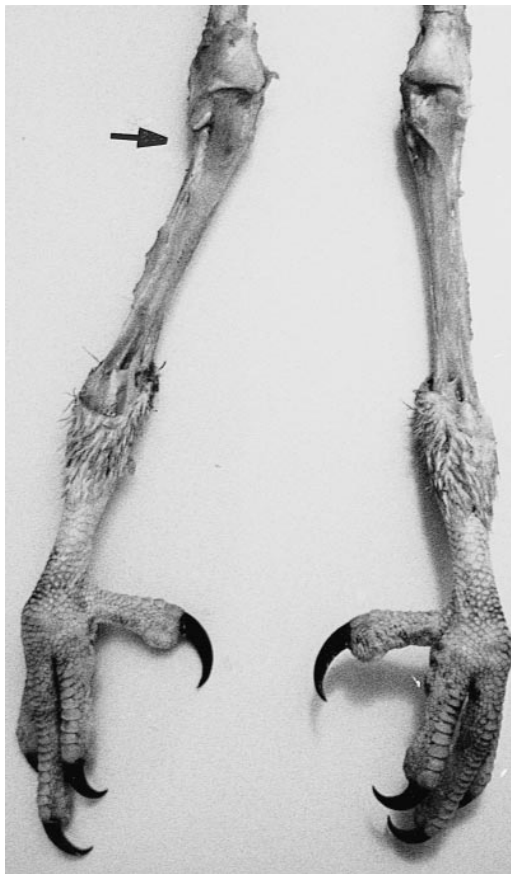

FIGURE 2. Lateral bowing, valgus deformity (arrow) in the proximal epiphysis of the left tarsometatarsal bone of a saker falcon nestling.

ed glucose and that it was sensitive to dig-
 itonin (7–8 mm zone of inhibition). The
 strain did not show phosphatase activity,
 did not hydrolyse arginine or urea, neither
 did it reduce tetrazolium chloride. There
 was no film and spot production. The iso-
 late proved positive by immunoblotting to
 reference sera against *M. buteonis* (per-
 formed by J. M. Bradbury, Department of
 Veterinary Pathology, Faculty of Veterinary
 Science, University of Liverpool, UK).

The PCR resulted in a 262 base pair
 (bp) DNA product (not shown). After se-
 quencing, the homology search of the
 GenBank and EMBL databases identified
 no 100% similarity of the 262 bp sequence
 with any mycoplasmal 16S rRNA so far se-
 quenced. Comparison with the corre-

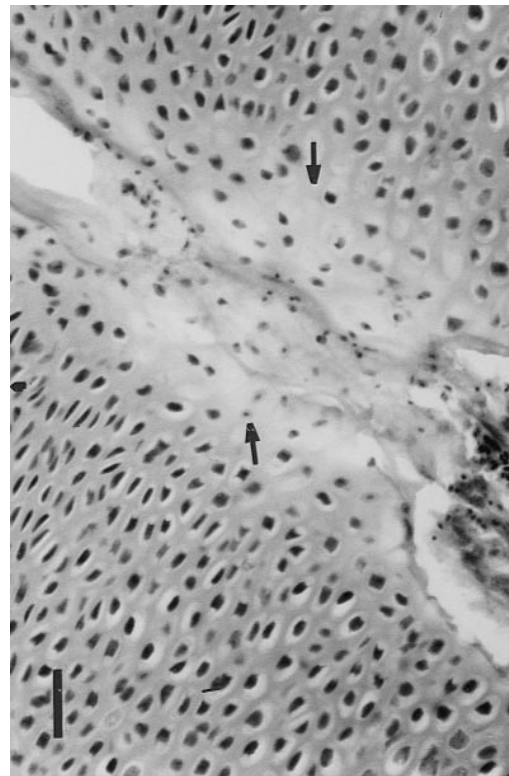


FIGURE 3. Dystrophy and lysis of chondrocytes (arrows) around blood vessels in the growth plate cartilage of the proximal epiphysis of the left tarsometatarsus of a saker falcon nestling. H&E stain. Bar = 40 μ m.

sponding partial regions showed the fol-
 lowing similarities among the best match-
 ing mycoplasma species: *M. crocodyli*
 97.0%, “*M. lacerti*” 96.3%, *M. edwardii*
 96.3%, *M. leonicaptivi* 96.6%, *M. felis*
 94.8%, *M. bovirhinis* 94.8%, *M. gallina-
 ceum* 95.9%, *M. synoviae* 94.8%, and *M.
 sturni* 95.9%. Comparison with the un-
 published sequence of *M. buteonis* 16S
 rRNA (K.-E. Johansson, pers. comm.) re-
 vealed a 98.0% similarity. It is important
 to note that these results are based on par-
 tial rRNA analysis and therefore of infor-
 mative value only.

Perosis type skeletal deformities later
 associated with generalized *M. meleagridis*
 infection were first reported in turkey
 poults and named Turkey Syndrome-65
 (TS-65) (Working Party, 1965). The role of

M. meleagridis in TS-65 as a causative agent was proved experimentally (Wise et al., 1974). The syndrome was also reproduced by *M. gallisepticum* (Wannop et al., 1971; Wise and Fuller, 1975) and *M. iowae* (Bradbury and Ideris, 1982; Bradbury et al., 1988) infections in turkey poult and with an unidentified mycoplasma strain in pheasants (Wise and Fuller, 1976). Several attempts have been made to clarify the pathogenesis of the disease but none gave definite answers. According to most theories, transovarially transmitted mycoplasmas or very early generalized mycoplasma infections may deprive the young birds' metabolism of substances essential in bone development (Wise and Fuller, 1975; Bigland and Warenycia, 1978; Yamamoto, 1997). A clinical perosis case attributed to nutritional deficiencies also was reported in a captive lanner falcon (*Falco biarmicus*) by Kummerfeld (1982).

This case highlights the possibility of vertical spread and potential pathogenicity of mycoplasmas in free living falcon populations. It is difficult to estimate the real pathogenicity of the isolated mycoplasma strain and to predict the chances for recovery of diseased nestlings. If breeding pairs remain infected for more than a year, the disease could significantly affect breeding success. Pathogenicity testing of the isolated mycoplasma strain and further observations of affected falcons are necessary to obtain at least partial answers to the above questions.

Although the DNA sequence analysis involved only a part of the 16S rRNA gene, its results along with the result of the immunoblot assay suggest that the isolated mycoplasma strain is *M. buteonis*. The final answer can only be given after obtaining the complete sequence of the 16S rRNA gene.

We are grateful to J. M. Bradbury for performing the immunoblot assay and to K.-E. Johansson for comparing our sequence data with the *M. buteonis* 16S rRNA sequence. This work was partly supported by the OTKA A312 grant of the

National Research Fund of Hungary. We thank J. Bagyura for presenting us the case, V. Sztojkov, F. Rátz and R. Glávits for their helpful advice during the diagnostic work and reviewing the manuscript.

LITERATURE CITED

- ALTSCHUL, S. F., W. GISH, W. MILLER, E. W. MYERS, AND D. J. LIPMAN. 1990. Basic local alignment search tool. *Journal of Molecular Biology* 215: 403–410.
- BIGLAND, C. H., AND M. W. WARENYCIA. 1978. Effects of biotin, folic acid and pantothenic acid on the growth of *Mycoplasma meleagridis*, a turkey pathogen. *Poultry Science* 57: 611–618.
- BÖLSKE, G., AND T. MÖRNER. 1982. Isolation of a *Mycoplasma* sp. from three buzzards (*Buteo* spp.). *Avian Diseases* 26: 406–411.
- BRADBURY, J. M., AND A. IDERIS. 1982. Abnormalities in turkey poult following infection with *Mycoplasma iowae*. *Veterinary Record* 110: 559–560.
- , ———, AND T. T. OO. 1988. *Mycoplasma iowae* infection in young turkeys. *Avian Pathology* 17: 149–171.
- FURR, P. M., J. E. COOPER, D., AND D. TAYLOR-ROBINSON. 1977. Isolation of mycoplasmas from three falcons (*Falco* spp). *Veterinary Record* 100: 72–73.
- KISS, I., K. MATIZ, E. KASZANYITZKY, Y. CHÁVEZ, AND K.-E. JOHANSSON. 1997. Detection and identification of avian mycoplasmas by polymerase chain reaction and restriction fragment polymorphism assay. *Veterinary Microbiology* 58: 23–30.
- KUMMERFELD, N. 1982. Perosis bei einem Lannerfalken (*F. biarmicus*). *Praktische Tierarzt* 63: 449–450, 452.
- PANANGALA, V. S., J. S. STRINGFELLOW, K. DYBVIG, A. WOODARD, F. SUN, D. L. ROSE, AND M. M. GRESHAM. 1993. *Mycoplasma coragypsi* sp. nov., a new species from the footpad abscess of a black vulture, *Coragyps atratus*. *International Journal of Systematic Bacteriology* 43: 585–590.
- POVEDA, J. B., J. CARRANZA, A. MIRANDA, A. GARRIDO, M. HERMOSO, A. FERNANDEZ, AND J. DOMENECH. 1990a. An epizootiological study of avian mycoplasmas in southern Spain. *Avian Pathology* 19: 627–633.
- , J. GIEBEL, H. KIRCHHOFF, AND A. FERNANDEZ. 1990b. Isolation of mycoplasmas from a buzzard, falcons and vultures. *Avian Pathology* 19: 779–783.
- , ———, J. FLOSSDORF, J. MEIER, AND H. KIRCHHOFF. 1994. *Mycoplasma buteonis* sp. nov., *Mycoplasma falconis* sp. nov., and *Mycoplasma gypis* sp. nov., three species from birds of prey. *International Journal of Systematic Bacteriology* 44: 94–98.

- SAMBROOK, J., E. F. FRITSCH, AND T. MANIATIS. 1989. Molecular cloning: A laboratory manual, 2nd Edition. Cold Spring Harbor Laboratory Press, Cold Spring Harbor, New York, pp. 6.30–6.31.
- VAN KUPPEVELD, F. J. M., J. T. M. VAN DER LOGT, A. F. ANGULO, M. J. VAN ZOEST, W. G. V. QUINT, H. G. M. NIESTERS, J. M. D. GALAMA, AND W. J. G. MELCHERS. 1992. Genus- and species-specific identification of mycoplasmas by 16S rRNA amplification. *Applied Environmental Microbiology* 58: 2606–2615.
- WANNOP, C. C., E. J. BUTLER, AND A. W. PEARSON. 1971. Experimental reproduction of turkey syndrome 65 by infection with *M. gallisepticum*. *Veterinary Record* 88: 30–33.
- WHITFORD, H. W., R. F. ROSEBUSCH, AND L. H. LAUERMAN (1994) *Mycoplasmosis in Animals: Laboratory Diagnosis*. Iowa State University Press, Ames, Iowa, USA. 186 pp.
- WISE, D. R., M. K. FULLER, AND G. A. THORNTON. 1974. Experimental reproduction of turkey syndrome '65 with *Mycoplasma meleagridis*. *Research in Veterinary Science* 17: 236–241.
- , AND ———. 1975. Experimental reproduction of turkey syndrome 65 with *Mycoplasma meleagridis* and *M. gallisepticum* and associated changes in serum protein characteristics. *Research in Veterinary Science* 19: 201–203.
- , AND ———. 1976. Pathogenicity studies in poultry with an unidentified serotype of mycoplasma. *Research in Veterinary Science* 20: 334–339.
- WORKING PARTY. 1965. A new syndrome in turkey poults. *Veterinary Record* 77: 1292.
- YAMAMOTO, R. 1997. *Mycoplasma meleagridis* infection. In *Diseases of poultry*, 10th Edition, B. W. Calnek, H. J. Barnes, C. W. Beard, L. R. McDougald and Y. M. Saif (eds.). Iowa State University Press, Ames, Iowa, pp. 208–219.
- ZIEDLER, K., A. HLINAK, G. RAETZ, O. WERNER, AND D. EBNERE. 1995. Untersuchungen zum Antikörperstatus von Wild- und Zoovogeln gegen ausgewählte Nutztier-relevante Erreger. *Journal of Veterinary Medicine, Series B* 42: 321–330.

Received for publication 13 October 1998.