



## **Ehrlichia chaffeensis in Archived Tissues of a White-tailed Deer**

Authors: Little, Susan E., and Howerth, Elizabeth W.

Source: Journal of Wildlife Diseases, 35(3) : 596-599

Published By: Wildlife Disease Association

URL: <https://doi.org/10.7589/0090-3558-35.3.596>

---

BioOne Complete ([complete.BioOne.org](https://complete.BioOne.org)) is a full-text database of 200 subscribed and open-access titles in the biological, ecological, and environmental sciences published by nonprofit societies, associations, museums, institutions, and presses.

Your use of this PDF, the BioOne Complete website, and all posted and associated content indicates your acceptance of BioOne's Terms of Use, available at [www.bioone.org/terms-of-use](https://www.bioone.org/terms-of-use).

Usage of BioOne Complete content is strictly limited to personal, educational, and non - commercial use. Commercial inquiries or rights and permissions requests should be directed to the individual publisher as copyright holder.

---

BioOne sees sustainable scholarly publishing as an inherently collaborative enterprise connecting authors, nonprofit publishers, academic institutions, research libraries, and research funders in the common goal of maximizing access to critical research.

## ***Ehrlichia chaffeensis* in Archived Tissues of a White-tailed Deer**

**Susan E. Little,<sup>1,3</sup> and Elizabeth W. Howerth<sup>2</sup>** <sup>1</sup> Department of Medical Microbiology and Parasitology, and <sup>2</sup> Department of Pathology, College of Veterinary Medicine, The University of Georgia, Athens, Georgia 30602, USA; and <sup>3</sup> Corresponding author (email: slittle@calc.vet.uga.edu).

**ABSTRACT:** White-tailed deer (*Odocoileus virginianus*) play an integral role in the natural history of *Ehrlichia chaffeensis*, the causative agent of human monocytic ehrlichiosis (HME). Paraffinized tissues from a white-tailed deer submitted as a diagnostic case to the Southeastern Cooperative Wildlife Disease Study (Athens, Georgia, USA) in October of 1985 and originally described as infected with an unidentified rickettsial organism were re-examined by specific nested polymerase chain reaction (PCR) for evidence of infection with *Ehrlichia* spp. *Ehrlichia chaffeensis* was identified from the bone marrow and inguinal lymph node of this deer based on amplification of a characteristic sequence-confirmed 16S rDNA fragment from these tissues. Parallel PCR tests on the same samples were negative for 16S rDNA fragments of the agent of human granulocytic ehrlichiosis (HGE) and for an *Ehrlichia*-like organism widely distributed in white-tailed deer populations. This report describes detection of *E. chaffeensis* in archived tissue from a deer collected before the index case of human monocytic ehrlichiosis was established.

**Key words:** *Ehrlichia chaffeensis*, human monocytic ehrlichiosis, *Odocoileus virginianus*, retrospective study, specific nested polymerase chain reaction, white-tailed deer.

Human monocytic ehrlichiosis, caused by the rickettsia *Ehrlichia chaffeensis*, is an emerging tick-borne disease which manifests as a febrile illness characterized by headache, myalgia, thrombocytopenia, and occasionally death (Fishbein et al., 1989). White-tailed deer (*Odocoileus virginianus*) were first implicated as a reservoir host of *E. chaffeensis* due to widespread serologic activity to and PCR evidence of *E. chaffeensis* in wild deer (Dawson et al., 1994a; Lockhart et al., 1996, 1997a). The importance of deer in the epidemiology of *E. chaffeensis* was confirmed by cell culture isolation of this organism from deer (Lockhart et al., 1997b; Little et al., 1998). Deer also have been reported to be infected with at least two other *Ehrlichia* spp.; the human granulocytic ehrlichiosis (HGE)

agent (Belongia et al., 1997; Little et al., 1998) and a distinct *Ehrlichia*-like organism described only from 16S rDNA sequence data (Dawson et al., 1996; Little et al., 1997).

In April of 1985, a male white-tailed deer from Wilkes County, Georgia (USA; 33°45'N 08°24'W) was submitted for diagnostic examination to the Southeastern Cooperative Wildlife Disease Study (College of Veterinary Medicine, University of Georgia, Athens, Georgia). The deer was debilitated, emaciated, and heavily parasitized with lone star ticks (*Amblyomma americanum*) and medium stomach worms (*Ostertagia ostertagi*), findings reported previously; it died within 24 hr of presentation (Conti and Howerth, 1987). In that report, granular rickettsial-type intracytoplasmic inclusions were described in monocytes in blood and lymph node smears (Conti and Howerth, 1987) stained with Diff-Quik (Dade Diagnostics of PR, Inc., Aguada, Puerto Rico). In the present report, we identify *E. chaffeensis* from tissues of that deer by polymerase chain reaction (PCR) amplification and sequencing of a species-characteristic rDNA fragment.

Two, 8 µm sections were cut from each of three blocks of archived, paraffin-embedded bone marrow, inguinal lymph node, and spleen, and placed in individual sterile 1.5 ml microcentrifuge tubes. Sections were extracted twice with 1 ml of xylene for 30 min at room temperature. The tissue pellet was washed twice with 0.5 ml of 100% ethanol, dried, and digested in 100 µl of 50 mM KCl, 100 mM Tris-HCl, 2.5 mM MgCl<sub>2</sub>, 0.5% Tween-20, 1% lauryl sulfate, and 200 µg/ml proteinase K at 50 C for 1 hr. Digested tissue was incubated at 95 C for 1 hr, placed on ice, and then centrifuged for 1 min at 7,000 × g.

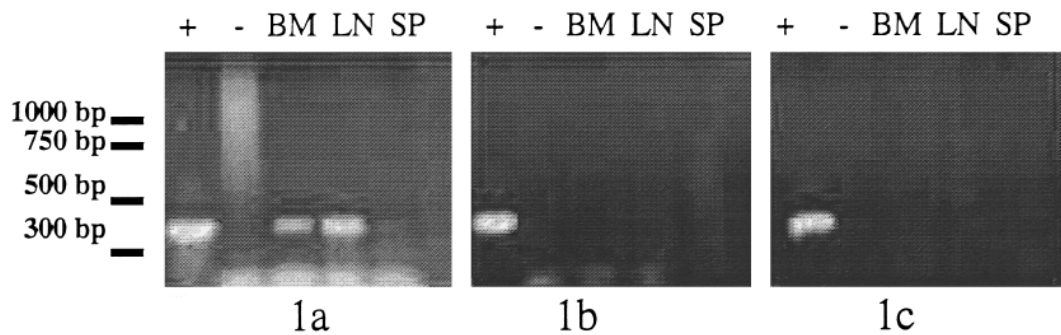


FIGURE 1. Agarose gel (2%) showing amplification products generated by PCR of nucleic acid extracted from tissue sections of bone marrow (BM), inguinal lymph node (LN), and spleen (SP) with primers for *E. chaffeensis* (1a), the HGE agent (1b), or the deer *Ehrlichia*-like organism (1c). A positive control (+) consisting of DNA extracted from *E. chaffeensis*-infected DH82 cells (1a), HGE-infected HL60 cells (1b), or whole blood from which sequence-confirmed deer *Ehrlichia* was previously amplified (1c) was included with each set of reactions. A negative control (–) of molecular biology grade water as template DNA was also included in each reaction set. The sequences of the 389 bp fragments from bone marrow and lymph node sections (1a) were identical to that of *E. chaffeensis*.

The resultant supernatant was used in diagnostic nested PCR as previously described (Dawson et al., 1994b; Little et al., 1997). *Ehrlichia*-wide primers ECB (5'-CGTATTACCGCGGCTGCTGGCA-3') and ECC (5'-AGAACGAACGCTGGCG-GCAAGCC-3') were used to generate a 474–479 bp product from 5 µl extracted nucleic acid in a 50 µl primary reaction (0.2 mM dNTP, 2.5 mM MgCl<sub>2</sub>, 50 mM KCl, 10 mM Tris-HCl, 0.1% Triton X-100, 0.8 µM each primer, and 2.5 units Taq DNA polymerase) which was cycled 30 times through 1 min at 94 C, 1 min at 45 C, and 2 min at 72 C. One µl of the product of this reaction was then added to each of three, individual secondary reactions identical in composition to the primary reactions except primers were either HE1 (5'-CAATTGCTTATAACCTTTTGCTT-ATAAAT-3') and HE3 (5'-TATAGGTAC-CGTCATTATCTTCCCTAT-3') for *E. chaffeensis*, GE9f (5'-AACGGATTATTC-TTTATAGCTTGCT-3') and GA1UR (5'-GAGTTTGCCGGGACTTCTTCT-3') for the HGE agent, or DGA (5'-TTATCTCT-GTAGCTTGCTACG-3') and GA1UR for the deer *Ehrlichia*-like organism. The temperature profile of the secondary reactions with DGA/GA1UR and GE9f/GA1UR were identical to that for the pri-

mary reactions except the annealing temperature was raised to 55 C. Secondary reactions with HE1/HE3 were cycled 40 times through 1 min at 94 C, 1 min at 55 C, and 15 sec at 72 C with a 1 sec extension per cycle.

Identity of amplicons was confirmed by sequencing both strands of individual PCR products. Internal amplification products were purified with a Microcon<sup>®</sup> spin filter (Amicon Inc., Beverly, Massachusetts) and submitted with corresponding primers to the Molecular Genetics Facility at the University of Georgia for sequencing following the Applied Biosystems Inc. protocol for the ABI 373A automated sequencer (Perkin-Elmer, Foster City, California). Resulting sequences were aligned using DNAsis Mac v 2.0 and compared with published sequence data for all *Ehrlichia* spp.

Figure 1 shows results of PCR testing of the bone marrow, inguinal lymph node, and spleen from this deer. Nested PCR produced amplicons with *E. chaffeensis*-specific primer pair HE1/HE3 from bone marrow and lymph node. The sequence of these products was identical to the published sequence of *E. chaffeensis*. Products were not generated with primers designed

to amplify the HGE agent or the deer *Ehrlichia*-like organism (Fig. 1).

Our results indicate that the rickettsia-like organism described in the parasitized deer from 1985 was *E. chaffeensis*, the causative agent of HME. The index case of HME occurred in 1986 in a patient bitten by a tick in Arkansas (USA; Maeda et al., 1987), and human cases have been retrospectively identified from archived samples from 1985 (Fishbein et al., 1994). Although no official national system of notifying public health officials exists, the Centers for Disease Control and Prevention (Atlanta, Georgia) has documented more than 400 cases of HME since the emergence of this disease (Walker and Dumler, 1996). Experimental and field data indicate that the organism is transmitted among deer and to people by the lone star tick, *A. americanum* (Ewing et al., 1995; Standaert et al., 1995; Lockhart et al., 1995, 1996). In the original case report, this deer was described as "covered by thousands of lone star ticks" (Conti and Howerth, 1987).

White-tailed deer are considered the major reservoir host for *E. chaffeensis* based on serologic, PCR, and cell culture evidence of infection of wild white-tailed deer with this organism (Dawson et al., 1994a; Lockhart et al., 1997a,b). Thus, the finding that this deer was infected with *E. chaffeensis* is not of great surprise. However, monocytic morulae characteristic of *E. chaffeensis* have not been found in blood smears or buffy coat smears of infected deer, although immunohistochemistry has detected morula-like structures in the lymph nodes of experimentally infected deer (Dawson et al., 1994b). Furthermore, clinical disease due to *E. chaffeensis* has not been described in deer (Dawson et al., 1994b; Ewing et al., 1995). In the present report, the presence of distinct morulae in the monocytes suggests this deer had an exceptionally high level of rickettsemia, which may have contributed in part to the animal's debilitation.

This research was conducted through sponsorship from the fish and wildlife agencies of Alabama, Arkansas, Florida, Georgia, Kansas, Kentucky, Louisiana, Maryland, Mississippi, Missouri, North Carolina, Puerto Rico, South Carolina, Tennessee, Virginia, and West Virginia. Funds were provided by the Federal Aid to Wildlife Restoration Act (50 Stat. 917) and through Grant Agreement 14-45-0009-94-906, National Biological Survey, U.S. Department of the Interior. Support also was received through Cooperative Agreement 94-9-6-13-0032-CA, Veterinary Services, Animal Plant and Health Inspection Service, U.S. Department of Agriculture.

#### LITERATURE CITED

- BELONGIA, E. A., K. D. REED, P. D. MITCHELL, C. P. KOLBERT, D. H. PERSING, J. S. GILL, AND J. J. KAZMIERCZAK. 1997. Prevalence of granulocytic *Ehrlichia* infection among white-tailed deer in Wisconsin. *Journal of Clinical Microbiology* 35: 1465-1468.
- CONTI, J. A., AND E. W. HOWERTH. 1987. Ostertagiosis in a white-tailed deer due to *Ostertagia ostertagi*. *Journal of Wildlife Diseases* 23: 159-162.
- DAWSON, J. E., J. E. CHILDS, K. L. BIGGIE, C. MOORE, D. STALLKNECHT, J. SHADDOCK, J. BOUSEMAN, E. HOFMEISTER, AND J. G. OLSON. 1994a. White-tailed deer as a potential reservoir of *Ehrlichia* spp. *Journal of Wildlife Diseases* 30: 162-168.
- , D. E. STALLKNECHT, E. W. HOWERTH, C. WARNER, K. BIGGIE, W. R. DAVIDSON, J. M. LOCKHART, V. F. NETTLES, J. G. OLSON, AND J. E. CHILDS. 1994b. Susceptibility of white-tailed deer (*Odocoileus virginianus*) to infection with *Ehrlichia chaffeensis*, the etiologic agent of human ehrlichiosis. *Journal of Clinical Microbiology* 32: 2725-2728.
- , C. K. WARNER, V. BAKER, S. A. EWING, D. E. STALLKNECHT, W. R. DAVIDSON, A. A. KOCAN, J. M. LOCKHART, AND J. G. OLSON. 1996. *Ehrlichia*-like 16S rRNA sequence from wild white-tailed deer (*Odocoileus virginianus*). *The Journal of Parasitology* 82: 52-58.
- EWING, S. A., J. E. DAWSON, A. A. KOCAN, R. W. BARKER, C. K. WARNER, R. J. PANCIERA, J. C. FOX, K. M. KOCAN, AND E. F. BLOUIN. 1995. Experimental transmission of *Ehrlichia chaffeensis* (Rickettsiales: Ehrlichiae) among white-tailed deer by *Amblyomma americanum* (Acari: Ixodidae).

- dae). *Journal of Medical Entomology* 32: 368–374.
- FISHBEIN, D. B., A. KEMP, J. E. DAWSON, N. R. GREENE, M. A. REDUS, D. H. FIELDS. 1989. Human ehrlichiosis: prospective active surveillance in febrile hospitalized patients. *Journal of Infectious Diseases* 159: 576–579.
- , J. E. DAWSON, L. E. ROBINSON. 1994. Human ehrlichiosis in the United States. *Annals of Internal Medicine* 120: 736–743.
- LITTLE, S. E., J. E. DAWSON, J. M. LOCKHART, D. E. STALLKNECHT, C. K. WARNER, AND W. R. DAVIDSON. 1997. Development and use of a specific polymerase chain reaction assay for the detection of an *Ehrlichia*-like organism in white-tailed deer (*Odocoileus virginianus*). *Journal of Wildlife Diseases* 33: 246–253.
- , D. E. STALLKNECHT, J. M. LOCKHART, J. E. DAWSON, AND W. R. DAVIDSON. 1998. Natural coinfection of a white-tailed deer (*Odocoileus virginianus*) population with three *Ehrlichia*. *The Journal of Parasitology* 84: In press.
- LOCKHART, J. M., W. R. DAVIDSON, J. E. DAWSON, AND D. E. STALLKNECHT. 1995. Temporal association of *Amblyomma americanum* with the presence of *Ehrlichia chaffeensis* antibodies in white-tailed deer. *Journal of Wildlife Diseases* 31: 119–124.
- , W. R. DAVIDSON, D. E. STALLKNECHT, AND J. E. DAWSON. 1996. Site-specific geographic association between *Amblyomma americanum* (Acari: Ixodidae) infestations and *Ehrlichia chaffeensis*-reactive (Rickettsiales: Ehrlichieae) antibodies in white-tailed deer. *Journal of Medical Entomology* 33: 153–158.
- , W. R. DAVIDSON, D. E. STALLKNECHT, J. E. DAWSON, AND S. E. LITTLE. 1997a. Natural history of *Ehrlichia chaffeensis* in the piedmont physiographic province of Georgia. *The Journal of Parasitology* 83: 887–894.
- , W. R. DAVIDSON, D. E. STALLKNECHT, J. E. DAWSON, AND E. W. HOWERH. 1997b. Isolation of *Ehrlichia chaffeensis* from wild white-tailed deer (*Odocoileus virginianus*) confirms their role as natural reservoir hosts. *Journal of Clinical Microbiology* 35: 1681–1686.
- MAEDA, K., N. MARKOWITZ, R. C. HAWLEY, M. RISTIC, D. COX, AND J. E. MCDADE. 1987. Human infection with *Ehrlichia canis*, a leukocytic rickettsia. *New England Journal of Medicine* 316: 853–856.
- STANDAERT, S. M., J. E. DAWSON, W. SCHAFFNER, J. E. CHILDS, K. L. BIGGIE, J. SINGLETON, JR., R. R. GERHARDT, M. L. KNIGHT, AND R. H. HUTCHESON. 1995. Ehrlichiosis in a golf-oriented retirement community. *New England Journal of Medicine* 333: 420–425.
- WALKER, D. H., AND J. S. DUMLER. 1996. Emergence of the ehrlichioses as human health problems. *Emerging Infectious Diseases* 2: 18–29.

*Received for publication 25 August 1998.*