

## **AN EPIZOOTIC OF FIBROMATOSIS IN GRAY SQUIRRELS (*SCIURUS CAROLINENSIS*) IN FLORIDA**

Authors: Terrell, Scott P., Forrester, Donald J., Mederer, Hyta, and Regan, Timothy W.

Source: Journal of Wildlife Diseases, 38(2) : 305-312

Published By: Wildlife Disease Association

URL: <https://doi.org/10.7589/0090-3558-38.2.305>

---

The BioOne Digital Library (<https://bioone.org/>) provides worldwide distribution for more than 580 journals and eBooks from BioOne's community of over 150 nonprofit societies, research institutions, and university presses in the biological, ecological, and environmental sciences. The BioOne Digital Library encompasses the flagship aggregation BioOne Complete (<https://bioone.org/subscribe>), the BioOne Complete Archive (<https://bioone.org/archive>), and the BioOne eBooks program offerings ESA eBook Collection (<https://bioone.org/esa-ebooks>) and CSIRO Publishing BioSelect Collection (<https://bioone.org/csiro-ebooks>).

Your use of this PDF, the BioOne Digital Library, and all posted and associated content indicates your acceptance of BioOne's Terms of Use, available at [www.bioone.org/terms-of-use](http://www.bioone.org/terms-of-use).

Usage of BioOne Digital Library content is strictly limited to personal, educational, and non-commercial use. Commercial inquiries or rights and permissions requests should be directed to the individual publisher as copyright holder.

---

BioOne is an innovative nonprofit that sees sustainable scholarly publishing as an inherently collaborative enterprise connecting authors, nonprofit publishers, academic institutions, research libraries, and research funders in the common goal of maximizing access to critical research.

## AN EPIZOOTIC OF FIBROMATOSIS IN GRAY SQUIRRELS (*SCIURUS CAROLINENSIS*) IN FLORIDA

Scott P. Terrell,<sup>1,2,5</sup> Donald J. Forrester,<sup>1</sup> Hyta Mederer,<sup>3</sup> and Timothy W. Regan<sup>4</sup>

<sup>1</sup> Department of Pathobiology, College of Veterinary Medicine, University of Florida, Gainesville, Florida 32611, USA

<sup>2</sup> Current address: Walt Disney World Animal Programs, Disney's Animal Kingdom, 1200 North Savannah Circle, Bay Lake, Florida 32830, USA

<sup>3</sup> Florida Wildlife Hospital and Sanctuary, Inc., 4560 North U.S. Highway 1, Melbourne, Florida 32935, USA

<sup>4</sup> Florida Fish and Wildlife Conservation Commission, 8535 Northlake Boulevard, West Palm Beach, Florida 33412, USA

<sup>5</sup> Corresponding author (e-mail: Scott.P.Terrell.-ND@disney.com)

**ABSTRACT:** Beginning in the fall of 1998 and extending into the spring and early summer of 1999 there was a large epizootic of squirrel fibromatosis in squirrels in seven counties in peninsular Florida. Hundreds of gray squirrels (*Sciurus carolinensis*) with multiple cutaneous tumors were submitted or reported to biologists, veterinary hospitals, and private wildlife rehabilitators. Most squirrels died or were euthanized soon after submission. Twenty squirrels were submitted for necropsy. The majority of the squirrels examined were adults (12/20) and male (15/20). The number and location of tumors varied widely among the affected squirrels; however, a consistent finding was involvement of the eyelids (20/20). Histopathology revealed a proliferative population of mesenchymal cells within the dermis and marked ballooning degeneration of keratinocytes in the overlying epidermis. Intracytoplasmic viral inclusions were present in the neoplastic mesenchymal cell population and the degenerating keratinocytes. Ulceration and necrosis of the surface of the tumors or associated tissues was present in 14 of the 20 squirrels. Virions consistent with poxvirus were observed via electron microscopy in samples collected from a representative tumor. Death of the squirrels was attributed to emaciation, tissue damage, and severe negative energy balance associated with poxvirus infection and massive tumor growth. The underlying cause of this unusual epizootic of fibromatosis in gray squirrels remains unknown.

**Key words:** epizootic, fibromatosis, Florida, gray squirrel, *Sciurus carolinensis*, squirrel poxvirus.

### INTRODUCTION

Free-ranging gray squirrels (*Sciurus carolinensis*) with cutaneous fibromas were first reported in Maryland in 1953 (Kilham et al., 1953). These virus induced fibromas are caused by a poxvirus in the genus *Leporipox* which also includes the myxoma and fibroma viruses of rabbits (Cheville, 1994). The disease is known as squirrel fibromatosis or squirrel pox. Tumors caused by squirrel fibroma virus often occur as multiple raised nodular lesions primarily located on the head and limbs (Kilham et al., 1953; Kilham, 1955; O'Connor et al., 1980; Yuill, 1981). Histologically, cutaneous lesions result from a combination of epidermal hyperplasia and dermal fibroblast proliferation (Kilham et al., 1953). Lesions associated with squirrel pox infection often spontaneously regress; however, animals may die when overwhelming numbers of tumors are present

or in cases where tumors cover the eyes interfering with vision and feeding.

Squirrel fibromatosis has been reported in many states within the range of gray squirrels. Most cases are reported in Maryland and other states along the eastern seaboard extending up to New York and Connecticut. The disease occurs infrequently in the southeastern United States (Davidson and Nettles, 1997). Squirrel fibromatosis has been seen in Florida only once previously, in Nassau County in northern Florida in 1972 (Forrester, 1992). Most reports of squirrel fibromatosis involve a single infected squirrel with a few reports describing disease in up to six animals (Kilham et al., 1953; Hirth et al., 1969). The previous report of fibromatosis from Florida was unusual in that a small epizootic was described (Forrester, 1992).

In this report we describe an epizootic of squirrel fibromatosis in southeastern

Florida. This report is unique due to the number of squirrels involved in the epizootic and the severity of the lesions observed in the affected squirrels.

### MATERIALS AND METHODS

Beginning in November 1998 and extending into July 1999, at least 69 cases of gray squirrels with multiple cutaneous tumors were reported to biologists of the Florida Fish and Wildlife Conservation Commission, private veterinarians, and wildlife rehabilitators in several counties of southeastern Florida. Exact records were not kept by most of the private veterinarians in the area and it is estimated that the actual number of squirrels affected was much greater than 69. Squirrels that were presented to veterinarians and rehabilitators often died or were euthanized due to severe debilitation. The chronology of the epizootic was determined by consulting the records of The Florida Wildlife Hospital (Melbourne, Brevard County, Florida, USA) and the phone logs of the Florida Fish and Wildlife Conservation Commission office (West Palm Beach, Palm Beach County, Florida). In order to better characterize the geographic extent of the epizootic, questionnaires were sent to 163 wildlife rehabilitators throughout the state of Florida who are active members of the Florida Wildlife Rehabilitators Association. In a letter that was sent with the questionnaire, the gross appearance of the disease was described and a photograph was provided. Information requested on the survey included numbers and species of squirrels seen or cared for from 1 November 1998 to 30 May 1999, numbers of squirrels seen with the disease, and the specific localities of diseased animals. In addition, rehabilitators were asked if they had seen this disease in previous years, and if so, which years and how many cases were seen.

Twenty squirrels from Brevard County ( $n = 18$ ) and Palm Beach County ( $n = 2$ ) were submitted for necropsy. Nineteen of the 20 squirrels were submitted dead. One squirrel was alive, but was extremely debilitated and died before any diagnostic tests were performed. The gender of each animal was recorded. Body weights and measurements of hindfoot length, body length, and tail length were recorded. Animals were grouped into broad age classes (juvenile vs. adult) based on hindfoot length (Larson and Taber, 1980). The distribution of skin lesions on each squirrel was diagrammed to determine the approximate percentage of body surface area covered by tumors. Lesions were then categorized as localized, multicentric, or diffuse. Animals with localized lesions had one

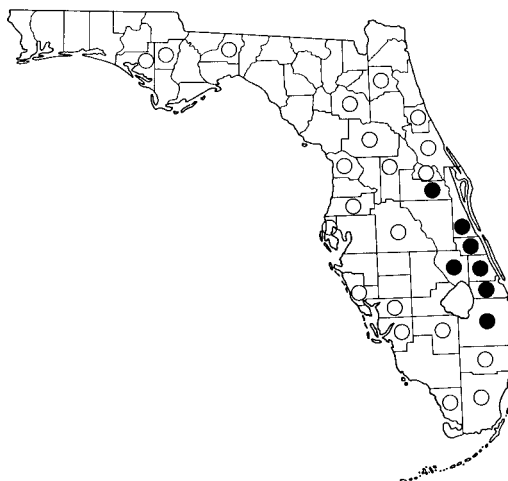


FIGURE 1. Distribution of the epizootic of fibromatosis in gray squirrels in Florida, November 1998 to July 1999. Solid circles indicate counties where positive squirrels were reported; open circles are counties in which squirrels were examined but found to be free of fibromatosis.

to three small ( $<1$  cm diameter) individual masses involving  $<10\%$  of the body surface area. Animals with multicentric lesions had four or more, often coalescing, tumors involving multiple sites on the body (20–70% of the body surface area affected). Animals with diffuse lesions had little or no uninvolved skin ( $>80\%$  of the body surface area affected). Photographs were taken of each squirrel examined for future reference to lesion distribution.

A complete necropsy was performed. Representative samples of skin lesions, regional lymph nodes, heart, lung, liver, kidney, and spleen were fixed in 10% buffered neutral formalin for histopathology. Sections for histopathology were embedded in paraffin, sectioned at 5  $\mu\text{m}$ , and stained with hematoxylin and eosin. Skin lesions were minced into 1 mm square pieces and placed into Trump's fixative for electron microscopy. Ultrathin sections for transmission electron microscopy were stained with 2% uranyl acetate and Reynolds lead citrate.

### RESULTS

Squirrels with cutaneous lesions consistent with squirrel fibromatosis were reported from seven counties in southeastern Florida, including Orange, Brevard, Indian River, Okeechobee, St. Lucie, Martin, and Palm Beach ( $26^{\circ}20'$  to  $28^{\circ}30'N$ ,  $80^{\circ}45'W$ ) (Fig. 1). Forty-eight of 163 (29.4%) questionnaires were returned.

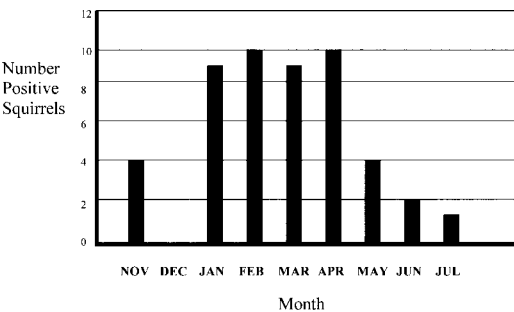


FIGURE 2. Chronology of fibromatosis in gray squirrels seen at the Florida Wildlife Hospital and Sanctuary in Brevard County, Florida from November 1998 to July 1999.

Seven rehabilitators reported having seen squirrels with lesions consistent with fibromatosis. Three of these reports were from Brevard County and one each was from Palm Beach County, St. Lucie County, Indian River County, and Orange County. We had previous evidence of diseased squirrels in all of these counties from personnel of the Florida Fish and Wildlife Conservation Commission. No rehabilitators outside the known range of the epizootic had seen diseased squirrels. The numbers of diseased squirrels seen each month at The Florida Wildlife Hospital are shown in Figure 2. The numbers peaked at nine or ten per month for a 4-mo period (January to April) and then declined.

Gross necropsy findings are summarized

in Table 1. Squirrels with multicentric disease had tumors on the eyelids and ears (Fig. 3a) and often had extensive involvement of the skin covering the front and hind limbs with less common involvement of the trunk (Fig. 3b). Ulceration of the surface of tumors in squirrels with multicentric disease was common (14/15). In five of the 15 squirrels with multicentric disease, tumors present on the hindlimb were associated with severe swelling, discoloration, and necrosis of the limb or foot distal to the tumor (Fig. 3c). Squirrels with diffuse disease had numerous coalescing tumors involving the head, ventrum, and limbs (Fig. 3d) or the tumors were of a diffuse infiltrative nature giving the skin a thickened cerebriform appearance. In addition to cutaneous lesions, emaciation was present in sixteen of 20 squirrels. These emaciated squirrels had grossly evident boney prominences and diffuse absence of subcutaneous and peritoneal adipose tissue.

The histopathologic characteristics of all skin lesions examined were similar and were characterized by moderate to marked hyperplasia of the epidermis with severe ballooning degeneration of keratinocytes in all levels of the epidermis and in follicular epithelium. Large (up to 20 μm in diameter) hypereosinophilic intracytoplasmic viral inclusions were common in the

TABLE 1. Summary of gross lesions in 20 gray squirrels in Florida with fibromatosis.

	Disease classification			Total (n = 20)
	Localized (n = 2)	Multicentric (n = 15)	Diffuse (n = 3)	
Males	1	11	3	15
Females	1	4	0	5
Adults	0	9	3	12
Juveniles	2	6	0	8
Eyelids affected	2	15	3	20
Ears affected	0	12	3	15
Surface ulceration	0	14	0	14
Lesions on limbs	0	12	3	15
Lesions on trunk	0	8	3	11
Distal limb/foot necrosis	0	5	0	5
Emaciation	0	13	3	16



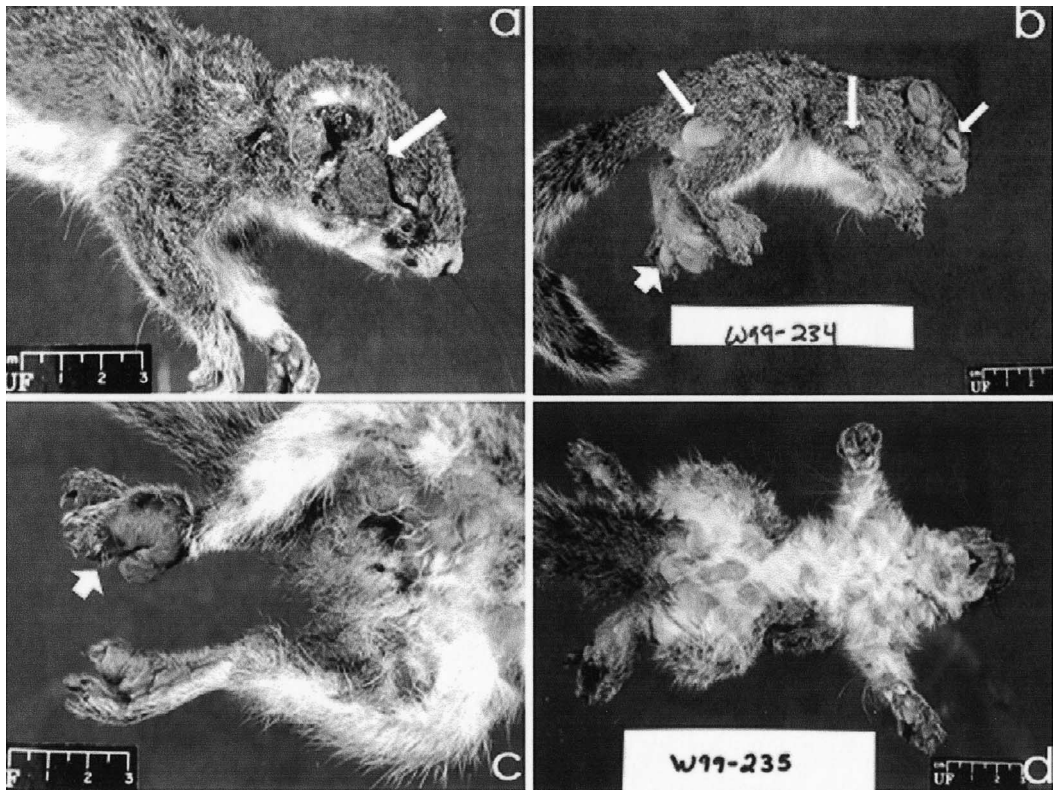


FIGURE 3. Poxvirus infection in gray squirrels from Florida. (a) Localized poxvirus lesion involving the lower eyelid (arrow). (b) Multicentric poxvirus lesions. Note tumors present on the eyelids and front and hindlimbs (thin arrows). There is marked swelling of the left hindfoot associated with tumor growth (short arrow). (c) Poxvirus lesions of the distal limb and foot. There is severe swelling, discoloration, and necrosis of the limb and foot (arrow). (d) Diffuse poxvirus lesions. Note the multiple coalescing tumors present on the ventrum as well as swelling of the left hindlimb.

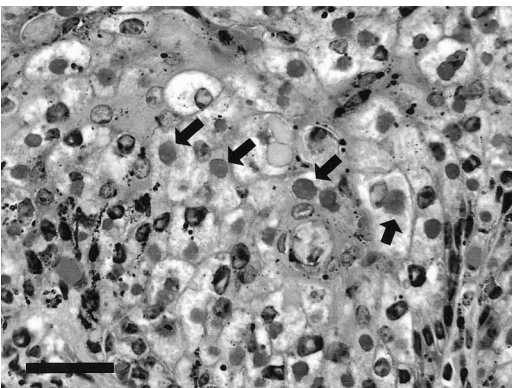


FIGURE 4. Epidermis of a gray squirrel infected with poxvirus. Large intracytoplasmic viral inclusions are common within degenerate swollen keratinocytes (arrows). HE. Bar = 50  $\mu$ m.

cytoplasm of degenerate keratinocytes (Fig. 4). Epidermal erosion and ulceration of varying severity were observed in all lesions examined. Bacterial colonization of the skin surface ranged from a few scattered small colonies of Gram positive cocci to massive colonization of ulcerated areas by mixed Gram positive and negative bacteria. Inflammatory infiltrates composed primarily of neutrophils subtended areas of erosion, ulceration, and bacterial colonization.

Within the dermis underlying the hyperplastic epidermis there was variable nodular proliferation of plump fibroblasts. In eight of 15 squirrels with multicentric disease proliferating fibroblasts formed dense bundles. In the remaining seven

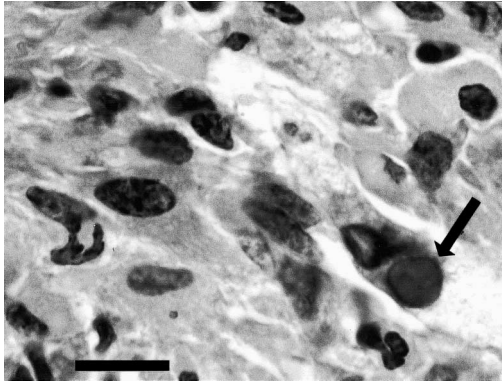


FIGURE 5. Subcutaneous nodule from a gray squirrel with fibromatosis. A large intracytoplasmic viral inclusion is present within a proliferating fibroblast (arrow). HE. Bar = 15  $\mu$ m.

squirrels fibroblasts were poorly organized and of low density giving the dermis a myxomatous appearance. Squirrels with localized small lesions on the eyelids had minimal fibroblast proliferation in the dermis. In squirrels with diffuse disease, fibroblasts often formed dense bands in the superficial dermis without evidence of nodule formation. Small (approximately 5  $\mu$ m in diameter) round hypereosinophilic intracytoplasmic viral inclusions were identified in scattered proliferating fibroblasts in twelve of 20 squirrels examined (Fig. 5). Mitotic figures were rare (<1/10 high power field) within the areas of fibroblast proliferation.

In the five squirrels exhibiting swelling and necrosis of a limb distal to a cutaneous tumor, multiple cross sections through the affected limb were examined. In all five squirrels there was diffuse coagulative necrosis of the skin, skeletal muscle, and deep fibrovascular tissues. Blood and lymphatic vessels were markedly dilated. Bacteria (primarily Gram positive cocci) penetrated deep into the necrotic tissue and occasionally were present within blood vessels. Cortical bone of the limbs and toes was necrotic.

A bundle of plump fibroblasts, similar to those observed in the dermis underlying cutaneous tumors, was present expanding the subcapsular sinus of an inguinal lymph

node of one squirrel. This lymph node was draining a foot with a large pox lesion present. Viral inclusions were not observed in these cells. Lesions associated with poxvirus infection were not observed in any other major organ examined (liver, spleen, kidney, lung, heart).

Oval virions approximately 300 nm in length consistent with poxvirus were identified in the cytoplasm of keratinocytes (Fig. 6, inset). Virions were characterized by a case, lateral bodies, and an external membrane. The central portion of virions was characterized by an hour glass appearance typical of poxviruses. Virions were numerous in infected cells. Cellular degeneration was characterized by cell swelling, loss of intercellular junctions, vacuolization of the cytoplasm, and loss of cytoplasmic organelles (Fig. 6). Poxvirions were also identified in scattered fibroblasts that contained cytoplasmic viral inclusions on histopathology.

## DISCUSSION

In describing this epizootic of fibromatosis, we have illustrated many of the classic characteristics of this viral disease of gray squirrels. At the same time, several clinical and pathologic findings in these squirrels were unusual or unique to this epizootic. The high morbidity and mortality of infected squirrels was unusual and differed from previous reports (Kilham et al., 1953; Kilham, 1955; O'Connor et al., 1980; Yuill, 1981). In most cases, death of squirrels was attributed to severe negative energy balance associated with massive tumor growth. Bacterial contamination of cutaneous lesions was common; however septicemia was not identified. Necrosis and sloughing of hindlimbs distal to tumors has not been described previously with fibromatosis. In these squirrels, lymphatic or blood vessel compression by the expansile tumors led to ischemic necrosis of the distal limb. These necrotic limbs were an excellent portal of entry for a variety of bacteria.

A common feature of infected squirrels



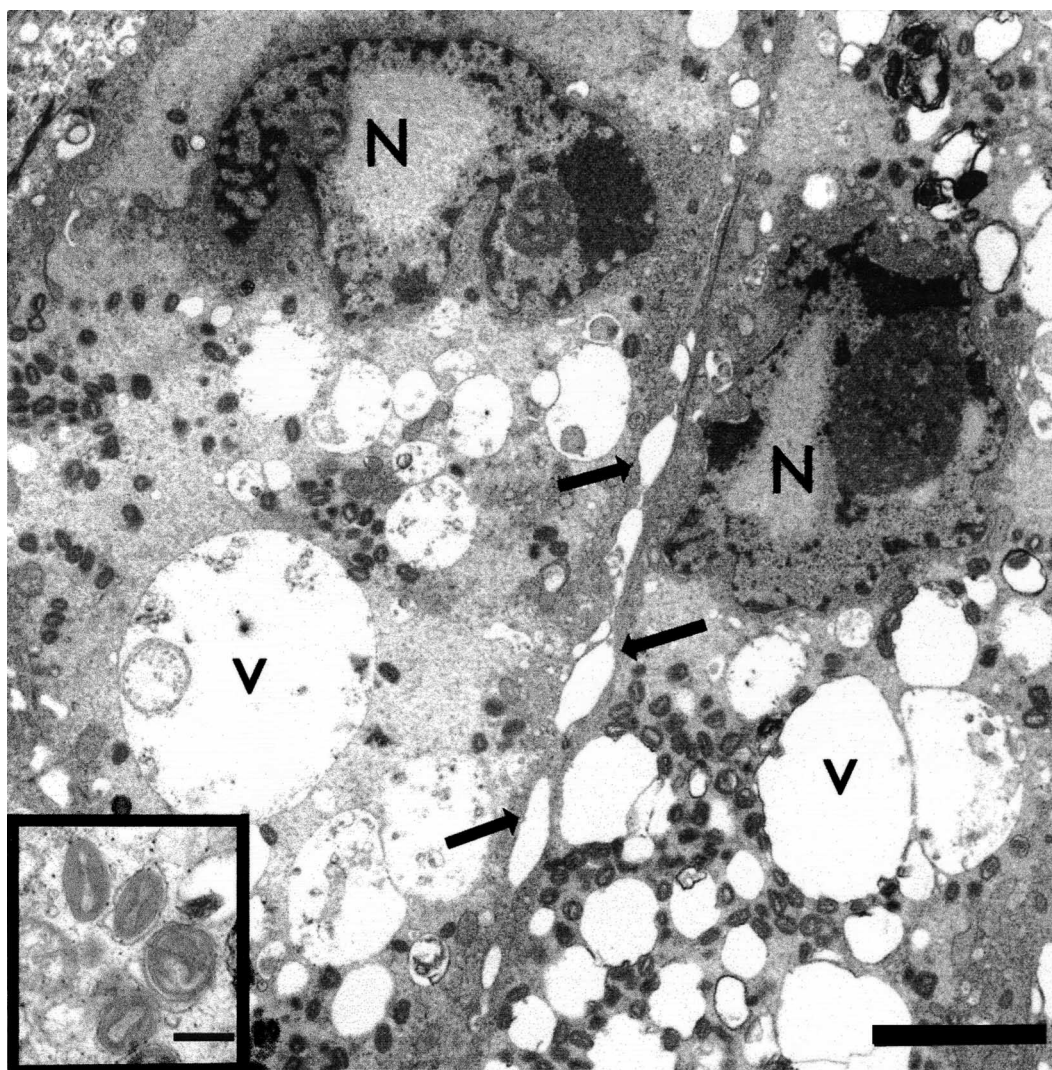


FIGURE 6. Two epidermal keratinocytes from a gray squirrel with fibromatosis. The nuclei are marked (N). Cellular degeneration is characterized by cell swelling, loss of intercellular junctions (arrows), vacuolization of the cytoplasm (v), and loss of cytoplasmic organelles. Large numbers of small oval poxvirions are visible in the cell cytoplasm. Transmission electron micrograph, uranyl acetate and lead citrate stain, bar = 2  $\mu$ m. Inset: Poxvirus within the cell cytoplasm, bar = 200 nm.

examined in this study was the presence of proliferative lesions on the eyelids. This may mean that the hairless regions of the eyelids are the site of initial inoculation of the virus by vectors such as mosquitoes. Selection of specific biting sites has been documented in many species of blood-feeding arthropods. Sand flies (*Culicoides* sp.) have a preference for feeding on mice in sites where hair densities are low such

as the eyelids, ears, nose, feet, and tail (Coleman and Edman, 1988). Certain mosquito species have also been observed to feed in areas of short, sparse hair (De Jong and Knols, 1996). The high prevalence of tumors on the eyelids, ears, limbs, and feet may mean that mosquitoes or fleas transmitting the poxvirus feed preferentially on those areas. Spread to other body sites is predominantly via viremia

(Robinson and Kerr, 2001). Virus could also be spread to multiple body sites by repeated feeding of the arthropod vector or by intensive grooming of the squirrel. Large numbers of fleas were common on infected squirrels and this may have facilitated spread of the virus from one body site to another and from squirrel to squirrel.

This epizootic of squirrel fibromatosis is unique from an epidemiologic standpoint. Fibromatosis typically occurs as a disease in a single animal or small clusters of animals (Kilham et al., 1953; Hirth et al., 1969). Forrester (1992) reported the only other epizootic of squirrel fibromatosis which occurred on Amelia Island, Florida. That report was based on anecdotal evidence and examination of only one affected squirrel. It is possible that epizootics of fibromatosis are common in squirrel populations, but given the gray squirrel's affinity for habitation near humans and the gross physical malformation of infected squirrels, we think it is unlikely that large numbers of tumor-ridden squirrels would go unnoticed by the public or wildlife professionals.

An epidemiologic curve was constructed to graphically represent this epizootic (Fig. 2). The epidemic pattern may be representative of a significant imbalance between the disease and the host, with the disease agent having a significant advantage. Such an imbalance is often present when a new disease agent is introduced either through mutation of a previously endemic agent or through introduction of a new disease agent (Martin et al., 1987). We considered several possible causes for the occurrence of the disease in epizootic form: (1) Introduction of a novel poxvirus into an immunologically naïve population; (2) Occurrence of the disease during a time of high vector number or activity; (3) Occurrence of the disease in a very dense population of squirrels facilitating spread of the virus. There are no data available to definitively support or refute any of these possibilities.

Vector activity may have played a role in this epizootic. Veterinarians and rehabilitators working with infected squirrels reported that large numbers of fleas were present on most of the animals examined. Fleas are vectors of poxvirus in wild rabbits (Allan and Shanks, 1955). Fleas such as the squirrel flea (*Orchopeus howardi*) are suspected to be involved in transmission of poxvirus in wild squirrels (Robinson and Kerr, 2001). The large numbers of fleas present on infected squirrels may have transmitted poxvirus to squirrels in close contact with one another or to squirrels using similar feeding or nesting areas.

The effect of this epizootic on gray squirrel populations in southeastern Florida is unknown. To our knowledge there have been no reports of declines in squirrel populations in southeastern Florida since the epizootic. It is unlikely the epizootic will have any lasting negative effects on this highly fecund species. Individual cases of fibromatosis are still occasionally observed in Brevard and Palm Beach counties and it appears the virus is endemic in that area similar to other areas within the gray squirrel's range.

#### ACKNOWLEDGEMENTS

We thank P. Ginn for her assistance and expertise in preparation of this manuscript and G. Foster for his assistance during necropsy and data collection. We also thank members of the Florida Wildlife Rehabilitators Association for their assistance in determining the distribution of the disease. The core electron microscopy laboratory at the University of Florida provided assistance with transmission electron micrographs. The research was supported by the Florida Agricultural Experiment Station, and approved for publication as Journal Series No. R-08050

#### LITERATURE CITED

- ALLAN, R. M., AND P. L. SHANKS. 1955. Rabbit fleas on wild rabbits and the transmission of myxomatosis. *Nature* 175: 692–698.
- CHEVILLE, N. F. 1994. Ultrastructural pathology: An introduction to interpretation. Iowa State University Press, Ames, Iowa. pp. 492–502.
- COLEMAN, R., AND J. D. EDMAN. 1988. Feeding site selection of *Lutzomyia longipalpis* (Diptera:



- Pshchodidae) on mice infected with *Leishmania mexicana amazonensis*. *Journal of Medical Entomology* 25: 229–233.
- DAVIDSON, W. R., AND V. F. NETTLES. 1997. Field manual of wildlife diseases in the southeastern United States, 2nd Edition, Southeastern Cooperative Wildlife Disease Study, University of Georgia, Athens, Georgia, 417 pp.
- DE JONG, R., AND B. G. J. KNOLS. 1996. Selection of biting sites by mosquitoes. CIBA foundation symposium: Olfaction in mosquito host interactions 200: 89–103.
- FORRESTER, D. J. 1992. Parasites and diseases of wild mammals in Florida. University Press of Florida, Gainesville, Florida, 459 pp.
- HIRTH, R. S., D. S. WYAND, A. D. OSBORNE, AND C. N. BURKE. 1969. Epidermal changes caused by squirrel poxvirus. *Journal of American Veterinary Medical Association* 155: 1120–1125.
- KILHAM, L. 1955. Metastasizing viral fibromas of gray squirrels: Pathogenesis and mosquito transmission. *American Journal of Hygiene* 61: 55–63.
- , C. M. HERMAN, AND E. R. FISCHER. 1953. Naturally occurring fibromas of gray squirrels related to Shope's rabbit fibroma. *Proceedings of the Society of Experimental Biology and Medicine* 82: 298–301.
- LARSON, J. S., AND R. D. TABER. 1980. Criteria of sex and age. In *Wildlife management techniques manual*, 4th Edition, S.D. Schemnitz (ed.). The Wildlife Society, Washington, D.C., pp. 143–202.
- MARTIN, S. W., A. H. MEEK, AND P. WILLEBERG. 1987. *Veterinary epidemiology*. Iowa State University Press, Ames, Iowa, 343 pp.
- ROBINSON, A. J., AND P. J. KERR. 2001. Poxvirus infections. In *Infectious diseases of wild mammals*, 3rd Edition, E. S. Williams and I. K. Barker (eds.). Iowa State University Press, Ames, Iowa, pp. 179–201.
- O'CONNOR, D. J., R. W. DITERS, AND S. W. NIELSON. 1980. Poxvirus and multiple tumors in an eastern gray squirrel. *Journal of the American Veterinary Medical Association* 177: 792–795.
- YUILL, T. M. 1981. Myxomatosis and fibromatosis. In *Infectious diseases of wild mammals*, 2nd Edition, J. W. Davis, L. H. Karstad and D. O. Trainer (eds.). Iowa State University Press, Ames, Iowa, pp. 154–177.

*Received for publication 22 March 2001.*