



Parelaphostrongylus tenuis in Captive Pronghorn Antelope (*Antilocapra americana*) in Nebraska

Authors: Simmons, Heather A., Steffen, David J., Armstrong, Douglas L., and Rogers, Douglas G.

Source: Journal of Wildlife Diseases, 38(4) : 822-825

Published By: Wildlife Disease Association

URL: <https://doi.org/10.7589/0090-3558-38.4.822>

BioOne Complete (complete.bioone.org) is a full-text database of 200 subscribed and open-access titles in the biological, ecological, and environmental sciences published by nonprofit societies, associations, museums, institutions, and presses.

Your use of this PDF, the BioOne Complete website, and all posted and associated content indicates your acceptance of BioOne's Terms of Use, available at www.bioone.org/terms-of-use.

Usage of BioOne Complete content is strictly limited to personal, educational, and non - commercial use. Commercial inquiries or rights and permissions requests should be directed to the individual publisher as copyright holder.

BioOne sees sustainable scholarly publishing as an inherently collaborative enterprise connecting authors, nonprofit publishers, academic institutions, research libraries, and research funders in the common goal of maximizing access to critical research.

***Parelaphostrongylus tenuis* in Captive Pronghorn Antelope (*Antilocapra americana*) in Nebraska**

Heather A. Simmons,^{1,4} David J. Steffen,² Douglas L. Armstrong,³ and Douglas G. Rogers^{2,1} Animal Health Diagnostic Laboratory and Department of Pathobiology and Diagnostic Investigation, Michigan State University, P.O. Box 30076, Lansing, Michigan 48909, USA; ² Veterinary Diagnostic Laboratory, University of Nebraska, Lincoln, Nebraska 68583-0907, USA; ³ Henry Doorly Zoo, Omaha, Nebraska 68107, USA; ⁴ Corresponding author (email: simmons@ahdl.msu.edu)

ABSTRACT: Lesions in four captive pronghorn antelope (*Antilocapra americana*) naturally infected with *Parelaphostrongylus tenuis* in eastern Nebraska (USA) are described in this report. Animals were bright and alert with hind limb ataxia that progressed to sternal or lateral recumbency between July 28 and October 17, 1998. Animals were euthanized due to disease progression despite therapy. Multifocal decubital ulcers over bony prominences occurred in two animals and chronic unilateral otitis media was present in one animal. Histopathologic examination revealed severe Wallerian degeneration randomly scattered throughout the spinal cords of all four animals. Spinal cord sections from two animals contained adult nematode parasites consistent with *P. tenuis*. This is the first report of naturally occurring *P. tenuis* infection in pronghorn antelope. Pronghorn antelope should be considered susceptible to *P. tenuis* infection and contact with infected white-tailed deer as well as intermediate gastropod hosts of *P. tenuis* should be prevented in endemic areas.

Key words: *Antilocapra americana*, gastropod, meningeal worm, *Odocoileus virginianus*, *Parelaphostrongylus tenuis*, pronghorn antelope, white-tailed deer.

The meningeal worm (*Parelaphostrongylus tenuis*) is a common parasite of white-tailed deer (*Odocoileus virginianus*) in eastern North America and has been identified in deer populations throughout eastern Nebraska (Oates et al., 1999). This metastrongyle nematode is found within the subdural space and venous sinuses of the cranium. Infection in white-tailed deer may be subclinical or result in transient morbidity. In contrast, infection in other ungulate species often causes severe morbidity and mortality (Anderson and Prestwood, 1981).

Infection by *P. tenuis* occurs when grazing hosts ingest gastropods carrying infective L3 larvae. Infective larvae penetrate

the abomasum and migrate to the spinal cord in approximately 10 days. Larvae invade dorsal horns of the spinal cord where they develop into subadults. Approximately 40 days postexposure, larvae migrate cranially into the cranial subdural space, where they mature into adult worms. Female worms deposit eggs on the meninges and into venous sinuses. Venous circulation carries eggs and first stage larvae (L1) to the lungs, where L1 penetrate alveoli, and are coughed up and swallowed. First stage larvae pass out of the deer in the mucus coat surrounding the fecal pellet. These larvae penetrate the foot of a gastropod intermediate host where they ultimately develop into L3 larvae (Anderson and Prestwood, 1981).

Parelaphostrongylus tenuis infection has been identified in moose (*Alces alces*), caribou (*Rangifer tarandus tarandus*), reindeer (*Rangifer tarandus terraenovae*), wapiti (*Cervus elaphus*), mule deer (*Odocoileus hemionus*), black-tailed deer (*Odocoileus hemionus columbianus*), fallow deer (*Dama dama*), eland (*Taurotragus oryx*), domestic sheep, domestic goats, guinea pigs, (Anderson and Prestwood, 1981), sable antelope (*Hippotragus niger*), scimitar-horned oryx (*Oryx dammah*) (Ferrell et al., 1997), bighorn sheep (*Ovis canadensis*) (Pybus et al., 1996), blackbuck antelope (*Antelope cervicapra*), llama (*Lama glama*), camels (*Tylopoda* sp.) (Oliver et al., 1992), and bongo (*Tragelaphus eurycerus*) (Rowley et al., 1987). Severe neurologic signs were produced in experimentally infected pronghorn antelope (*Antilocapra americana*) (Tyler and Hibler cited by Anderson and Prestwood, 1981). This is the first report of naturally occur-

ring *P. tenuis* infection in pronghorn antelope.

All medical and pathology reports for pronghorn antelope displayed at the Lee G. Simmons Conservation Park and Wildlife Safari (Nebraska, 41°00'609"N, 96°17'895"W) were reviewed for this report. The Wildlife Safari was established for the exhibition of native Nebraska wildlife and for the conservation of rare and endangered exotic species. The 178 ha park was habitat for white-tailed deer prior to construction of the park perimeter with a 2.4 m woven wire fence in 1997. The facility has seven wetland areas, including two reclaimed rock quarries and is bisected by a permanent natural creek. Pronghorn antelope were housed in a 22 ha pasture with a herd of 35 elk and two mule deer. White-tailed deer occupied an adjacent pen separated by a common fence.

Four pronghorn antelope developed rear limb ataxia that progressed to sternal and/or lateral recumbency between 28 July and 17 October 1998. Animals were bright and alert but had gait and posture abnormalities that were most prominent when walking or standing. One had a right head tilt.

Serum chemistries and complete blood counts were performed on all affected animals. Abnormalities were consistent with prolonged recumbency. Analysis of cerebral spinal fluid from the first pronghorn antelope with clinical signs revealed mononuclear inflammatory cells. All affected animals were treated with combinations of antibiotics, steroids, and anthelmintics. Three of the four pronghorn antelope were euthanized several weeks after onset of clinical signs. The fourth pronghorn antelope responded to therapy and was placed with the herd for several months after treatment. However, she was ultimately euthanized 21 October 1999, due to increasing hind limb weakness and a reluctance to walk or stand.

Two animals had multifocal decubital ulcers over bony prominences. The pronghorn antelope that had displayed a head

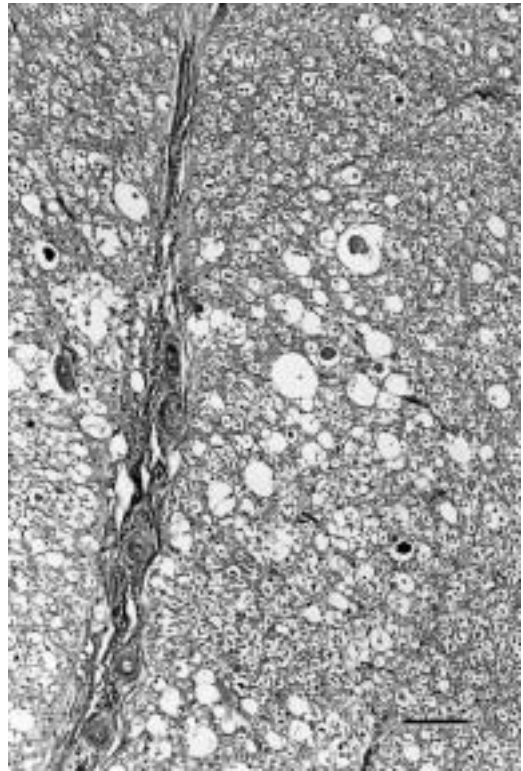


FIGURE 1. Photomicrograph of spinal cord from a pronghorn antelope with *Parelaphostrongylus tenuis* infection showing severe Wallerian degeneration and axonal spheroids. HE stain. Bar=100 μ m.

tilt had chronic otitis media. *Pseudomonas aeruginosa* was isolated from the tympanic bulla. No additional significant gross lesions were noted.

Histopathologic examination of hematoxylin and eosin stained sections of formalin fixed, paraffin embedded tissues, revealed severe Wallerian degeneration randomly scattered throughout dorsal horns and ventral funiculi of spinal cord sections of all four animals. Large axonal spheroids, gliosis, and loss of myelin were prominent. (Fig. 1) One animal also had foci of demyelination, spongy degeneration, and gliosis in the cerebellar folia. Two of the four animals had cross sections of nematode parasites consistent *P. tenuis* (Chitwood and Lichtenfels, 1972) within sections of spinal cord (Fig. 2). Parasites and tissues are in the University of Nebraska, Veteri-

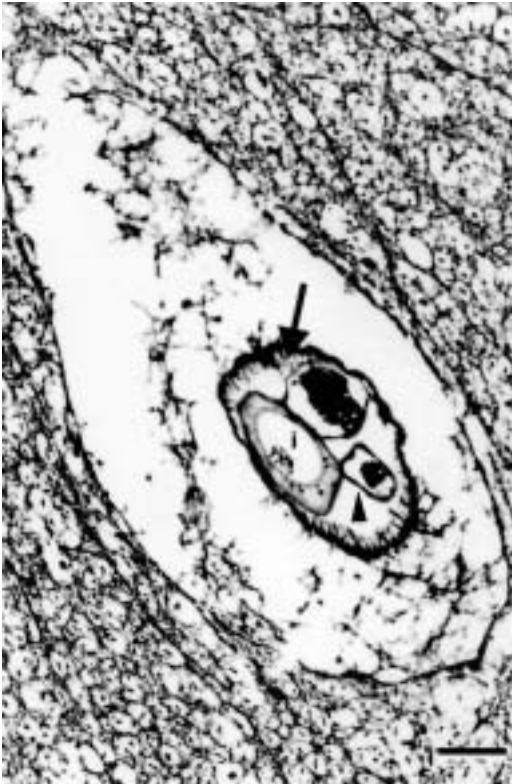


FIGURE 2. Photomicrograph of a cross section of *Parelaphostrongylus tenuis* demonstrating characteristic polymyarian musculature (arrow) Intestinal tract (i) and reproductive organ (arrowhead). HE stain. Bar=20 μ m.

nary Diagnostic Center Collection (Accession number 11327-99).

There are marked differences in host response to infection with *P. tenuis*. White-tailed deer are definitive hosts and seldom display clinical signs. Few gross lesions are reported in white-tailed deer and histologic lesions are usually mild with little cellular reaction around worms in the neuropil. Malacia is not usually seen in infected white-tailed deer. This is in marked contrast to experimentally and naturally infected aberrant hosts (Anderson and Prestwood, 1981).

Migratory behavior of *P. tenuis* has been implicated in the severity of clinical signs seen in aberrant hosts. Worm migration within neural tissue other than the dorsal horns of the spinal cord was seen in two

of four pronghorns infected at the Wildlife Safari and has also been noted in moose (Anderson and Prestwood, 1981), fallow deer (Pybus et al., 1992), bighorn sheep (Pybus et al., 1996), domestic sheep (Jortner et al., 1985), and blackbuck antelope (Oliver et al., 1996).

Zoological institutions, wildlife parks, game managers, and captive wildlife hobbyists should include pronghorn antelope on the list of species highly susceptible to *P. tenuis* infection. The number of native and exotic species susceptible to disease caused by this parasite has led to management recommendations by many institutions in endemic areas. Recommendations for the National Zoological Park's Conservation and Research Center (CRC; Front Royal, Virginia, USA) included construction of high-tensile deer fences, to exclude white-tailed deer and prevent gastropod infection with *P. tenuis*, as well as vegetation-free gravel barriers around paddocks, to prevent the entrance of infected gastropods into areas that house susceptible species (Rowley et al., 1987).

The remaining pronghorn antelope at the Wildlife Safari were moved to a pasture in another portion of the park. Herbicide control of foliage along fence lines to prevent gastropod movement into the pen was recommended as a less expensive alternative to gravel barriers. There have been no clinical signs in any of the remaining pronghorn antelope, or the elk and mule deer that shared pasture with the affected antelope in the 3 yr since the initial diagnosis of parelaphostrongylosis.

LITERATURE CITED

- ANDERSON, R. C., AND A. K. PRESTWOOD. 1981. Lungworms. In *Diseases and parasites of white-tailed deer*, W. R. Davidson, F. A. Hayes, V. F. Nettles and F. E. Kellogg, (eds.). Tall Timbers Research Station, Miscellaneous Publications No. 7, Tallahassee, Florida, pp. 226-317.
- CHITWOOD, M., AND J. R. LICHTENFELS. 1972. Identification of parasite metazoa in tissue sections. *Experimental Parasitology* 32: 407-519.
- FERRELL, S. T., L. K. RICHMAN, M. BUSH, R. J. MONTALI, AND L. TELL. 1997. Clinical challenge.

- Journal of Zoo and Wildlife Medicine 28: 221–223.
- JORTNER, B. S., H. F. TROUTT, T. COLLINS, AND K. SCARRATT. 1985. Lesions of spinal cord parelaphostrongylosis in sheep. Sequential changes following intramedullary larval migration. Veterinary Pathology 22: 137–140.
- OATES, D. W., M. C. STERNER, AND D. J. STEFFEN. 1999. Meningeal worm in free-ranging deer in Nebraska. Journal of Wildlife Diseases 35: 101–104.
- OLIVER, J. L., S. R. TROSCLAIR, J. M. MORRIS, D. B. PAULSEN, D. E. DUNCAN, D. Y. KIM, A. C. CAMUS, T. J. VICEK, AND M. C. NASARRE. 1996. Neurologic disease attributable to infection with *Parelaphostrongylus tenuis* in blackbuck antelope. Journal of the American Veterinary Medical Association 209: 140–142.
- PYBUS, M. J., W. M. SAMUEL, D. A. WELCH, J. SMITS, AND J. C. HAIGH. 1992. Mortality of fallow deer (*Dama dama*) experimentally-infected with meningeal worm, *Parelaphostrongylus tenuis*. Journal of Wildlife Diseases 28: 95–101.
- , S. GROOM, AND W. M. SAMUEL. 1996. Meningeal worm in experimentally-infected bighorn and domestic sheep. Journal of Wildlife Diseases 32: 614–618.
- ROWLEY, M. A., E. S. LOKER, J. F. PAHEL, AND R. J. MONTALI. 1987. Terrestrial gastropod hosts of *Parelaphostrongylus tenuis* at the National Zoological Park's Conservation and Research Center, Virginia. Journal of Parasitology 73: 1084–1089.

Received for publication 30 December 2001.