

# **HEALTH STATUS OF HARP SEALS (PHOCA GROENLANDICA) AND HOODED SEALS (CYSTOPHORA CRISTATA) ON SABLE ISLAND, NOVA SCOTIA, CANADA, CONCURRENT WITH THEIR EXPANDING RANGE**

Authors: Lucas, Zoe, Daoust, Pierre-Yves, Conboy, Gary, and Brimacombe, Michael

Source: Journal of Wildlife Diseases, 39(1) : 16-28

Published By: Wildlife Disease Association

URL: <https://doi.org/10.7589/0090-3558-39.1.16>

---

The BioOne Digital Library (<https://bioone.org/>) provides worldwide distribution for more than 580 journals and eBooks from BioOne's community of over 150 nonprofit societies, research institutions, and university presses in the biological, ecological, and environmental sciences. The BioOne Digital Library encompasses the flagship aggregation BioOne Complete (<https://bioone.org/subscribe>), the BioOne Complete Archive (<https://bioone.org/archive>), and the BioOne eBooks program offerings ESA eBook Collection (<https://bioone.org/esa-ebooks>) and CSIRO Publishing BioSelect Collection (<https://bioone.org/csiro-ebooks>).

Your use of this PDF, the BioOne Digital Library, and all posted and associated content indicates your acceptance of BioOne's Terms of Use, available at [www.bioone.org/terms-of-use](http://www.bioone.org/terms-of-use).

Usage of BioOne Digital Library content is strictly limited to personal, educational, and non-commercial use. Commercial inquiries or rights and permissions requests should be directed to the individual publisher as copyright holder.

---

BioOne is an innovative nonprofit that sees sustainable scholarly publishing as an inherently collaborative enterprise connecting authors, nonprofit publishers, academic institutions, research libraries, and research funders in the common goal of maximizing access to critical research.

# HEALTH STATUS OF HARP SEALS (*PHOCA GROENLANDICA*) AND HOODED SEALS (*CYSTOPHORA CRISTATA*) ON SABLE ISLAND, NOVA SCOTIA, CANADA, CONCURRENT WITH THEIR EXPANDING RANGE

Zoe Lucas,<sup>1</sup> Pierre-Yves Daoust,<sup>2,5</sup> Gary Conboy,<sup>2</sup> and Michael Brimacombe<sup>3,4</sup>

<sup>1</sup> P.O. Box 64, Halifax CRO, Halifax, Nova Scotia B3J 2L4, Canada

<sup>2</sup> Canadian Cooperative Wildlife Health Centre, Department of Pathology & Microbiology, Atlantic Veterinary College, University of Prince Edward Island, Charlottetown, Prince Edward Island C1A 4P3, Canada

<sup>3</sup> Department of Health Management, Atlantic Veterinary College, University of Prince Edward Island, Charlottetown, Prince Edward Island C1A 4P3, Canada

<sup>4</sup> Current address: Department of Preventive Medicine, New Jersey School of Medicine, University of Medicine and Dentistry of New Jersey, East Orange, New Jersey 07018, USA

<sup>5</sup> Corresponding author (email: daoust@upe.ca)

**ABSTRACT:** Beach surveys for harp (*Phoca groenlandica*) and hooded (*Cystophora cristata*) seals documented a dramatic increase in their numbers on Sable Island in mid 1990s. In the 1980s, no more than five animals of both species were observed on this island each year, however, during late 1994 to 1998, 1,191 harp and 870 hooded seals, mostly young animals, were recorded. Although some of these seals had been killed by sharks, most (roughly 75%) were found alive or as intact carcasses on the beach, and some of the live seals were later found dead. Emaciation/starvation was considered the primary cause of death in seals that were not obviously killed by sharks. Factors that may have compounded this poor body condition included gastric impaction with abnormal ingesta, hemorrhagic diathesis possibly induced by parasitic migration and secondary vasculitis, and stomatitis (in hooded seals only). Some harp and hooded seals expanding their range in recent years may be unable to feed successfully, although the reasons for this are unclear.

**Key words:** *Cystophora cristata*, emaciation, harp seal, health, hooded seal, *Phoca groenlandica*.

## INTRODUCTION

Harp seals (*Phoca groenlandica*) and hooded seals (*Cystophora cristata*) are ice-breeding species which migrate annually between the subarctic and arctic regions of the North Atlantic Ocean. Harp seals in the northwest Atlantic are normally found no farther south than the Gulf of St. Lawrence (approximately 47°N) (Sergeant, 1991). Hooded seals are a more offshore species, again not usually found south of the Gulf of St. Lawrence (Hammill, 1993). However, Stevick and Fernald (1998) and McAlpine et al. (1999a, b) reported an unprecedented increase in numbers of harp and hooded seals in the northern Gulf of Maine in the 1990s, particularly since 1994. These seals were recorded annually between late January and mid May, involved a high proportion of immature animals, and seemed to include a mixture of healthy animals and animals in poor

health. McAlpine et al. (1999a) also noted that harp and hooded seals had increased along the Atlantic coast of Nova Scotia and the New England states. They concluded that the collapse of fish stocks in the western North Atlantic in recent years, concurrent with an increase in size of harp and hooded seal populations resulting from decreased commercial harvest of these two species, could explain the sudden increase in extralimital distribution. The influence of other biologic and physical factors, however, is suggested by recent changes in meteorologic and hydrographic conditions which may have affected the distribution of prey species (Bowring, 2000; Carscadden et al., 2001).

Sable Island is an isolated offshore sandbar, 42 km long, located in the western North Atlantic at about 44°N and 60°W, approximately 160 km southeast of Canso, Nova Scotia (Canada), the nearest landfall. During the mid 1990s, there was a large

increase in numbers of harp and hooded seals on Sable Island. Between December 1994 and May 1998, 2,061 seals (1,191 harp, 870 hooded) were recorded during beach surveys, whereas, during the 1980s, no more than five alive and dead harp and hooded seals (combined) were observed each year (Lucas and Daoust, 2002). These 2,061 seals included live animals (41.7%) and carcasses found on the beach with (26.7%) and without (31.6%) evidence of fatal shark attack (Lucas and Daoust, 2002). Of 859 seals of both species and of all ages found alive, 197 (22.9%) were later found dead. The majority of harp and hooded seals found were immature (88.1% and 94.2%, respectively). Most immature harp seals were likely 10–14 mo old, and most immature hooded seals were likely 3 yr old or younger (Lucas and Daoust, 2002). The beach survey program on Sable Island provided an opportunity to gather further information on harp and hooded seals involved in extralimital distribution. In particular, little is known about diseases that may affect these two species, and the potential for serious outbreaks of infectious diseases in seals, such as phocine distemper and influenza, is now well recognized (Geraci et al., 1982; Duignan et al., 1997; Kennedy, 1998). Therefore, studies of causes of mortality in these animals are warranted. This article reports observations on the health status of harp and hooded seals on Sable Island between December 1994 and May 1998.

#### MATERIALS AND METHODS

Beach surveys for harp and hooded seals were carried out on Sable Island during December through May from December 1994 to May 1998 by the senior author. All 80 km of the island's beach were searched at approximately 7 day intervals, except during several periods of 3 wk annually when the observer was off island. The survey effort and timing were roughly the same during each of the 4 yr. While surveys and markings of live harp and hooded seals were not carried out during June through November, travel and activity on the beach for other projects continued at a similar level of effort, and records were kept of the occasional

harp and hooded seals sighted. Seals were grouped into three age categories: pups (1–3 mo old, born in March or April of the same year that they were found on Sable Island); immatures (10 mo to approximately 4 yr old, the youngest born in March or April of the year prior to the year that they were found on the island); and adults (Lucas and Daoust, 2002).

During December through May, live young seals were captured on the beach and individually marked with animal marking crayons of different colors (Viehzeichenstift Raidex, Kane Veterinarians Supplies, Cambridge, Ontario, Canada) before release. Manual restraint of young harp seals was achieved easily because they quickly assume a state of paralysis when attacked by predators or approached or handled by humans, presumably as a defense mechanism (Lydersen and Kovacs, 1995). Although more aggressive upon first contact, young hooded seals respond in a similar manner to capture (Lucas and Daoust, unpubl. data). This reaction precluded evaluation of the degree of vigor of live seals following capture, except in cases of extreme weakness. Adult seals were not captured and marked, but in most cases it was possible to identify them on the basis of pelage pattern characteristics. The fate of marked or otherwise identified seals, i.e., whether found again alive or dead, or not found on subsequent days, was recorded. Identification of a live young harp seal 39 days after its first sighting indicated that the crayon marks persisted on the animals long enough to serve the purpose of this study (Lucas and Daoust, 2002). In January–March 1997 and 1998, the pattern and degree of bleeding evident externally on young seals when captured were also recorded, the amount of blood observed being ranked on a scale of 0 to 3 (0, no blood; 1, blood visible as droplets at base of <30% of vibrissae, no blood on the nail beds of flippers; 2, blood visible as droplets at base of >30% of vibrissae and in small amounts at the nail beds of flippers; 3, distinct confluence of blood droplets seeping from the bases of vibrissae and from the nail beds of flippers).

Dead seals, comprising both those that died on the beach after coming ashore alive and those that washed ashore as carcasses were also examined. These animals were divided into two groups: killed by sharks (KBS) and showing deep wounds, massive loss of tissue and/or evidence of hemorrhage, and intact carcasses for which the cause of death was not evident from external examination. Of the intact carcasses, most were examined superficially on the beach (ESB), and some were retained to be examined in detail at necropsy (EDN). Fatal wounds caused by shark predation were distinguished

from scavenging by sharks by the presence of characteristic patterns of punctures and cuts (Lucas, unpubl. data). Depending on the condition of the seal carcass (e.g., presence of injuries, scavenging or decomposition), measurements were taken following the recommendations of the American Society of Mammalogists (1967). Information recorded included sex, size (standard length, axillary girth), and blubber thickness (mid-dorsal and/or sternal). Normal values of 35–45 mm for sternal blubber thickness in immature harp seals (10 mo to <5 yr old, collected in the northwest Atlantic, at approximately 52°N and 55°W, between January and March) were obtained from Chabot et al. (1996: Fig. 7). Comparable values were not available for hooded seals. Stomachs were collected from some carcasses for examination of their contents.

Over the course of three seasons (February 1995, March 1996, February–March 1998), a necropsy was done on the intact carcasses (EDN) of 28 immature harp seals and 42 immature hooded seals found on the beach in a good state of preservation (code 2, based on criteria of Geraci and Lounsbury, 1993). Samples of the following tissues from 24 of the 28 harp seals and 37 of the 42 hooded seals were processed routinely for histologic examination: brain, heart, lung, stomach, liver, kidney, thyroid, adrenal, and skeletal muscle. All samples were fixed in 10% buffered formalin, dehydrated in graded alcohol and xylene, and embedded in paraffin; 5  $\mu$ m-thick sections were stained with hematoxylin and eosin. Samples of lung, liver and kidney from eight harp seals and 10 hooded seals examined in winter 1996 were frozen at –20 C for <3 wk before being processed for bacteriologic examination. These tissues were cultured at 35 C in 5% CO<sub>2</sub> on 5% sheep blood and MacConkey agars, and bacterial isolates were identified by standard methods (Quinn et al., 1994). Grossly visible helminths recovered from the heart and lungs at necropsy were fixed in 10% buffered formalin. Some stomachs were frozen at –20 C and stored for later examination in the laboratory. Nematodes recovered from the stomach were fixed in hot (63 C) AFA (70% ethanol, 10% formalin, 5% glacial acetic acid). The left lungs of six EDN harp seals and 12 EDN hooded seals in winter 1998 were examined for nematode parasites using the modified Inderbitzen lung flush technique (Oakley, 1980). Briefly, a tube connected to a water tap was inserted into the pulmonary artery. The tap was turned on, inflating the lung with water which exited through the primary bronchus onto a 250  $\mu$ m (60 mesh) geological sieve (Fisher Scientific, Ottawa, Ontario). The contents collected on

the sieve were examined for parasites with a dissecting microscope. Worms were fixed in hot (63 C) AFA and transferred to lactophenol for identification. Due to fragmentation of many of the lungworms during recovery, adult anterior ends and male and female posterior ends were enumerated to determine the total worm counts. Voucher specimens were deposited in the Invertebrate Collection of the Canadian Museum of Nature (Ottawa, Canada; accession numbers: 2001-0055 for *Contracaecum osculatum*, 2001-0056 for *Filaroides* [*Parafilaroides*] *gymnurus* recovered from hooded seals, 2001-0057 for *F. gymnurus* recovered from harp seals). Voucher specimens of *Otostrongylus circumlitus* and *Acanthocheilonema spirocauda* were not available for deposition in the Museum collection.

For statistical analyses, sternal and mid-dorsal blubber thicknesses of KBS, ESB, and EDN carcasses of immature seals were compared using a one-way analysis of variance with Tukey's pairwise comparisons and a family-error rate of 0.05 (Spjøtvoll and Stoline, 1973). Standard lengths and axillary girths of ESB and EDN carcasses were compared using a two-sample *t*-test at a 0.05 level of significance. To avoid potential confusion with pups which can be found on the island in April and May (Lucas and Daoust, 2002), only seals found between December and March were used in these analyses.

## RESULTS

Examination of live seals and ESB/EDN carcasses revealed that 21 (3.4%) of 620 immature harp seals and 47 (5.9%) of 790 immature hooded seals had cutaneous cuts which, in roughly 50% of cases, were considered extensive (deep and/or numerous). While many such cuts appeared to have been inflicted by sharks, none of these were considered severe enough to have been the primary cause of death, although it is possible that death resulted from subsequent septicemia or internal hemorrhage. Six live and two dead immature harp seals and 10 live and one dead immature hooded seals were oiled on >10% of their body. Three seals, all alive, were entangled in marine debris: two immature harp seals had a loop of plastic strapping around their neck which had cut deeply into the soft tissues, and an immature hooded seal had a fragment of gillnet



FIGURE 1. Blood seeping from the base of vibrissae of a harp seal shortly after capture (grade 2—see Materials and Methods).

caught around its upper thorax and front flippers which had not yet cut through its skin. Thirty-five (5.6%) of 620 immature harp seals and 36 (4.6%) of 790 immature hooded seals had some degree of hair loss, involving >50% of the body surface in 16 of the harp seals and 20 of the hooded seals. Of these, one harp seal and nine hooded seals were almost entirely hairless.

Eighteen (2.3%) of 790 immature hooded seals had a severe suppurative stomatitis/gingivitis characterized by a large amount of pus in the mouth, particularly at the base of the teeth; in seven of these animals, one lower canine was missing and/or the mandibular symphysis had separated. Similar oral lesions were not observed in any of the immature harp seals.

Eighteen (21%) of 85 live immature harp seals and 29 (25%) of 115 live immature hooded seals examined in January–March 1997 and 1998 started to bleed from the bases of vibrissae and/or the nail beds as they were being restrained (Fig. 1). In some instances, bleeding began as the seal assumed a state of paralysis on being approached (i.e., before being handled). The amount of blood observed was grade 1 in two harp seals and 15 hooded seals, grade 2 in 13 harp seals and 12 hooded seals, and grade 3 in three harp

seals and two hooded seals. Eight harp seals from the original group of 85 animals and 28 hooded seals from the original group of 115 animals were later found dead. Of these, two (25%) harp seals and six (21%) hooded seals had bled at the time of the original capture. Only one of these animals, a hooded seal with grade 1 bleeding, was examined in detail at necropsy (found dead and examined the following day). No gross or microscopic lesions other than a thin blubber (sternal, 11 mm; mid-dorsal, 9 mm) and a few small gastric parasitic granulomas were found in this animal.

The mid-dorsal and sternal regions of the blubber in ESB and EDN carcasses of immature harp and hooded seals were significantly thinner than in KBS carcasses (Table 1), suggesting that animals killed at sea were in relatively better condition than beach-cast animals. No significant difference in standard length and axillary girth was found between ESB carcasses and EDN carcasses of immature harp and hooded seals (Table 1). Cutaneous cuts, hair loss and stomatitis/gingivitis, which were observed in some of the live seals and ESB carcasses, were not present in any of the EDN animals. Multifocal small granulomas, scattered throughout the hepatic parenchyma and consisting grossly of white or pale yellow foci, 1–3 mm in diameter, were seen commonly in EDN carcasses of both species, particularly hooded seals in which they were consistently larger and more numerous (Table 2). Microscopically, these granulomas were composed of macrophages, lymphocytes, eosinophils, and occasional multinucleated giant cells, often surrounding a central zone of necrosis. In five hooded seals, a few of these granulomas contained small nematode larvae or their remnants (Fig. 2). A few similar but smaller aggregates of inflammatory cells, with no associated necrosis, were found microscopically in the pulmonary interstitium of some animals. The walls of small hepatic and pulmonary blood vessels adjacent to some granulomas were also in-

TABLE 1. Comparison of morphometric indices among carcasses of immature harp and hooded seals found on Sable Island, Nova Scotia, during December through March from December 1994 to March 1998: seals killed by sharks (KBS), intact carcasses of seals examined superficially on the beach (ESB), and intact carcasses of seals collected from the beach and examined in detail at necropsy (EDN). (\* denotes a significant difference [ $P \leq 0.05$ ] from other means under the same index).

	Harp seals <sup>a</sup>			Hooded seals <sup>b</sup>		
	Mean (SD)	Range	<i>n</i>	Mean (SD)	Range	<i>n</i>
Sternal blubber (mm)						
KBS	22.5 (10.7)*	9–50	29	20.75 (4.35)*	15–25	4
ESB	13.26 (6.04)	4–33	96	11.56 (5.43)	3–28	134
EDN	14.14 (4.45)	5–22	28	14.22 (5.88)	6–30	41
<i>P</i> -value ( <i>F</i> -test, 1-way ANOVA)	<0.001			<0.001		
Mid-dorsal blubber (mm)						
KBS	24.86 (11.25)*	14–45	36	17.83 (4.71)*	12–25	6
ESB	11.63 (6.34)	3–40	94	10.23 (4.74)	3–25	135
EDN	11.79 (4.42)	5–25	19	12.21 (3.85)	8–19	34
<i>P</i> -value ( <i>F</i> -test, 1-way ANOVA)	<0.001			<0.001		
Standard length (cm)						
KBS	NA <sup>c</sup>	NA		NA	NA	
ESB	106.8 (7.21)	89–129	81	109.4 (6.05)	90–122	125
EDN	109.2 (6.38)	101–121	21	111.7 (7.05)	98–125	32
<i>P</i> -value ( <i>t</i> -test)	0.148			0.111		
Axillary girth (cm)						
KBS	NA	NA		NA	NA	
ESB	69.5 (7.55)	51–100	96	72.9 (6.9)	62–90	138
EDN	68.3 (4.23)	60.5–81	28	73.1 (8.85)	58–104	41
<i>P</i> -value ( <i>t</i> -test)	0.273			0.885		

<sup>a</sup> KBS carcasses: 35 female, 29 male, one unknown sex. ESB carcasses: 34 female, 62 male. EDN carcasses: 13 female, 15 male.

<sup>b</sup> KBS carcasses: two female, seven male, one unknown sex. ESB carcasses: 58 female, 80 male. EDN carcasses: 19 female, 23 male.

<sup>c</sup> NA=not available (because of extensive damage to the carcass).

TABLE 2. Gross and microscopic lesions identified in intact carcasses of immature harp and hooded seals examined in detail at necropsy on Sable Island, Nova Scotia, in February 1995, March 1996, and February–March 1998. Of these lesions, only acute suppurative meningitis in a harp seal was considered to have been directly responsible for the animal's death.

	Observation	Harp	Hooded
Number of carcasses examined <sup>a</sup>		28	42
Moderate to large amount of sand in stomach	gross	11	19
Gastric anisakid nematodes <sup>b</sup>	gross	16	4
Heartworms ( <i>Acanthocheilonema spirocauda</i> )	gross	0	1
Lungworms ( <i>Otostrongylus circumlitus</i> )	gross	1	1
Small clusters of nematodes ( <i>Filaroides gymmnurus</i> ) in pulmonary parenchyma	microscopic	5	13
Multifocal hepatic eosinophilic granulomas	gross and microscopic	9	29
Pulmonary interstitial eosinophilic granulomas	microscopic	2	5
Hepatic and/or pulmonary vasculitis, with or without thrombosis	microscopic	6	9 <sup>c</sup>
Acute suppurative leptomeningitis	microscopic	1	0

<sup>a</sup> Tissues from 24 of 28 harp seals and 37 of 42 hooded seals were examined grossly and microscopically. The other seals were only examined grossly.

<sup>b</sup> Seals included in this category were those whose stomachs were estimated to contain several hundred anisakids. (The actual number of anisakids determined in six harp seals varied between 758 and 1,325; they were identified as third- and fourth-stage larvae of *Contracaecum* sp. in one seal and as adult *C. osculatum* in five seals).

<sup>c</sup> In one of these nine seals, there was also acute thrombosis of a few small renal blood vessels.

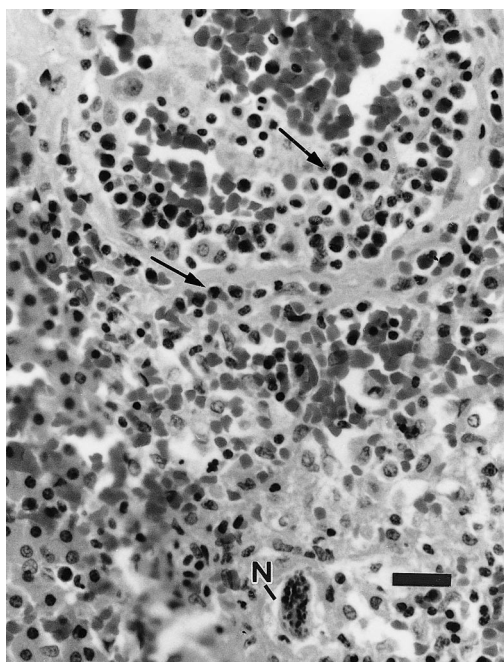


FIGURE 2. Nematode larva (N) surrounded by a few macrophages in hepatic parenchyma of a hooded seal. Several eosinophils (arrows) are within the wall and lumen of an adjacent blood vessel. Bar=25  $\mu$ m.

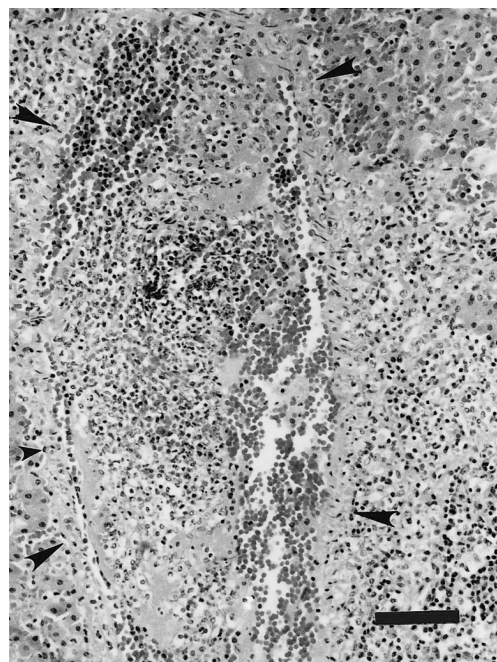


FIGURE 3. Acute hepatic vascular thrombosis in a harp seal (arrowheads outline the blood vessel wall). The adjacent region of the hepatic parenchyma (right part of figure) is infiltrated by numerous macrophages and eosinophils, partly obliterating the architecture of the blood vessel wall. Bar=80  $\mu$ m.

filtrated by inflammatory cells, and some of these blood vessels showed evidence of acute or chronic thrombosis (Table 2). Acute thrombi consisted of fibrin admixed with leukocytes (Fig. 3), whereas in thrombi of longer duration, endothelial cells had infiltrated the fibrin clot in an attempt to canalize it (Fig. 4). In one harp seal, the leptomeninges covering the ventral surface of the brain were grossly hemorrhagic. Microscopically, several areas of the leptomeninges covering the ventral surface of the brain and the cerebral hemispheres of this seal were infiltrated by moderate numbers of neutrophils and macrophages, accompanied by much free blood in some places, indicating the presence of an acute suppurative leptomeningitis (Fig. 5). Tissues from this seal were not collected for bacterial culture. Microscopic lesions suggestive of a viral infection were not seen in any of the EDN carcasses.

Unusual and large amounts of ingesta were recorded in the stomachs of ESB

carcasses of immature harp and hooded seals. Of roughly 100 stomachs examined, most were either empty or contained small amounts of sand, gravel, or stones. Some, however, were filled with large amounts of a single type of ingesta; others contained a variety of ingesta (Table 3). Fewer hooded seals than harp seals were found with stomachs containing unusual ingesta, and, in comparison to harp seals, no kelp or large numbers of stones were observed in hooded seals. There was no suggestion in either species that the presence of unusual ingesta was more common in stomachs that contained large numbers of parasites. In EDN carcasses of 11 of 28 harp seals and 19 of 42 hooded seals, the stomach contained a moderate to large amount of sand occasionally mixed with stones. However, no microscopic evidence of gastritis was detected in any of these animals. In some EDN carcasses (with or without

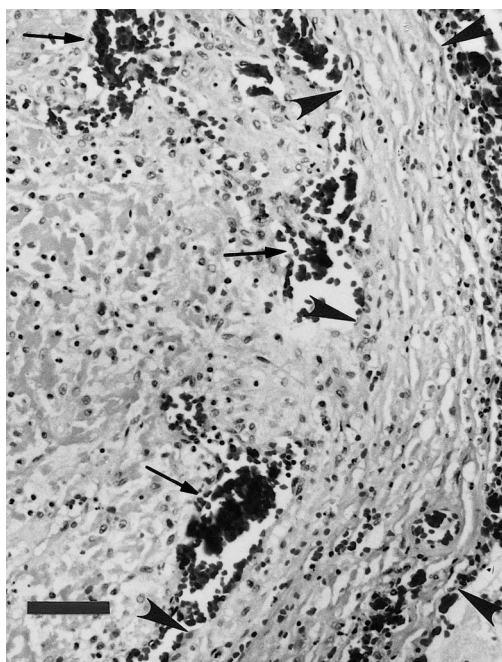


FIGURE 4. Chronic pulmonary vascular thrombosis in a harp seal (arrowheads outline a portion of the blood vessel wall). Most of the lumen of the blood vessel (left part of figure) is filled with fibrin which numerous endothelial cells have infiltrated in an attempt to canalize the thrombus. Aggregates of red blood cells (arrows) are present in what is left of the blood vessel lumen. Bar=70  $\mu$ m.

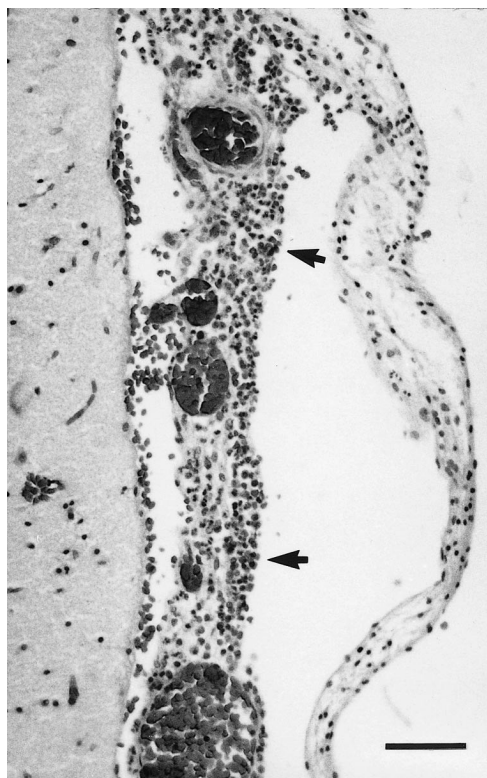


FIGURE 5. Acute suppurative leptomeningitis in a harp seal. The leptomeninges are congested and infiltrated by moderate numbers of inflammatory cells (neutrophils and macrophages) (arrows). Bar=60  $\mu$ m.

sand in their stomach), part of or the entire esophagus, some parts of the small intestine, or the entire large intestine were filled with sand (Fig. 6).

Gastric anisakid nematodes were more common in EDN carcasses of harp seals than hooded seals and were often concentrated in one or a few large aggregates attached to the mucosa. Whereas many of the 42 EDN hooded seals had very few of these parasites and only four of them had what were estimated to be several hundred, most of the 28 EDN harp seals had at least a few hundred nematodes, and 16 had what were estimated to be several hundred (Table 2). The actual number of anisakids determined in six of these 16 harp seals varied between 758 and 1,325. They were identified as adult *Contracaecum osculatum* in five seals and only as third- and fourth-stage larvae of *Contra-*

*caecum* sp. in the sixth seal. In one EDN harp seal and one EDN hooded seal, the stomach contained a few grossly visible granulomas which, microscopically, were associated with necrotic segments of nematodes.

Sections of small nematodes, either as small clusters within alveoli or as single sections of parasites within bronchioles or, rarely, small bronchi (>1 mm in diameter), were observed in histologic sections of lungs of five harp seals and 13 hooded seals (Table 2). No inflammation was associated with these parasites. This anatomical location, deep within the pulmonary parenchyma, and the width of the nematodes (60–294  $\mu$ m) were consistent with those of *Filaroides* spp. according to Measures (2001). Using the lung flush technique, *F. gymnurinus* were recovered from

TABLE 3. Blubber thickness over sternum and mid-dorsally (as a relative measure of body condition) and stomach contents and weights in some immature harp seals and hooded seals found dead and examined superficially on the beach of Sable Island, Nova Scotia, during December 1996 to May 1997 and December 1997 to May 1998.

Sex	Blubber (mm)		Stomach contents	
	Sternal	Dorsal	Wet weight (g)	Description
A) Harp				
F <sup>a</sup>	9	9	>900	Partly digested fish (including 80 mostly intact sandlance, <i>Ammodytes americanus</i> ); fragments of kelp stipe ( <i>Laminaria</i> spp.) and polyethylene; small amount of gravel and sand; nine stones
F	18	16	1,490	Sand; stones; shells
F	6	6	2,150	Filled to capacity with >100 fragments of kelp stipe (mostly 4–6 cm long); sand; shell fragments; several euphausiids
F	12	8	NA <sup>b</sup>	Filled to capacity with 190 fragments of kelp stipe (mostly 4–6 cm long); seaweed
F	30	NA	380	Sand (110 g); stones; seaweed; fragments of latex and polyethylene
F	25	28	710	69 stones (450 g, largest ca. 40 cm <sup>3</sup> ); one hermit crab ( <i>Pagurus</i> spp.); gravel; fragments of polyethylene, shell and birch bark
M	10	8	1,300	Sand; gravel; small fragments of peat
M	15	12	1,600	280 stones; tar balls; small amount of sand
M	21	21	390	Sand (210 g); three small stones; one foil chip bag
M	25	27	7,840	Sand (7,840 g); fragment of decomposed kelp
M	25	22	310	Filled to capacity with >150 fragments of kelp stipe (mostly 4–6 cm long)
M	10	7	1,820	Sand (60 g); 187 stones (largest ca. 50 cm <sup>3</sup> ); gravel; three clam shells; seaweed; fragments of peat and beach grass
NA	NA	NA	990	Sand (450 g); 21 stones (190 g); gravel; seaweed; fragments of kelp stipe, beach grass, wood and peat; one fish operculum; three bivalve shells
B) Hooded				
M	15	12	2,280	Sand; gravel
M	15	14	850	Sand
M	25	20	1,700	Sand
M	20	18	780	Fine mineral sand; one shell

<sup>a</sup> This harp seal was killed by a shark and washed up on the beach; carcasses of all other animals (harp and hooded) were found intact on the beach.

<sup>b</sup> NA=not available.

the left lung of six of six (100%) harp seals (mean intensity [SD]=7.7 [4.9]; range=1–15 worms) and of 11 of 12 (91%) hooded seals (mean intensity [SD]=14.6 [12.9]; range=0–48 worms). Identification of *F. gymnuurus* was based on male (spicule shape and size, caudal papillae) and female (bipartite vaginal sphincter) genital structures. By comparison, infection with these

lungworms was detected on histologic sections of the right lung in only two of six (33%) harp seals and eight of 12 (66%) hooded seals. A single specimen of a large nematode identified as *Otostrongylus circumlitus* was found in a large bronchus of one harp seal. Small numbers of *O. circumlitus* were found in caudal airways of both lungs of a hooded seal. Microscopi-



FIGURE 6. The proximal half of the esophagus of a hooded seal is filled with sand. Bar=2 cm.

cally in this seal, the nematodes were associated with a chronic inflammation of bronchial walls and peribronchial tissue, characterized by fibrosis and infiltration of mononuclear leukocytes and eosinophils. These lesions were not found in regions of the lungs other than in the immediate proximity of nematodes found grossly. In one hooded seal, the right ventricle of the heart contained several long thin nematodes identified as *Acanthocheilonema spirocauda*.

Bacterial culture of internal organs of eight harp seals and nine hooded seals yielded either no growth or variable, most often small, numbers of bacterial colonies interpreted as postmortem contaminants (*Escherichia coli*,  $\alpha$ - and  $\beta$ -hemolytic *Streptococcus* spp.). In one hooded seal, however, isolation of *E. coli* in large numbers and in pure culture from the lungs, liver and kidneys suggested a terminal septicemia, although no gross or microscopic lesions were found which could corroborate this diagnosis.

#### DISCUSSION

Harbor (*Phoca vitulina*) and grey (*Halichoerus grypus*) seals breed on Sable Island and are year-round residents (Boulva and McLaren, 1979; Stobo and Zwanenburg, 1990). In addition, during winter and spring, adult and young harp and hooded seals, and young ringed seals (*Phoca hispida*) (Lucas and McAlpine, unpubl.

data), have been observed on the island. Surveys beginning in winter 1994–95 documented a large increase in numbers of harp and hooded seals on Sable Island as compared to the previous decade. This confirmed reports of a dramatic increase in numbers of harp and hooded seals outside their historic northern range during the 1990s (McAlpine and Walker, 1990; Stevick and Fernald, 1998; McAlpine et al., 1999a, b).

McAlpine and Walker (1990) noted that most harp seals found in extralimital locations were animals in poor health but suggested that it is difficult to assess the significance of this because sick animals are more likely to be encountered on beaches and reported. This suggestion is supported by the Sable Island observations. Based on measurements of blubber thickness, seals killed by sharks were generally in better condition than the seals that came ashore and died on the beach. Stomach contents also suggested that harp and hooded seals killed at sea were generally healthier than the beached seals. The stomachs of some shark-killed seals contained large amounts of normal food items such as fish and euphausiids (Sergeant, 1976; Lawson et al., 1995); whereas none of the stomachs of intact beached carcasses examined contained more than a trace of normal food. The average blubber thickness of ESB and EDN carcasses of both species was less than the 15 mm blubber thickness considered to be the lower limit for effective thermal insulation in young phocids under natural conditions (Brodie and Päsche, 1982; Worthly, 1991), suggesting that animals that came on land were more likely those whose blubber could no longer protect them from hypothermia in water. The average blubber thickness of KBS carcasses was greater than 15 mm. It is unlikely that this reflects selection for fatter prey by sharks. Among the hundreds of grey seal pups killed by sharks during the grey seal breeding season in December through February on Sable Island, many thin grey seal pups are

killed (Lucas, unpubl. data). Nevertheless, comparison of the average blubber thickness in the sternal region of KBS harp seals with the values provided by Chabot et al. (1996) (35–45 mm) in seals collected at the same time of year in the northwest Atlantic suggests that most harp seals in waters surrounding Sable Island were thin.

Emaciation caused by starvation was considered the most common and primary disease problem in EDN carcasses and, by inference, in ESB carcasses. In harp seals, this was based on the very low average sternal blubber thickness of these animals as compared to values provided by Chabot et al. (1996) for this age group and on the absence of underlying chronic diseases among the EDN carcasses that could have led to the loss of body condition. Although reference values are not available for the blubber thickness of hooded seals, the close similarity of the mid-dorsal and sternal blubber thicknesses to those in harp seals (Table 1) and the absence of chronic diseases among EDN carcasses of hooded seals that would have been sufficient to cause loss of body condition suggest that emaciation caused by starvation also was the primary problem in this species. Some harp and hooded seals in the Sable Island area may arrive in good body condition, but are subsequently unable to feed successfully. The reasons for this are not clear, but difficulty finding suitable prey and foraging in an unfamiliar environment may be factors. There is evidence in other pinniped species that animals in their first three years of life are more susceptible than other segments of the population to nutritional stress brought about by changes in the oceanic environment or by increased population densities (Fowler, 1990; Bickham et al., 1998).

Nearly 25% of the EDN carcasses whose tissues were examined microscopically (six of 24 harp seals, nine of 37 hooded seals, Table 2) had hepatic or pulmonary vascular inflammatory lesions associated with nearby granulomas, and some of these vascular lesions were accompanied

by intravascular coagulation. The presence of numerous eosinophils in the hepatic and pulmonary granulomas and associated vascular lesions and the presence of nematode larvae in some hepatic granulomas suggest that parasitic infection had caused the vascular lesions and thrombosis. Although the identity of the nematode larvae could not be determined, they may have been those of *F. gymnurinus*. This metastrongyloid parasite was highly prevalent in these seals, as indicated by the results of the pulmonary lavages done in 1998, and the occurrence of eosinophilic granulomas in the liver and lungs would be compatible with the systemic migratory route commonly used by metastrongyloids (Anderson, 2000). These migrating larvae may, therefore, have been responsible for the hepatic and pulmonary granulomas, associated vasculitis, and vascular thrombosis. In January–March 1997 and 1998, more than 20% of live harp and hooded seals had a tendency to bleed during capture, a proportion similar to the number of EDN carcasses with hepatic and/or pulmonary vascular lesions. It is thus possible that this bleeding tendency had resulted from repeated episodes of intravascular coagulation that had led to a depletion of coagulation factors and/or platelets. Gulland et al. (1997) reported several cases of acute disseminated intravascular coagulation (DIC) in juvenile northern elephant seals (*Mirounga angustirostris*) suffering from severe infection of the right cardiac chambers and pulmonary arteries by *O. circumlitus*. Presenting clinical signs included epistaxis, and coagulation assays in some animals revealed a slower clotting time. A low grade, chronic form of DIC, characterized clinically by bleeding episodes (including expectoration of blood), iron-deficiency anemia from chronic blood loss, and subcutaneous hematoma formation, has been described in dogs infected with *Angiostrongylus vasorum*, a metastrongyloid which parasitizes the right side of the heart and pulmonary arteries (Schelling et al., 1986; Ramsey et al., 1996). In the pre-

sent study, seals in a presumed state of chronic DIC and secondary hemorrhagic diathesis did not seem to be more likely to die than seals that showed no bleeding tendency at the time of capture, since the ratio of these two groups was the same among seals that were later found dead. There was also no indication of increased intensity of parasitic infection in EDN carcasses with hepatic or pulmonary vascular inflammatory lesions. Only small numbers of adult *Filaroides* nematodes were seen microscopically in the lungs of these animals, and these parasites were never associated with an inflammatory reaction. Some EDN carcasses of harp seals had several hundred gastric nematodes identified as *C. osculatum*, but the intensity of this parasitic infection was similar to that reported in presumably normal harp seals collected in the northwest Atlantic (Bratney and Ni, 1992).

Gradual emaciation depresses the function of the immune system which, in turn, increases the susceptibility of an animal to various parasitic and infectious diseases (Chandra, 1992). This process could promote the occurrence of acute bacterial diseases such as meningitis in some seals. The stomatitis/gingivitis observed in a small proportion of the hooded seals may have been another expression of their decreased resistance to infection, although we cannot explain why this type of lesion was not encountered among harp seals as well. McAlpine et al. (1999b) reported a similar condition ("infection of the gums") in one of at least 25 hooded seals recorded in the Bay of Fundy and northern Gulf of Maine. Despite a possible depression of the immune system caused by emaciation, no infectious disease of a contagious nature, in particular no evidence of viral infection, was identified in any of the EDN seals.

The presence of stones, in a wide range of sizes and quantities, has been reported in the stomach of many pinnipeds (King, 1983; Nordøy, 1995; Needham, 1997; Bryden, 1999). In some cases, these stones may be ingested deliberately, although

their physiologic function, if any, is unknown, and it is also possible that stones are ingested accidentally. The amount of stones, gravel, or sand in some ESB and EDN carcasses in our study would seem to have been far in excess of any possible physiologic role and may even have contributed to starvation in some of them. None of these materials seemed to correlate with intensity of gastric parasitism. Some of these animals had a blubber thickness of as much as 28 mm, indicating that they had not exhausted their energy reserves before ingesting sand, stones, or kelp. Yet, the relatively uniform size of stipe fragments found in the three stomachs packed with kelp suggests that the seals had bitten the segments from stipes as if feeding on them. Although seals typically rely on the food that they ingest for their source of water, harp seals also readily eat snow and ice (Renouf et al., 1990). There is normally little access to snow or ice on Sable Island and none in waters surrounding it. Consumption of either sand, stones, or kelp, could therefore have been associated with dehydration as well as starvation in these animals, perhaps reflecting some form of displacement behavior. Harp seals and hooded seals can drink seawater, which may be beneficial to ion-deficient animals but may not provide them with a net gain of water (Storeheier and Nordøy, 2001).

Although emaciation was considered the primary disease problem in EDN and ESB carcasses, the range of mid-dorsal and sternal blubber thicknesses in these animals (Table 1) suggests that some of them had not yet reached a terminal stage of emaciation. The exact cause of death of these seals was not determined. Seals rely on food consumption as an important source of water, and their blubber acts as a thermal insulator and, during fasting, as a source of energy and metabolic water. Therefore, a starving seal likely faces several physiologic challenges simultaneously, including depletion of energy reserves, hypothermia and dehydration, any combina-

tion of which could gradually lead to death. Increased secretion of aldosterone by the adrenal cortex may be an important mechanism for seals to prevent water loss during fasting, by promoting reabsorption of water in renal tubules through increased reabsorption of sodium (Nordøy et al., 1993). However, prolonged stimulation of adrenal cortical secretion, possibly exacerbated by stress, could result in adrenal exhaustion which, in turn, could lead to severe plasma electrolyte imbalance, particularly hyponatremia (St. Aubin and Geraci, 1986). Such a cause of death would leave no morphologic evidence. Further investigations of natural causes of mortality in these animals could provide valuable information on their responses to environmental challenges.

#### ACKNOWLEDGMENTS

We thank G. Forbes (Sable Island Station), the Meteorological Service of Canada, the Nova Scotia Petroleum Directorate, Exxon-Mobil Canada Energy, EnCana Resources, and J. Conway (Fisheries and Oceans Canada) for logistical assistance; G. Dobbin for his assistance with statistical analyses; and W. Stobo, D. Cairns, and S. Burton for helpful comments on the manuscript.

#### LITERATURE CITED

- AMERICAN SOCIETY OF MAMMALOGISTS. 1967. Standard measurements of seals. *Journal of Mammalogy* 48: 459–462.
- ANDERSON, R. C. 2000. Nematode parasites of vertebrates. Their development and transmission. C.A.B. International, Wallingford, UK, 650 pp.
- BICKHAM, J. W., T. R. LAUGHLIN, D. G. CALKINS, J. K. WICKLIFFE, AND J. PATTON. 1998. Genetic variability and population decline in Steller sea lions from the Gulf of Alaska. *Journal of Mammalogy* 79: 1390–1395.
- BOULVA, J., AND I. A. McLAREN. 1979. Biology of the harbour seal, *Phoca vitulina*, in eastern Canada. *Bulletin of the Fisheries Research Board of Canada* 200: 1–24.
- BOWERING, W. R. 2000. Trends in distribution, biomass and abundance of Greenland halibut (*Reinhardtius hippoglossoides*) in NAFO Subarea 2 and Divisions 3KLMNO from Canadian research vessel surveys during 1978–99. Northwest Atlantic Fisheries Organization, Scientific Council Research Document 00/12, Serial No. N4234.
- BRATTEY, J., AND I.-H. NI. 1992. Ascaridoid nematodes from the stomach of harp seals, *Phoca groenlandica*, from Newfoundland and Labrador. *Canadian Journal of Fisheries and Aquatic Sciences* 49: 956–966.
- BRODIE, P. F., AND A. J. PÄSCHE. 1982. Density-dependent condition and energetics of marine mammal populations in multispecies fisheries management. In *Multispecies approaches to fisheries management advice*, M. C. Mercer (ed.). Canadian Special Publication of Fisheries and Aquatic Sciences no. 59, pp. 35–38.
- BRYDEN, M. M. 1999. Stones in the stomachs of southern elephant seals. *Marine Mammal Science* 15: 1370–1373.
- CARSCADDEN, J. E., K. T. FRANK, AND W. C. LEGGETT. 2001. Ecosystem changes and the effects on capelin (*Mallotus villosus*), a major forage species. *Canadian Journal of Fisheries and Aquatic Sciences* 58: 73–85.
- CHABOT, D., G. B. STENSON, AND N. B. CADIGAN. 1996. Short- and long-term fluctuations in the size and condition of harp seal (*Phoca groenlandica*) in the Northwest Atlantic. *Northwest Atlantic Fisheries Organization, Science Council Studies* 26: 15–32.
- CHANDRA, R. K. 1992. Nutrition and immunology: Experience of an old traveller and recent observations. In *Nutrition and Immunology*, R. K. Chandra (ed.). ARTS Biomedical Publishers and Distributors, St. John's, Newfoundland, Canada, pp. 9–43.
- DUIGNAN, P. J., O. NIELSEN, C. HOUSE, K. M. KOVACS, N. DUFFY, G. EARLY, S. SADOVE, D. J. ST. AUBIN, B. K. RIMA, AND J. R. GERACI. 1997. Epizootiology of morbillivirus infection in harp, hooded, and ringed seals from the Canadian Arctic and western Atlantic. *Journal of Wildlife Diseases* 33: 7–19.
- FOWLER, C. W. 1990. Density dependence in northern fur seals (*Callorhinus ursinus*). *Marine Mammal Science* 6: 171–195.
- GERACI, J. R., AND V. J. LOUNSBURY. 1993. *Marine Mammals Ashore. A field guide for strandings*. Texas A&M University Sea Grant College Program, Galveston, Texas, 305 pp.
- , D. J. ST. AUBIN, I. K. BARKER, R. G. WEBSTER, V. S. HINSHAW, W. J. BEAN, H. L. RUHNKE, J. H. PRESCOTT, G. EARLY, A. S. BAKER, S. MADOFF, AND R. T. SCHOOLEY. 1982. Mass mortality of harbor seals: Pneumonia associated with influenza A virus. *Science* 215: 1129–1131.
- GULLAND, F. M. D., K. BECKMEN, K. BUREK, L. LOWENSTINE, L. WERNER, T. SPRAKER, M. DAILEY, AND E. HARRIS. 1997. Nematode (*Otostrongylus circumlitus*) infestation of northern elephant seals (*Mirounga angustirostris*) stranded along the central California coast. *Marine Mammal Science* 13: 446–459.
- HAMMILL, M. O. 1993. Seasonal movements of

- hooded seals tagged in the Gulf of St. Lawrence, Canada. *Polar Biology* 13: 307–310.
- KENNEDY, S. 1998. Morbillivirus infections in aquatic mammals. *Journal of Comparative Pathology* 119: 201–25.
- KING, J. E. 1983. *Seals of the world*, 2nd Edition, British Museum of Natural History and Oxford University Press, London, UK, 240 pp.
- LAWSON, J. W., G. STENSON, AND D. G. MCKINNON. 1995. Diet of harp seals (*Phoca groenlandica*) in nearshore waters of the northwest Atlantic during 1990–1993. *Canadian Journal of Zoology* 73: 1805–1818.
- LUCAS, Z., AND P-Y DAOUST. 2002. Large increases of harp seals (*Phoca groenlandica*) and hooded seals (*Cystophora cristata*) on Sable Island, Nova Scotia, since 1995. *Polar Biology* 25: 562–568.
- LYDERSEN, C., AND K. M. KOVACS. 1995. Paralysis as a defense response to threatening stimuli in harp seals (*Phoca groenlandica*). *Canadian Journal of Zoology* 73: 486–492.
- MCALPINE, D. F., AND R. H. WALKER. 1990. Extralimital records of the harp seal, *Phoca groenlandica*, from the western North Atlantic: A review. *Marine Mammal Science* 6: 248–252.
- , P. T. STEVICK, AND L. D. MURISON. 1999a. Increase in extralimital occurrences of ice-breeding seals in the northern Gulf of Maine region: More seals or fewer fish? *Marine Mammal Science* 15: 906–911.
- , ———, ———, AND S. D. TURNBULL. 1999b. Extralimital records of hooded seals (*Cystophora cristata*) from the Bay of Fundy and northern Gulf of Maine. *Northeastern Naturalist* 6: 225–230.
- MEASURES, L. N. 2001. Lungworms of marine mammals. In *Parasitic diseases of wild mammals*, 2nd Edition, W. M. Samuel, M. J. Pybus and A. A. Kocan (eds.), Iowa State University Press, Ames, Iowa, pp. 279–300.
- NEEDHAM, D. J. 1997. The role of stones in the sea lion stomach: Investigations using contrast radiography and fluoroscopy. In *Marine mammal research in the Southern Hemisphere*, Vol. 1, Status, ecology and medicine, M. Hindell and C. Kemper (eds.), Surrey Beatty & Sons, Chipping Norton, pp. 164–169.
- NORDØY, E. S. 1995. Gastroliths in the harp seal *Phoca groenlandica*. *Polar Research* 14: 335–338.
- , A. AAKVAAG, AND T. S. LARSEN. 1993. Metabolic adaptations to fasting in harp seal pups. *Physiological Zoology* 66: 926–945.
- OAKLEY, G. A. 1980. The recovery of *Dictyocaulus viviparus* from bovine lungs by lung perfusion: A modification of Inderbitzen's method. *Research in Veterinary Science* 29: 395–396.
- QUINN, P. J., M. E. CARTER, B. K. MARKEY, AND G. R. CARTER. 1994. *Clinical veterinary microbiology*. Wolfe Publishing, Mosby-Year Book Europe Ltd., London, UK, 648 pp.
- RAMSEY, I. K., J. LITTLEWOOD, J. K. DUNN, AND M. E. HERITAGE. 1996. Role of chronic disseminated intravascular coagulation in a case of canine angiostrongylosis. *The Veterinary Record* 138: 360–363.
- RENOUF, D., E. NOSEWORTHY, AND M. C. SCOTT. 1990. Daily fresh water consumption by captive harp seals (*Phoca groenlandica*). *Marine Mammal Science* 6: 253–257.
- SCHELLING, C. G., C. E. GREENE, A. K. PRESTWOOD, AND V. C. W. TSANG. 1986. Coagulation abnormalities associated with acute *Angiostrongylus vasorum* infection in dogs. *American Journal of Veterinary Research* 47: 2669–2673.
- SERGEANT, D. E. 1976. History and present status of populations of harp and hooded seals. *Biological Conservation* 10: 95–118.
- . 1991. Harp seals, man and ice. *Canadian Special Publication of Fisheries and Aquatic Sciences* number 114, 153 pp.
- SPJOTVOLL, E., AND M. R. STOLINE. 1973. An extension of the T-method of multiple comparisons to include the cases with unequal sample sizes. *Journal of the American Statistical Association* 68: 975–978.
- ST. AUBIN, D. J., AND J. R. GERACI. 1986. Adrenocortical function in pinniped hyponatremia. *Marine Mammal Science* 2: 243–250.
- STEVICK, P. T., AND T. W. FERNALD. 1998. Increase in extralimital records of harp seals in Maine. *Northeastern Naturalist* 5: 75–82.
- STOBO, W. T., AND K. C. T. ZWANENBURG. 1990. Grey seal (*Halichoerus grypus*) pup production on Sable Island and estimates of recent production in the northwest Atlantic. *Canadian Bulletin of Fisheries and Aquatic Sciences* 222: 171–184.
- STOREHEIER, P. V., AND E. S. NORDØY. 2001. Physiological effects of seawater intake in adult seals during phase I of fasting. *Comparative Biochemistry and Physiology Part A* 128: 307–315.
- WORTHY, G. A. J. 1991. Insulation and thermal balance of fasting harp and grey seal pups. *Comparative Biochemistry and Physiology* 100A: 845–851.

Received for publication 25 October 2001.