

## **CAPILLARIA AND TRYPANOSOMA INFESTATIONS IN *Microtus ochrogaster***

Authors: DUNAWAY,, P. B., COSGROVE, G. E., and STORY, J. D.

Source: Bulletin of the Wildlife Disease Association, 4(1) : 18-20

Published By: Wildlife Disease Association

URL: <https://doi.org/10.7589/0090-3558-4.1.18>

---

The BioOne Digital Library (<https://bioone.org/>) provides worldwide distribution for more than 580 journals and eBooks from BioOne's community of over 150 nonprofit societies, research institutions, and university presses in the biological, ecological, and environmental sciences. The BioOne Digital Library encompasses the flagship aggregation BioOne Complete (<https://bioone.org/subscribe>), the BioOne Complete Archive (<https://bioone.org/archive>), and the BioOne eBooks program offerings ESA eBook Collection (<https://bioone.org/esa-ebooks>) and CSIRO Publishing BioSelect Collection (<https://bioone.org/csiro-ebooks>).

Your use of this PDF, the BioOne Digital Library, and all posted and associated content indicates your acceptance of BioOne's Terms of Use, available at [www.bioone.org/terms-of-use](http://www.bioone.org/terms-of-use).

Usage of BioOne Digital Library content is strictly limited to personal, educational, and non-commercial use. Commercial inquiries or rights and permissions requests should be directed to the individual publisher as copyright holder.

---

BioOne is an innovative nonprofit that sees sustainable scholarly publishing as an inherently collaborative enterprise connecting authors, nonprofit publishers, academic institutions, research libraries, and research funders in the common goal of maximizing access to critical research.

**CAPILLARIA AND TRYPANOSOMA  
INFESTATIONS IN *Microtus ochrogaster***

Ten prairie voles, *Microtus ochrogaster*, were trapped by R. W. Dimmick during January and February, 1965, near Cookeville, Putnam County, Tennessee. These animals were sent to us in February, 1965, and blood samples were taken two weeks after we received the voles. Two weeks after blood sampling, these animals received acute gamma irradiation doses ranging from 520-1270 rad. An adult female which died six days after receiving 1084 rad was necropsied. The stomach was enlarged (4 cm maximum length), thickened, externally rugose in appearance, and white in color, suggestive of brain surface (Figure 1). The opened stomach showed tremendous thickening of the wall, which had many folds showing excessive keratinization. Numerous ova and nematodes of an unidentified species of *Capillaria* were found in tun-

nels in the squamous epithelium throughout the stomach and lower esophagus (Figure 2). The tissue reaction was hyperplastic and hyperkeratotic, rather than neoplastic, apparently in response to the irritation produced by the nematodes or their ova in the mucosa. The reaction was sharply limited to the squamous epithelial mucosa with no extension to adjacent columnar epithelial mucosa (Figure 3). The disease probably was present before irradiation and seemed to be unrelated to it. Subsequently, six *M. ochrogaster* were examined which had been killed 30 days postirradiation. *Capillaria* infestations were severe in three individuals, slight in two animals, and nonexistent in the remaining individual. Three other mice, which died at postirradiation times ranging from 6-26 days, were not necropsied.

The genus *Capillaria* has had several taxonomic revisions (Yamaguti, 1961, *Systema Helminthum*, Vol. III, *The*

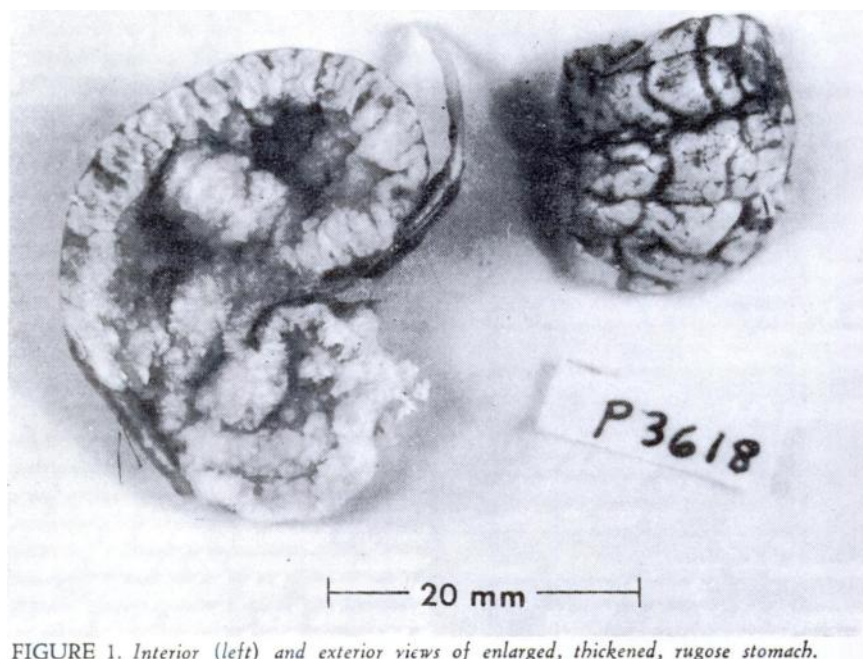


FIGURE 1. Interior (left) and exterior views of enlarged, thickened, rugose stomach.

*Nematodes of Vertebrates*, Part 1, pp. 241-346).

Species of *Capillaria* have long been known to be a cause of epithelial hyperplasia and neoplasia in the stomach of

laboratory rats (Beatti, 1930. *Z. Krebsforsch.* 32:27-39). Except for one report of a gastric adenoma in *Erotomys* in Europe (Roman, 1939. *Ann. Parasitol.* 17: 167-169), the hyperplastic and neoplastic

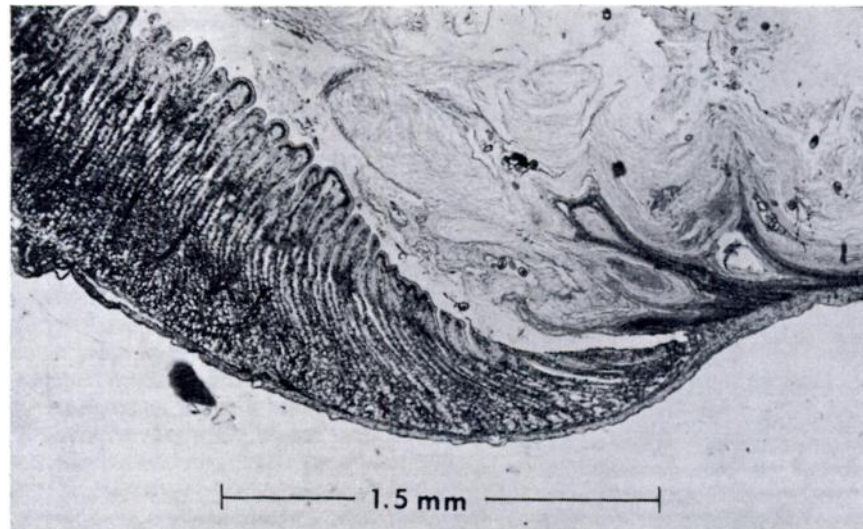


FIGURE 2. Histologic appearance of stomach with nematodes and ova in the squamous epithelial layer and marked hyperkeratosis (above).

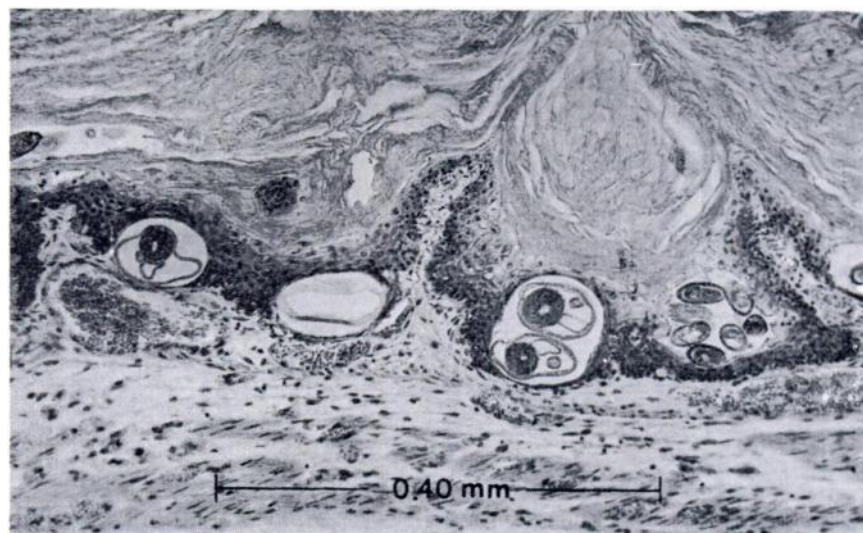


FIGURE 3. Histologic appearance of stomach at the junction of squamous lined (right) and glandular (left) portions.

Table 1. Blood values for *Microtus ochrogaster* infested with *Capillaria* and *Trypanosoma*.

Capillaria Infestation	Number of Voles	RBC* (cells x 10 <sup>6</sup> /mm <sup>3</sup> )	Hct Percent	MCV (μ <sup>3</sup> )	Hgb (g/100 ml blood)	WBC (cells x 10 <sup>3</sup> /mm <sup>3</sup> )	WT (g)
Severe	4	10.28	43.5	43	16.0	10.0	38.3
Slight	2	13.10	42.8	34	14.9	12.2	42.0
None	1	11.10	—	—	14.7	17.3	30.8
No examination for <i>Capillaria</i>	3	11.56	43.5	38	16.1	12.3	35.0
Differential Count Percent							
		Neutrophils	Eosinophils	Lymphocytes	Monocytes		
Severe	3	15.7	5.3	79.0	0		
Slight	1	32	10	58	0		
None	0	—	—	—	—		
No examination for <i>Capillaria</i>	3	17.0	2.3	80.7	0		

\*RBC = erythrocyte count, Hct = hematocrit, MCV = mean corpuscular volume, Hgb = hemoglobin, WBC = leukocyte count.

changes have always involved the squamous epithelium of the forestomach. *Capillaria gastrica* is the species most frequently identified from such lesions. When experimentally administered to rats, this species can induce squamous cell carcinoma of the stomach within 3 months (Vogel, 1929. Z. Krebsforsch. 29:351-359). *Capillaria* spp. apparently show low host specificity but considerable organ specificity in the host (Read, 1949. J. Parasitol. 35:223-230, 231-239). *Capillaria* occurs in many species of wild rodents. We are not aware of a previous report from *Microtus ochrogaster*, but other species of *Microtus* have been reported as hosts of gastric *Capillaria* (Read, 1949).

*Trypanosoma* sp. were found in each of the smears obtained from seven of these voles. These are the only trypanosomes that we have seen in > 1200 blood smears from > 60 species of wild mammals. Blood values for these voles are shown in Table 1. No *M. ochrogaster* uninfested with *Capillaria* and/or *Trypanosoma* was available, and "normal" blood values for this species of vole are not known. Compared with indigenous cricetid rodents in the same size range, most blood values for these animals were not unusual. However, total leukocyte

count was about  $4 \times 10^3$  cells/mm<sup>3</sup> higher than for local small rodents. There were no statistically different blood values among the *Capillaria*-infested animals, but of the four with severe infestations, three had the lowest erythrocyte counts of all specimens.

It is interesting to note that these animals, in spite of *Trypanosoma* and *Capillaria* infestations, were somewhat radio-resistant in comparison with certain species of indigenous rodents tested (Dunaway, Lewis, Story, Payne, and Inglis, 1968, *Second Natl. Symp. Radioecology*, in press). Two voles receiving the highest dose of 1271 rad lived for 9 and 11 days, one of two individuals survived after 1084 rad, and neither of two receiving 896 rad died.

#### Acknowledgements

This research was sponsored by the U. S. Atomic Energy Commission under contract with the Union Carbide Corporation.

P. B. DUNAWAY\*\*  
G. E. COSGROVE,\*  
and J. D. STORY\*\*

\*Biology Division, and  
\*\*Radiation Ecology Section,  
Health Physics Division,  
Oak Ridge National Laboratory,  
Oak Ridge, Tennessee 37830

October 17, 1967