

## **First Report of an Intraerythrocytic Small Piroplasm in Wild Iberian Lynx (*Lynx pardinus*)**

Authors: Luaces, Inés, Aguirre, Enara, García-Montijano, Marino, Velarde, Jorge, Tesouro, Miguel A., et al.

Source: Journal of Wildlife Diseases, 41(4) : 810-815

Published By: Wildlife Disease Association

URL: <https://doi.org/10.7589/0090-3558-41.4.810>

---

The BioOne Digital Library (<https://bioone.org/>) provides worldwide distribution for more than 580 journals and eBooks from BioOne's community of over 150 nonprofit societies, research institutions, and university presses in the biological, ecological, and environmental sciences. The BioOne Digital Library encompasses the flagship aggregation BioOne Complete (<https://bioone.org/subscribe>), the BioOne Complete Archive (<https://bioone.org/archive>), and the BioOne eBooks program offerings ESA eBook Collection (<https://bioone.org/esa-ebooks>) and CSIRO Publishing BioSelect Collection (<https://bioone.org/csiro-ebooks>).

Your use of this PDF, the BioOne Digital Library, and all posted and associated content indicates your acceptance of BioOne's Terms of Use, available at [www.bioone.org/terms-of-use](http://www.bioone.org/terms-of-use).

Usage of BioOne Digital Library content is strictly limited to personal, educational, and non-commercial use. Commercial inquiries or rights and permissions requests should be directed to the individual publisher as copyright holder.

---

BioOne is an innovative nonprofit that sees sustainable scholarly publishing as an inherently collaborative enterprise connecting authors, nonprofit publishers, academic institutions, research libraries, and research funders in the common goal of maximizing access to critical research.

## First Report of an Intraerythrocytic Small Piroplasm in Wild Iberian Lynx (*Lynx pardinus*)

Inés Luaces,<sup>1,6</sup> Enara Aguirre,<sup>2</sup> Marino García-Montijano,<sup>1</sup> Jorge Velarde,<sup>3</sup> Miguel A. Tesouro,<sup>4</sup> Celia Sánchez,<sup>5</sup> Margarita Galka,<sup>5</sup> Pilar Fernández,<sup>5</sup> and Ángel Sainz<sup>2</sup> <sup>1</sup>Gir diagnostics S.L., Madrid, Spain; <sup>2</sup>Dpto. Medicina y Cirugía Animal, Facultad de Veterinaria, Universidad Complutense, Madrid, Spain; <sup>3</sup>Clínica Veterinaria Fauna, Córdoba, Spain; <sup>4</sup>Dpto. Patología Animal, Medicina Veterinaria, Universidad de León, Spain; <sup>5</sup>Parque Nacional de Doñana, Ministerio de Medio Ambiente, Huelva, Spain; <sup>6</sup>Corresponding author (email: ines@girdiagnostics.com)

**ABSTRACT:** A wild injured Iberian lynx (*Lynx pardinus*) was taken from the Sierra Morena population. During the health check small intraerythrocytic piroplasms, morphologically indistinguishable from other feline piroplasms, were observed in Wright-Giemsa-stained blood films. Amplification by polymerase chain reaction of a portion of the 18S nuclear small subunit (NSS) rRNA gene and sequencing revealed similarity of the unknown organism with sequences obtained from Pallas's cat from Mongolia and from a domestic cat in Spain. In a retrospective (1993–2003) study of 50 Iberian lynx tissue samples, no amplifications of the 18S NSS rRNA gene of the organism were obtained. This is the first report of a naturally occurring erythroparasitemia in the Iberian lynx and the first documented case of naturally occurring piroplasm infection in a free-ranging felid from Europe.

**Key words:** *Cytauxzoon felis*, hemoparasite, Iberian lynx, *Lynx pardinus*, piroplasm.

The Iberian lynx (*Lynx pardinus*) is the most endangered feline in the world (Nowell and Jackson, 1996) and is found only in Southern Spain in two isolated populations. One population is located in Doñana National Park (between 36°47'40.92" to 37°8'36.24"N, 6°33'41.76" to 6°15'1.8"W), Huelva, Spain, with 36–40 individuals, and the other in Sierra Morena (between 38°4'7.68" to 38°24'11.16"N, 4°16'38.64" to 3°47'57.58"W), Jaén, Spain, with 90–120 lynxes (Guzmán et al., 2003).

Intraerythrocytic piroplasms have been reported in a variety of domestic and free-living feline species from several continents. A brief revision of piroplasms in exotic felids has been presented recently by Ketz-Riley et al. (2003). The infection caused by *Cytauxzoon felis* is well studied in the domestic cat, where it causes an acute, highly fatal, febrile disease, with

clinical signs of an acute hemolytic crisis (Hoover et al., 1994; Kier and Greene, 1998) although many of the clinical signs and death are apparently due to vascular disease caused by the tissue phase and are not related to the degree of parasitemia (Shaw et al., 2001).

This tick-transmitted disease has been frequently detected throughout much of the south-central United States (Meinkoth et al., 2000). The Eastern (*Lynx rufus rufus*) and Florida bobcat (*Lynx rufus floridanus*) are considered to be the primary reservoirs of the organism, with infection most often being subclinical in both species (Walker and Cowell, 1995). Although death in bobcats due to the parasite has been described by experimental inoculation (Kier et al., 1982) and by natural infection (Nietfeld and Pollock, 2002), the existence of scarce genetic information warrants further investigations to determine whether the bobcat is a natural host for two morphologically indistinguishable piroplasms (Glenn et al., 1982). Infections of cougars (*Felis concolor stanleyana*) (Kocan and Kocan, 1991) and Florida panthers (*Felis concolor coryi*) (Butt et al., 1991) have also been reported.

Recently, an intraerythrocytic small piroplasm has been described in wild-caught Pallas's cats (*Otocolobus manul*) from Mongolia (Ketz-Riley et al., 2003).

To the authors' knowledge no intraerythrocytic piroplasms have been reported in wild felids from Europe. The aim of this report was to identify an intraerythrocytic piroplasm in the blood of a wild-caught Iberian lynx and to carry out a retrospective study on tissue samples of lynx-

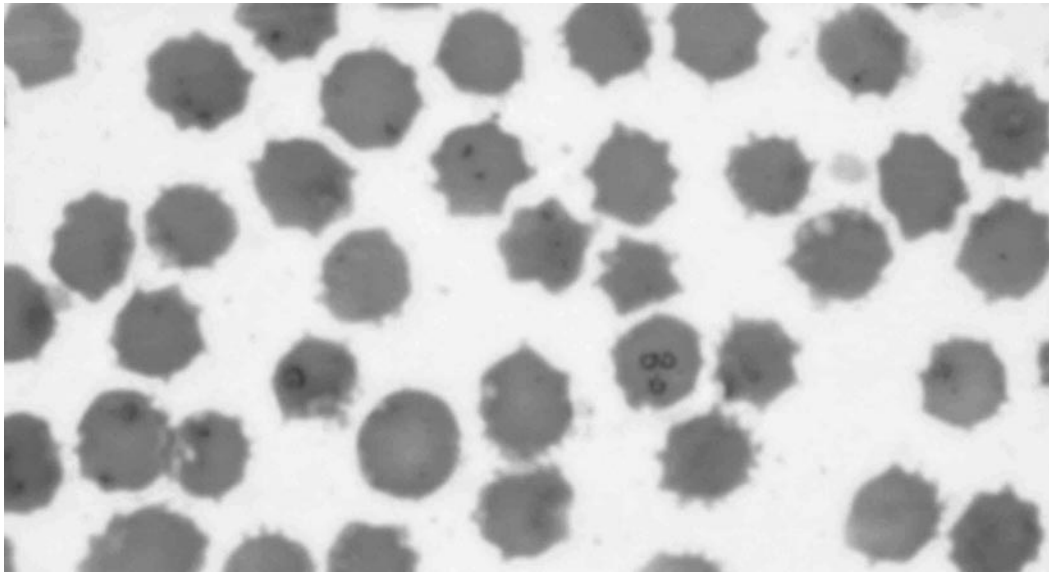


FIGURE 1. *Cytauxzoon* sp. found in red blood cells of an Iberian lynx (*Lynx pardinus*) in Spain. Wright-Giemsa stain.

es stored at Doñana National Park to determine the presence of the piroplasm in the species.

In March 2003, an injured young male Iberian lynx was extracted from the wild population of Sierra Morena and transported to quarantine facilities in a rehabilitation center in Córdoba, Spain. The animal was subjected to a standardized health check protocol consisting of a clinical examination and collection of biologic samples. This animal had several severe muscle and skin injuries in the forelegs and a mild cystitis. Blood hematologic and biochemistry values were within normal ranges for Iberian lynx according to Beltrán and Delibes (1991). Wright-Giemsa and J-322 Dip Quick (Jorgensen Laboratories Inc., Loveland, Colorado) stained blood films from peripheral blood had an approximately 4% parasitemia of intra-erythrocytic piroplasms (Fig. 1). Most piroplasms were rounded or slightly oval with the nucleus situated on the periphery. Dividing forms (Maltese crosses) were sometimes observed but extracellular forms were rarely seen. Single forms were usually situated in the center of the eryth-

rocyte, and measured from  $0.6\ \mu\text{m}$  to  $1.4\ \mu\text{m} \pm 0.2$  in length by  $0.6\ \mu\text{m}$  to  $1\ \mu\text{m} \pm 0.2\ \mu\text{m}$  ( $n = 40$  parasites).

To further characterize the organism, a polymerase chain reaction (PCR) was performed to amplify the 18S NSS rRNA genes of the members of the order Piroplasmida, as previously described by Meinkoth et al. (2000). DNA was extracted with the Ultraclean DNA Blood Spin Kit (MoBio Laboratories Inc., Solana Beach, California) from  $200\ \mu\text{l}$  of EDTA-anticoagulated peripheral blood. All the process was performed according to the manufacturer's instructions. In brief, PCR reaction was carried out in a  $50\text{-}\mu\text{l}$  reaction mixture containing  $5\ \mu\text{l}$  of  $10\times$  PCR buffer with  $2\ \text{mM}$   $\text{MgCl}_2$ ,  $200\ \mu\text{M}$  of deoxynucleoside triphosphate mixture,  $5\ \mu\text{M}$  of primer 3383 (5'-CCTGGTTGATCCTGCCAG-3') and  $5\ \mu\text{M}$  of primer 3406 (5'-CGACTTCTCCTTCCTTTAAG-3'),  $10\ \mu\text{l}$  of the extracted DNA were added. After an initial step of denaturation at  $96\ \text{C}$  for 3 min,  $1.3\ \text{U}$  of DNA polymerase were added. The following cycling conditions were 40 cycles of 1 min at  $96\ \text{C}$ , 1 min at  $65\ \text{C}$ , and 2 min at  $72\ \text{C}$ . No positive con-

trol was available. As negative control, distilled water was added instead of DNA in another reaction mix. The resulting PCR product (1,675 bp) was visualized under ultraviolet light on a 1% agarose gel stained with ethidium bromide after electrophoretic migration. The DNA extraction, PCR amplification, and agarose gel electrophoresis were carried out in separate areas of the laboratory to prevent sample contamination. Different instruments and reagents were used in each one of the areas and special care was taken in handling pre- and post-PCR samples.

Purification of the amplified product was performed with Bioclean DNA Purification columns kit (Biotoools B & M Labs, S. A., Madrid, Spain) according to the manufacturer's instructions, and the DNA was sequenced at the Automatic Sequencing Service of the "Centro de Investigaciones Biológicas" (CSIC) using ABI PRISM 377 DNA sequencer (Applied Biosystems, Foster City, California). To determine the complete sequence of the PCR product, a new internal primer was designed (5'-CTTTTGCCTTGAATACTT-TAGC-3') and it was used in a second sequencing reaction of the same PCR product. The obtained nucleotide sequence was analyzed for homology with other sequences available in the GenBank database. The accession numbers for the 18S rRNA nucleotide sequences of the organisms used for comparison in this study are as follows: *Cytauxzoon* sp., AF531418; *Cytauxzoon* sp., AY309956; *C. felis*, AF399930; *C. felis*, L19080; *Babesia equi*, Z15105; *B. equi*, AY150064; *B. equi*, AY150062; *Babesia felis*, AF244912; *Babesia leo*, AF244911; *Babesia gibsoni*, AF271082; *Babesia microti*, U09833; *Babesia* sp., AF188001; *Babesia bigemina*, X59604; *Babesia canis*, L19079; *Theileria bicornis*, AF499604; *Theileria* sp., U97054; *Theileria* sp., U97055; *Theileria* sp., U97051; *Theileria* sp., AB012196; *Theileria velifera*, AF097993; *Theileria annulata*, M64243; *Theileria parva*, L02366; Piroplasmida WA1, AF158700; *Neospora*

TABLE 1. Iberian lynx (*Lynx pardinus*) samples stored at Doñana National Park (1993–2003).

	<i>n</i>	Blood	Liver	Lung	Others
Captive	9	5	1	3	0
Free-ranging	41	9	16	10	6
Total	50	14	17	13	6

*caninum*, U17345; *Toxoplasma gondii*, L37415. These sequences were analyzed using the MegAlign (version 5.07) component of the Lasergene program (DNASTAR Inc., Madison, Wisconsin, USA). Multiple sequence alignment was performed using Clustal W algorithm to define the relationships among piroplasms and other apicomplexa. A phylogenetic tree was constructed by using the neighbor-joining method and a bootstrap test was conducted to assess the reliability of the nodes of the tree.

Besides this blood sample, 50 blood and tissue samples of Iberian lynx were also processed. These samples were obtained from all dead and alive lynxes that entered the Acebuche Wildlife rehabilitation center (Doñana National Park, Spain) from 1993 to 2003 and were preserved for different studies. For this retrospective epidemiologic study, the sample first chosen for DNA extraction was frozen lung to detect piroplasms in blood and tissues. Blood was analyzed when lung was not available. These samples were preserved in a Tris-sodium dodecyl sulfate-ethylenediamine-tetraacetate (Tris-SDS-EDTA) buffer specifically designed for DNA studies. Finally, other samples such as liver, kidney, or muscle were also processed if lung or blood was not available (Table 1).

DNA extraction from blood samples was performed with the Ultraclean DNA Blood Spin Kit (MoBio Laboratories Inc.) as previously described, and DNA extraction from tissue samples was carried out using the QIAamp DNA Mini Kit (Qiagen®). DNA extractions were performed following manufacturer's instructions of both commercial kits. Unfortunately, no

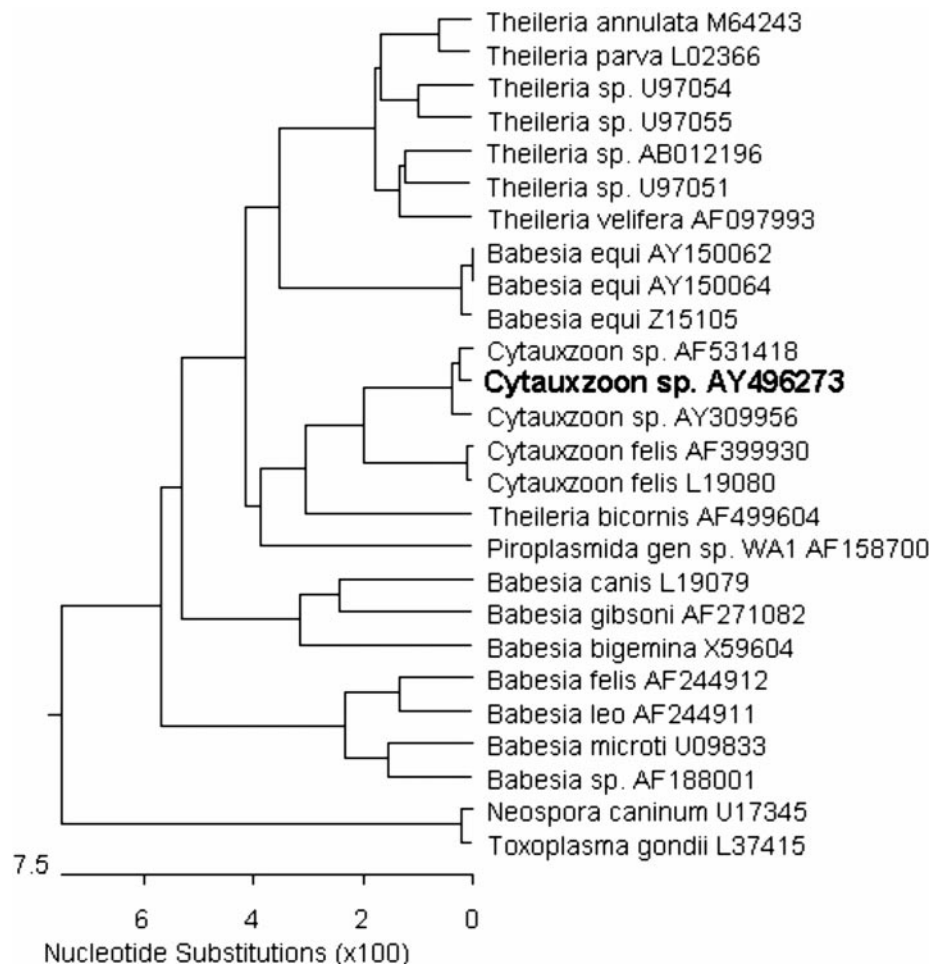


FIGURE 2. Dendrogram showing the genetic relationship between the 18S rRNA sequences of different piroplasms.

positive control for the DNA extraction procedure was available. These DNA samples were analyzed by the same PCR technique as described above.

The hot-start PCR technique performed from the wild-caught lynx blood sample resulted in the amplification of a fragment of 1,675 bp. This PCR product was sequenced and phylogenetically compared with different sequences from other piroplasms previously described. Figure 2 shows the topology of the unknown Iberian lynx piroplasm compared with other piroplasms. The nucleotide sequence reported here has been assigned GenBank accession number AY496273. No amplifi-

cation of the 18S NSS rRNA gene of the organism was obtained from any of the 50 samples stored at Doñana National Park.

We describe an intraerythrocytic protozoan parasite that showed maximum homology with the 18S NSS rRNA gene sequence of *Cytauxzoon* spp. To be more specific, the nucleotide sequence reported here showed eleven differences with the nucleotide sequence of *Cytauxzoon* sp. Spain 1 (GenBank accession number AY309956), reported as the first detection of *Cytauxzoon* sp. from a domestic cat in Spain (Criado-Fornelio, 2004). Besides this similarity, the nucleotide sequence reported here was also very similar (99.6%)



to the nucleotide gene sequence of the 18S NSS rRNA gene recently amplified from a blood sample that was obtained from a wild-caught Pallas's cat (*O. manul*) in Mongolia (GenBank accession number AF531418). In fact, both sequences differ only in eight nucleotides.

This is the first report of erythroparasitemia in Iberian lynx and most likely the first report of a naturally occurring piroplasm in a free-ranging felid from Europe. As no amplification of the piroplasmid 18S NSS rRNA gene was obtained from any of the 47 samples collected from animals from the Doñana population, there is no evidence of the presence of the piroplasm in this population. Besides that, there is also no evidence of the presence of the parasite in the samples from the animals of the Sierra Morena population that were collected previously to the detection of this individual. However, only three samples from this population were analyzed and further investigation should be performed. Nevertheless, all these results should be interpreted cautiously because no positive control for the DNA extraction process was available. On the other hand, *C. felis* is known to have a limited schizogonous phase in the lung and recovery of DNA may not be possible after time (Blouin et al., 1987).

The pathogenic significance of this parasite to the health of free-ranging Iberian lynx is currently uncertain. Logic suggests that it might behave in a way similar to *C. felis* in the bobcat, with the infection most often being subclinical (Walker and Cowell, 1995) but causing some deaths of free-ranging bobcats every year (Nietfeld and Pollock, 2002). To the present date, the infection by this agent has not been associated with the presence of clinical signs in Iberian lynx, but this newly described parasite must be treated as a threat to the species, because we are dealing with a species of a high degree of inbreeding (Johnson et al., 2004) with histologic evidence of immunodeficiency (Peña et al., 2003) including generalized lymphoid depletion

and hyaline deposits in arterioles of lymphoid tissues. Until further investigations concerning pathogenicity of this *Cytauxzoon* sp. in lynx are carried out, precaution should be taken in moving lynx between infected and potentially uninfected populations, as suggested for other endangered feline species (Roelke et al., 1991).

We thank the Junta de Andalucía, Pablo Pereira, Joaquín Valderrama, Narciso Coronel, María de los Ángeles de la Oliva, Concha Iglesias, and Jaime Hervás for their technical support in this work.

#### LITERATURE CITED

- BELTRÁN, J. B., AND M. DELIBES. 1991. Hematological and serum chemical characteristics of the Iberian lynx (*Lynx pardina*) in southwestern Spain. *Canadian Journal of Zoology* 69: 840–846.
- BLOUIN, E. F., A. A. KOCAN, K. M. KOCAN, AND J. HAIR. 1987. Evidence of a limited schizogonous cycle for *Cytauxzoon felis* in bobcats following exposure to infected ticks. *Journal of Wildlife Diseases* 23: 499–501.
- BUTT, M. T., D. BOWMAN, M. C. BARR, AND M. E. ROELKE. 1991. Iatrogenic transmission of *Cytauxzoon felis* from a Florida panther (*Felis concolor coryi*) to a domestic cat. *Journal of Wildlife Diseases* 27: 342–347.
- CRIADO-FORNELIO, A., M. A. GONZALEZ-DEL-RIO, A. BULING-SARANA, AND J. C. BARBA-CARRETER. 2004. The “expanding universe” of piroplasms. *Veterinary Parasitology* 119: 337–345.
- GLENN, B. L., R. E. ROLLEY, AND A. A. KOCAN. 1982. *Cytauxzoon*-like piroplasms in erythrocytes of wild-trapped bobcats in Oklahoma. *Journal of the American Veterinary Medical Association* 181: 1251–1253.
- GUZMÁN, J. N., F. J. GARCÍA, G. GARROTE, R. PEREZ DE AYALA, AND M. C. IGLESIAS. 2003. Resultados del censo diagnóstico de las poblaciones de lince ibérico (*Lynx pardinus*) en España (2002). In *Proceedings: VI Jornadas de la Sociedad Española para la Conservación y el Estudio de los Mamíferos—an Iberian Conference*, Secretaría de la SECEM (ed.). SECEM, Apdo. 15450, 29080, Málaga, Spain, pp. 89.
- HOOVER, J. P., D. B. WALKER, AND J. D. HEDGES. 1994. Cytauxzoonosis in cats: Eight cases, (1985–1992). *Journal of the American Veterinary Medical Association* 205: 455–460.
- JOHNSON, W. E., J. A. GODOY, F. PALOMARES, M. DELIBES, M. FERNANDES, E. REVILLA, AND S. J. O'BRIEN. 2004. Phylogenetic and phylogeographic analysis of Iberian lynx populations. *Journal of Heredity* 95: 19–28.
- KETZ-RILEY, C. J., M. V. REICHARD, R. A. VAN DER

- BUSSCHE, J. P. HOOVER, J. MEINKOTH, AND A. A. KOCAN. 2003. An intraerythrocytic small piroplasm in wild-caught Pallas's cats (*Otocolobus manul*) from Mongolia. *Journal of Wildlife Diseases* 39: 424–430.
- KIER, A. B., J. E. WAGNER, AND L. G. MOREHOUSE. 1982. Experimental transmission of *Cytauxzoon felis* from Bobcats (*Lynx rufus*) to domestic cats (*Felis domesticus*). *American Journal of Veterinary Research* 43: 97–101.
- KIER, A. B., AND C. E. GREENE. 1998. *Cytauxzoonosis*. In *Infectious diseases of the dog and cat*, 2nd Edition, C. E. Greene (ed.). W. B. Saunders Co., Philadelphia, Pennsylvania, pp. 470–473.
- KOCAN, A. A., AND K. M. KOCAN. 1991. Tick transmitted protozoan diseases in wildlife in North America. *Bulletin of the Society of Vector Ecology* 16: 94–108.
- MEINKOTH, J., A. A. KOCAN, L. WHITWORTH, G. MURPHY, J. C. FOX, AND J. P. WOODS. 2000. Cats surviving natural infection with *Cytauxzoon felis*: 18 cases (1997–1998). *Journal of Veterinary Internal Medicine* 14: 521–525.
- NIETFELD, J. C., AND C. POLLOCK. 2002. Fatal cytauxzoonosis in a free-ranging bobcat (*Lynx rufus*). *Journal of Wildlife Diseases* 38: 607–610.
- NOWELL, K., AND P. JACKSON. 1996. Wild cats: Status survey and conservation action plan. UICN/SSC Cat Specialist Group, Gland, Switzerland, 382 pp.
- PENA, L., P. GARCIA, P. FERNANDEZ, M. GALKA, A. BENITO, AND C. SANCHEZ. 2003. Histological evidences of immunodeficiency in Iberian lynx (*Lynx pardinus*). In *Proceedings: 21st Annual Conference of the European Society of Veterinary Pathologists*, Dublin.
- ROELKE, M. E., D. J. FORRESTER, E. R. JACOBSON, AND G. V. KOLLIAS. 1991. Rationale for surveillance and prevention of infectious and parasitic disease transmission among free-ranging and captive Florida panthers (*Felis concolor coryi*). In *Proceedings: AAZV Collected Proceedings 1990–2002*, R. E. Junge (ed.). American Association of Zoo Veterinarians, Calgary, Alberta, Canada, pp. 179–184.
- SHAW, S. E., R. J. BIRTLES, AND M. J. DAY. 2001. Arthropod-transmitted infectious diseases of cats. *Journal of Feline Medicine and Surgery* 3: 193–209.
- WALKER, D. B., AND R. L. COWELL. 1995. Survival of a domestic cat with naturally acquired cytauxzoonosis. *Journal of American Veterinary Medical Association* 209: 1363–1365.

*Received for publication 15 May 2004.*