



Confirmation and Phylogenetic Analysis of Rabbit Hemorrhagic Disease Virus in Free-living Rabbits from the Netherlands

Authors: van de Bildt, M. W. G., van Bolhuis, G. H., van Zijderveld, F., van Riel, D., Drees, J. M., et al.

Source: Journal of Wildlife Diseases, 42(4) : 808-812

Published By: Wildlife Disease Association

URL: <https://doi.org/10.7589/0090-3558-42.4.808>

BioOne Complete (complete.BioOne.org) is a full-text database of 200 subscribed and open-access titles in the biological, ecological, and environmental sciences published by nonprofit societies, associations, museums, institutions, and presses.

Your use of this PDF, the BioOne Complete website, and all posted and associated content indicates your acceptance of BioOne's Terms of Use, available at www.bioone.org/terms-of-use.

Usage of BioOne Complete content is strictly limited to personal, educational, and non - commercial use. Commercial inquiries or rights and permissions requests should be directed to the individual publisher as copyright holder.

BioOne sees sustainable scholarly publishing as an inherently collaborative enterprise connecting authors, nonprofit publishers, academic institutions, research libraries, and research funders in the common goal of maximizing access to critical research.

SHORT COMMUNICATIONS

Journal of Wildlife Diseases, 42(4), 2006, pp. 808–812
© Wildlife Disease Association 2006

Confirmation and Phylogenetic Analysis of Rabbit Hemorrhagic Disease Virus in Free-living Rabbits from the Netherlands

M. W. G. van de Bildt,¹ G. H. van Bolhuis,¹ F. van Zijderveld,² D. van Riel,¹ J. M. Drees,³ A. D. M. E. Osterhaus,¹ and T. Kuiken^{1,4} ¹ Dutch Wildlife Health Centre, based at Department of Virology, Erasmus Medical Centre, PO Box 1738, 3000 DR Rotterdam, The Netherlands and Faculty of Veterinary Medicine, University of Utrecht, The Netherlands; ² Vereniging Natuurmonumenten, Noordereinde 60, 1234 JJ 's-graveland, The Netherlands; ³ Community and Conservation Ecology, University Groningen, PO Box 14, 9750 Haren, The Netherlands; ⁴ Corresponding author (email: t.kuiken@erasmusmc.nl)

ABSTRACT: The number of free-living European rabbits (*Oryctolagus cuniculus*) in the Netherlands has declined dramatically in recent years. Although rabbit hemorrhagic disease virus (RHDV) infection has been implicated as a possible cause of this decline, the definitive diagnosis has not been reported. We examined three free-living rabbits found dead in the Netherlands in 2004 by use of gross pathology, histopathology, immunohistochemistry, and reverse transcriptase polymerase chain reaction. We subsequently compared the identified virus with RHDV from elsewhere in the world by phylogenetic analysis. There was widespread necrosis, hemorrhage, or both in liver, kidney, spleen, and lungs of all three rabbits, consistent with RHDV infection. The presence of RHDV in affected tissues was demonstrated by immunohistochemistry and reverse transcriptase polymerase chain reaction. The RHDV from the Netherlands showed the highest identity, 99%, with a strain from France in 2000, and fitted in genogroup G5. These results prove that RHDV infection causes mortality of free-living rabbits in the Netherlands and suggest that RHDV strains circulating in free-living rabbits in the Netherlands and France have a common source or that one has originated from the other.

Key words: Calicivirus, *Oryctolagus cuniculus*, phylogeny, rabbit, RHDV.

The number of free-living European rabbits (*Oryctolagus cuniculus*) in the Netherlands has declined dramatically in recent years (Bijlsma, 2004; Drees and Van Maanen, 2005). The reasons for this are unclear. Possible explanations include habitat loss, a series of severe winters, the emergence of an infectious disease such as rabbit hemorrhagic disease (RHD), or a combination of these factors. The rabbit

used to be very common on the sandy soils of the Netherlands and especially on the coastal dunes. However, rabbit numbers on coastal dunes declined between 10% and 30% per year since 1990, resulting in an overall decrease of 90% between 1990 and 2003. Similar declines have been recorded for rabbit numbers from inland habitats (Bijlsma, 2004; Drees and Van Maanen, 2005).

Although implicated as a possible cause of the above decline, the definitive diagnosis of RHD has not been reported in free-living rabbits from the Netherlands. Rabbit hemorrhagic disease has spread rapidly throughout Europe and other continents since its emergence in 1984 in China (Liu et al., 1984), and is now endemic in most parts of the world. In Europe, the spread of RHD raised serious concerns, because the rabbit is important both as an element of the ecosystem and as a game species (Cooke, 2002). Rabbit hemorrhagic disease in free-living rabbits in the Netherlands was first suspected in 1990, when unusual mortality of free-living rabbits, some with blood-stained nasal discharge, was reported (Siebenga, 1991). At that time, RHD was diagnosed in nine of 10 rabbits by postmortem examination, but the methods were not stated (Siebenga, 1991). Subsequently, antibodies to RHDV were detected in 12% of sera from 33 free-living rabbits, collected from different regions in the Netherlands in 1991 and 1992 (Van Maanen et al., 1996). However, serology

does not distinguish between RHDV and other, non-pathogenic caliciviruses (Cappucci et al., 1996; White et al., 2002).

In November 2004, three carcasses of free-ranging rabbits found in the dunes of the island Goeree-Overflakkee in Zeeland Province, The Netherlands, were presented for necropsy to the Dutch Wildlife Health Centre. They were the only freshly dead rabbit carcasses found on the island. No mortality of rabbits was noted on the neighboring islands Voorne and Schouwen-Duiveland. The rabbits had probably died less than 24 hr before they were found, based on the stiffness of the carcasses. The carcasses of these adult rabbits were mildly to moderately autolyzed and in a moderate to good nutritional condition. Detailed postmortem examinations were performed on the carcasses and samples were taken for routine histology, as well as for immunohistochemistry and RT-PCR.

For immunohistological detection of RHDV antigen, formalin-fixed, paraffin-embedded tissue sections were deparaffinized and pre-treated with 0.1% protease (Sigma, St. Louis, Missouri, USA) for 10 min at 37 C. Guinea pig serum against RHDV (a kind gift from Per Have, Danish Institute for Food and Veterinary Research) was incubated for 1 hr at room temperature and detected with a peroxidase-labeled rabbit-anti-guinea pig immunoglobulin (DAKO, Glostrup, Denmark). Peroxidase was revealed with 3-amino-9-ethyl-carbazole (Sigma) resulting in a bright red precipitate. A negative guinea pig serum and omission of serum were included as negative controls for all tissues. Tissues were counterstained with hematoxylin and embedded in glycerol-gelatin. The following tissues were examined by this method: heart, jejunum, kidney, liver, lung, spleen, and trachea of all three rabbits, adrenal gland, cecum, colon, lymph node, skeletal muscle, skin, and stomach of two rabbits, and abdominal wall, duodenum, esophagus, ovary, urinary bladder, testis, and thyroid of one rabbit.

From all three rabbits, samples of kidney, liver, lung and spleen as well as the bladder and jejunum from one rabbit and the bladder or jejunum from the other two rabbits were preserved in lysis buffer for RNA isolation. Total nucleic acids were isolated using the High Pure Viral Nucleic Acid Kit (Roche Diagnostics GmbH, Mannheim, Germany). Reverse transcriptase polymerase chain reaction was performed in a one-tube system, using primers REF: 5' CAACCTCCAGCC-CACCACCAACAC 3' and REB: 5' TGTTGGGAGCCTGTGCCGTA CTG 3' as described previously (Bascañana et al., 1997), which amplify a 316-base pair fragment of the VP60 gene located at nucleotide positions 6482 to 6782. Automated nucleotide sequencing of PCR fragments was performed on an ABI 3130XL genetic analyser with the Big Dye terminator cycle sequencing kit (ABI, Applied Biosystems, Foster City, California, USA) using the same primers as above. The resultant nucleotide sequences were compared with published sequences of RHDV by use of the DNASTAR software package (DNASTAR, Inc., Madison, Wisconsin, USA) to confirm the identity of the RT-PCR product. For phylogenetic analysis, the 316-base pair fragment of the VP60 gene of RT-PCR products obtained in this study were compared with sequences from the Genbank database representing the different genotypes using the Phylip package (Felsenstein, 2004).

The main gross changes were seen in lungs, liver, kidneys, and spleen of all three rabbits. The lungs had multiple or coalescing, dark red, firm areas, which were only partly collapsed. The liver was diffusely pale, slightly swollen, and—in one rabbit—had an enhanced lobular pattern. The kidneys were diffusely dark red to red-black. The spleen was diffusely dark red and mildly to moderately swollen. In all three rabbits, the stomach was filled with grass.

The main histological lesions in all three rabbits were found in the liver, kidney,

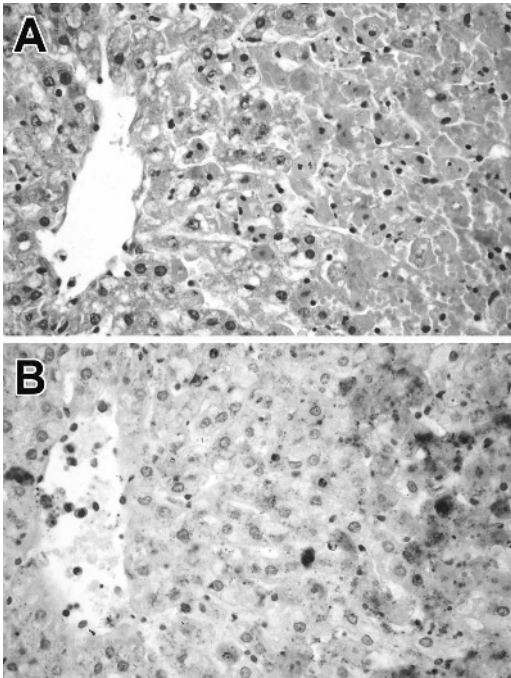


FIGURE 1. Hepatic necrosis in a free-living rabbit with rabbit hemorrhagic disease. **A.** Liver of rabbit no. 2. The hepatocytes in the right half of the panel are necrotic. Note the loss or pyknosis of nuclei and the hyper-eosinophilia of the cytoplasm of affected hepatocytes. The hepatocytes in the left half of the panel surround the lumen of the hepatic venule and are relatively normal. Hematoxylin and eosin. Original magnification $100\times$. **B.** Liver of rabbit no. 2. Serial section of panel A. Rabbit hemorrhagic disease virus antigen is visible as dark red staining in the nucleus and cytoplasm of affected hepatocytes. Virus antigen expression is mainly localized to the necrotic hepatocytes in the right side of the panel. Immunoperoxidase stain for rabbit hemorrhagic disease virus antigen. Original magnification $100\times$.

spleen, and lung. In the liver (Fig. 1A), there was widespread hepatocytic necrosis, often sparing the perivenular areas (zone 3). Affected hepatocytes were separated from the hepatic plates, were rounded, and had hyper-eosinophilic cytoplasm and fragmented or pyknotic nuclei. In the kidney, there was generalized global necrosis and thrombosis of glomeruli, characterized by pyknosis of glomerular cells and the presence of fibrin thrombi in congested glomerular capillaries. One of three rabbits also had multiple

foci of cortical tubular hemorrhage. In the spleen, there was diffuse necrosis. The red pulp of the spleen was diffusely replaced by abundant fibrin mixed with a few reticular cells, erythrocytes, and cell debris. The white pulp had marked loss of lymphocytes, and contained moderate numbers of necrotic lymphocytes and cell debris. In the lung, multifocal pulmonary hemorrhage and edema were found, characterized by flooding of the alveolar lumina with serous fluid, erythrocytes, or a mixture of both. Minor histologic lesions in other tissues were few small foci of myocardial hemorrhage in the right ventricle of one of three rabbits, and mild to moderate congestion of the tracheal submucosa in two of three rabbits. No significant histologic lesions were detected in the other tissues examined.

By immunohistochemistry, expression of RHDV antigen was visible as dark red granular staining in the cytoplasm and, less frequently, in the nucleus of affected cells. Expression of RHDV antigen was seen in the liver (Fig. 1B) and kidney of all three rabbits, in the spleen of two rabbits, and in the ovaries of one rabbit. Cells expressing viral antigen included hepatocytes, glomerular cells, cortical tubular cells, large mononuclear or dendritic cells in the spleen, and ovarian stromal cells. There was specific staining in blood vessel lumina of multiple tissues, but this was not cell-bound. In liver, kidney, and spleen, RHDV antigen expression was closely associated with the presence of histologic lesions. Expression of RHDV was absent in both isotype and omission controls. The acrosomal vesicles of spermatids in the testis of one rabbit showed nonspecific light brown staining (not shown).

By RT-PCR, all samples ($n=16$) but one, the jejunum of rabbit number two, showed a clear band of approximately the right size upon analysis on a 2% agarose gel. Nucleotide sequencing of PCR fragments confirmed the presence of RHDV in all three rabbits. Comparison of the 316-base pair fragment of the VP60 gene

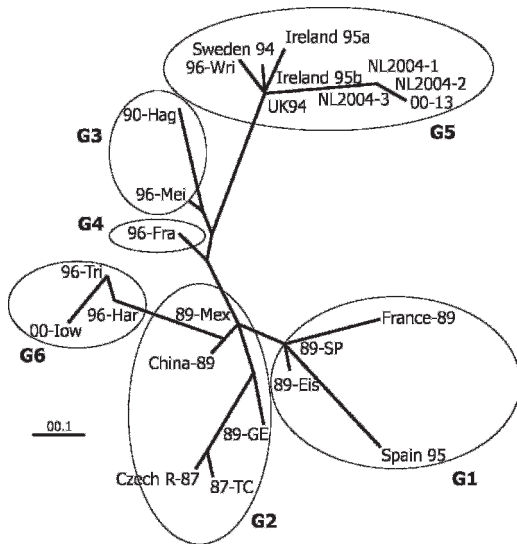


FIGURE 2. Phylogenetic tree of rabbit hemorrhagic disease virus based on a 316 nucleotide fragment of the VP60 gene. The viruses from the Netherlands fit in genotype group 5 and show the highest identity with a virus from France in 2000. The maximum likelihood tree was generated with the SEQBOOT and DNAML program of the Phylip package with 500 bootstraps. Genbank accession numbers are given in parentheses: France-89 (Z29514); 89-SP, Spain (Z49271); Spain 95 (U65348); 89-Eis, Germany (Y15440); 87-TC, Czechoslovakia (U54983); Czech R-87 (Z11535); 89-GE, Germany (M67473); China-89 (U65328); 89-Mex, Mexico (AF295785); 96-Fra, Germany (Y15424); 90-Hag, Germany (Y15441); 96-Mei, Germany (Y15426); 96-Har, Germany (Y15425); 96-Tri, Germany (Y15442); 00-Iow, USA (AF258618); Sweden 94 (U65351); UK94 (U65355); Ireland 95a (U65335); Ireland 95b (U65336); 96-Wri, Germany (Y15427); 00-13, France (AJ495856); NL2004-1 (DQ296063); NL2004-2 (DQ296064); NL2004-3 (DQ296065).

with sequences from the Genbank database showed the highest identity of 99% with a French strain from the year 2000, isolate 00-13 (Le Gall-Reculé et al., 2003). The sequences derived from the Dutch rabbits formed a cluster with the genotype group G5 sequences according to the genotypic characterization of Le Gall-Reculé and others (Le Gall-Reculé et al., 2003) (Fig. 2).

This is the first proof of RHD in free-living rabbits in the Netherlands. The diagnosis was based on the combination

of pathology, immunohistochemistry, and nucleotide sequencing of the RT-PCR product. The gross lesions, histopathologic, and immunohistochemistry findings correspond to those found previously in RHDV-infected rabbits (Fuchs and Weissenböck, 1992; Prieto et al., 2000; Lenghaus et al., 2001). To our knowledge, RHDV antigen expression in ovarian tissue has not been reported before. By phylogenetic analysis, the RHDV from the Netherlands was characterized as a member of the genotype group G5, most closely related to a French isolate from the year 2000 (Fig. 2). This suggests that the viruses from these two areas have a common source or that the one originated from the other. Possible routes of RHDV transmission between these two areas include: 1) direct transmission among contiguous populations of free-living rabbits, 2) transmission by flying insects (McCull et al., 2002), and 3) transport by humans of infected rabbits, infected insects, or contaminated fomites (Cooke, 2002). The virus is extremely resistant and remains viable in carcasses in the field for at least three months (Henning et al., 2005).

We gratefully acknowledge Jolianne Rijks, Fiona Read, and Frank van der Panne for their excellent technical assistance.

LITERATURE CITED

- BASCUÑANA, C. R., N. NOWOTNY, AND S. BELÁK. 1997. Detection and differentiation of rabbit hemorrhagic disease and European brown hare syndrome virus by amplification of VP60 genomic sequences from fresh and fixed tissue specimens. *Journal of Clinical Microbiology* 35: 2492-2495.
- BIJLSMA, R. G. 2004. Long term population trends of rabbits (*Oryctolagus cuniculus*) on Pleistocene sands in the central and northern Netherlands. *Lutra* 47: 3-20.
- CAPUCCI, L., P. FUSI, A. LAVAZZA, M. L. PACCIARINI, AND C. ROSSI. 1996. Detection and preliminary characterization of a new rabbit calicivirus related to rabbit hemorrhagic disease virus but nonpathogenic. *Journal of Virology* 70: 8614-8623.
- COOKE, B. D. 2002. Rabbit haemorrhagic disease: Field epidemiology and the management of wild

- rabbit populations. *Revue Scientifique et Technique (Office International des Epizooties)* 21: 347–358.
- DREES, M., AND Y. VAN MAANEN. 2005. Hoe gaat het met het konijn. *Sovon-Nieuws* 18: 12.
- FELSENSTEIN, J. 2004. PHYLIP (Phylogeny Inference Package), computer software version 3.6. Department of Genome Sciences, University of Washington, Seattle, Washington, USA.
- FUCHS, A., AND H. WEISSENBOCK. 1992. Comparative histopathological study of rabbit haemorrhagic disease (RHD) and European brown hare syndrome (EBHS). *Journal of Comparative Pathology* 107: 103–113.
- HENNING, J., J. MEERS, P. R. DAVIES, AND R. S. MORRIS. 2005. Survival of rabbit haemorrhagic disease virus (RHDV) in the environment. *Epidemiology and Infection* 133: 719–730.
- LE GALL-RECULE, G., F. ZWINGELSTEIN, S. LAURENT, C. DE BOISSESON, Y. PORTEJOIE, AND D. RASSCHAERT. 2003. Phylogenetic analysis of rabbit haemorrhagic disease virus in France between 1993 and 2000, and the characterisation of RHDV antigenic variants. *Archives of Virology* 148: 65–81.
- LENGHAUS, C., M. J. STUDDERT, AND D. GAVIER-WIDEN. 2001. Calicivirus infections. *In Infectious diseases of wild mammals*, E. S. Williams and I. K. Barker (eds.). Manson Publishing Ltd., London, United Kingdom, pp. 280–291.
- LIU, S. J., H. P. XUE, B. Q. PU, AND N. H. QUIAN. 1984. A new viral disease in rabbits. *Animal Husbandry and Veterinary Medicine* 16: 253–255.
- MCCOLL, K. A., J. C. MERCHANT, J. HARDY, B. D. COOKE, A. ROBINSON, AND H. A. WESTBURY. 2002. Evidence for insect transmission of rabbit haemorrhagic disease virus. *Epidemiology and Infection* 129: 655–663.
- PRIETO, J. M., F. FERNANDEZ, V. ALVAREZ, A. ESPI, J. J. GARCIA MARIN, M. ALVAREZ, J. M. MARTIN, AND F. PARRA. 2000. Immunohistochemical localisation of rabbit haemorrhagic disease virus VP-60 antigen in early infection of young and adult rabbits. *Research in Veterinary Science* 68: 181–187.
- SIEBENGA, S. 1991. Virusziekte bij hazen (EBHS) en konijnen (VHS) nu ook in Nederland. *De Nederlandse Jager* 96: 4–6.
- VAN MAANEN, C., N. H. M. T. PEPEKAMP, S. G. TH. ZUTHOFF, G. H. M. VAN LOGTESTIJN, D. R. MEKKES, H. W. A. VAN DE SANDE, AND M. H. VAN DER HAGE. 1996. Viral haemorrhagic disease: een overzicht en eigen bevindingen. *Tijdschrift voor Diergeneeskunde* 121: 184–188.
- WHITE, P. J., R. A. NORMAN, AND P. J. HUDSON. 2002. Epidemiological consequences of a pathogen having both virulent and avirulent modes of transmission: the case of rabbit haemorrhagic disease virus. *Epidemiology and Infection* 129: 665–677.

Received for publication 3 January 2006.