

Pruritic Facial Dermatitis in a Population of Free-living Stitchbirds

Authors: Low, Matthew, Alley, Maurice R., and Scott, Ian

Source: Journal of Wildlife Diseases, 43(2) : 262-268

Published By: Wildlife Disease Association

URL: <https://doi.org/10.7589/0090-3558-43.2.262>

The BioOne Digital Library (<https://bioone.org/>) provides worldwide distribution for more than 580 journals and eBooks from BioOne's community of over 150 nonprofit societies, research institutions, and university presses in the biological, ecological, and environmental sciences. The BioOne Digital Library encompasses the flagship aggregation BioOne Complete (<https://bioone.org/subscribe>), the BioOne Complete Archive (<https://bioone.org/archive>), and the BioOne eBooks program offerings ESA eBook Collection (<https://bioone.org/esa-ebooks>) and CSIRO Publishing BioSelect Collection (<https://bioone.org/csiro-ebooks>).

Your use of this PDF, the BioOne Digital Library, and all posted and associated content indicates your acceptance of BioOne's Terms of Use, available at www.bioone.org/terms-of-use.

Usage of BioOne Digital Library content is strictly limited to personal, educational, and non-commercial use. Commercial inquiries or rights and permissions requests should be directed to the individual publisher as copyright holder.

BioOne is an innovative nonprofit that sees sustainable scholarly publishing as an inherently collaborative enterprise connecting authors, nonprofit publishers, academic institutions, research libraries, and research funders in the common goal of maximizing access to critical research.

Pruritic Facial Dermatitis in a Population of Free-living Stitchbirds

Matthew Low,^{1,2,3,4} Maurice R. Alley,² and Ian Scott^{2,1} Ecology Group, Institute of Natural Resources, Massey University, Private Bag 11 222, Palmerston North, New Zealand; ² Institute of Veterinary, Animal, and Biomedical Sciences, Massey University, Private Bag 11 222, Palmerston North, New Zealand; ³ Current address: Australian Antarctic Division, Southern Ocean Ecosystem Program, 203 Channel Highway, Kingston 7050, Tasmania, Australia; ⁴ Corresponding author (email: matt.low@aad.gov.au)

ABSTRACT: From September 2001 to February 2005, observations of an island population of the New Zealand stitchbird (*Notiomystis cincta*) revealed a progressive feather-losing dermatitis, which developed during the breeding season around the birds' eyes, base of the bill, and ventral neck. The lesions were significantly more likely to develop in males (96%) than females (51%), with males exhibiting a more severe form of the condition at the end of the breeding season. Histology from a dead bird revealed the presence of ovoid burrowing mites within the lesions, and isolation of mites from skin crusts of a live bird were identified as *Knemidocoptes* spp. Although other factors might be involved in the expression of the condition, *Knemidocoptes* appears to be a likely causative agent in the development of skin lesions in this population.

Key words: Bird, dermatitis, feather, hihi, *Knemidocoptes*, lousefly, mite, *Notiomystis cincta*, translocation.

The stitchbird (or hihi: *Notiomystis cincta*) is an endangered passerine, restricted in its distribution to three islands off the coast of New Zealand (Higgins et al., 2001) and one newly established population on the mainland. The New Zealand Department of Conservation has attempted to establish new populations to improve its status in the wild (Taylor et al., 2005); however, until recently many of these translocations have been unsuccessful. Reasons proposed for its poor translocation success include lack of food at crucial times of the year (Armstrong and Ewen, 2001), competition from honeyeater species (Wilson, 1997), and the impact of disease (Alley et al., 1999). Because of the suggested link between disease and the viability of stitchbird populations, when a feather-losing dermatitis was observed in the Tiritiri Matangi Island stitchbird population, an effort was made to: 1) describe the lesions as they pre-

sented in individual stitchbirds and assess lesion prevalence within the population, 2) determine the likely causative agent of the dermatitis, and 3) evaluate the implications of this disease for recovery of the species.

During the breeding seasons between September 2001 and February 2005, stitchbirds on Tiritiri Matangi Island (36°36'S, 174°53'E), New Zealand, were observed with areas of feather loss around their face and neck (Fig. 1). Lesions were first seen in September 2001, and during the next 5 mo a steady increase in the prevalence and severity of the condition was noted; this was not an artifact of monitoring effort, because the level of monitoring of individual birds remained constant during this period (see Low, 2005 for details). Lesions were associated with an obvious pruritis, which manifested as face rubbing on twigs and branches and the bird scratching its face and neck with its foot.

In February 2002, at the end of that breeding season but before molting, all adult birds (males=25, females=29) were captured using cage traps at supplementary feeding stations (see Low, 2006 for details of capture). Birds with feather loss or skin crusting were evaluated, with the extent of lesions scored on a half point scale from 0–3 (0=none, 3=extensive) for their face, ventral beak, and ventral neck; lesions were not found on other parts of the body. On close examination of the lesions, feather loss and feather shortening (breakage) were observed, suggesting mechanical factors were involved, such as rubbing or scratching. In mildly affected individuals, lesions were confined to the head and consisted of patchy areas of

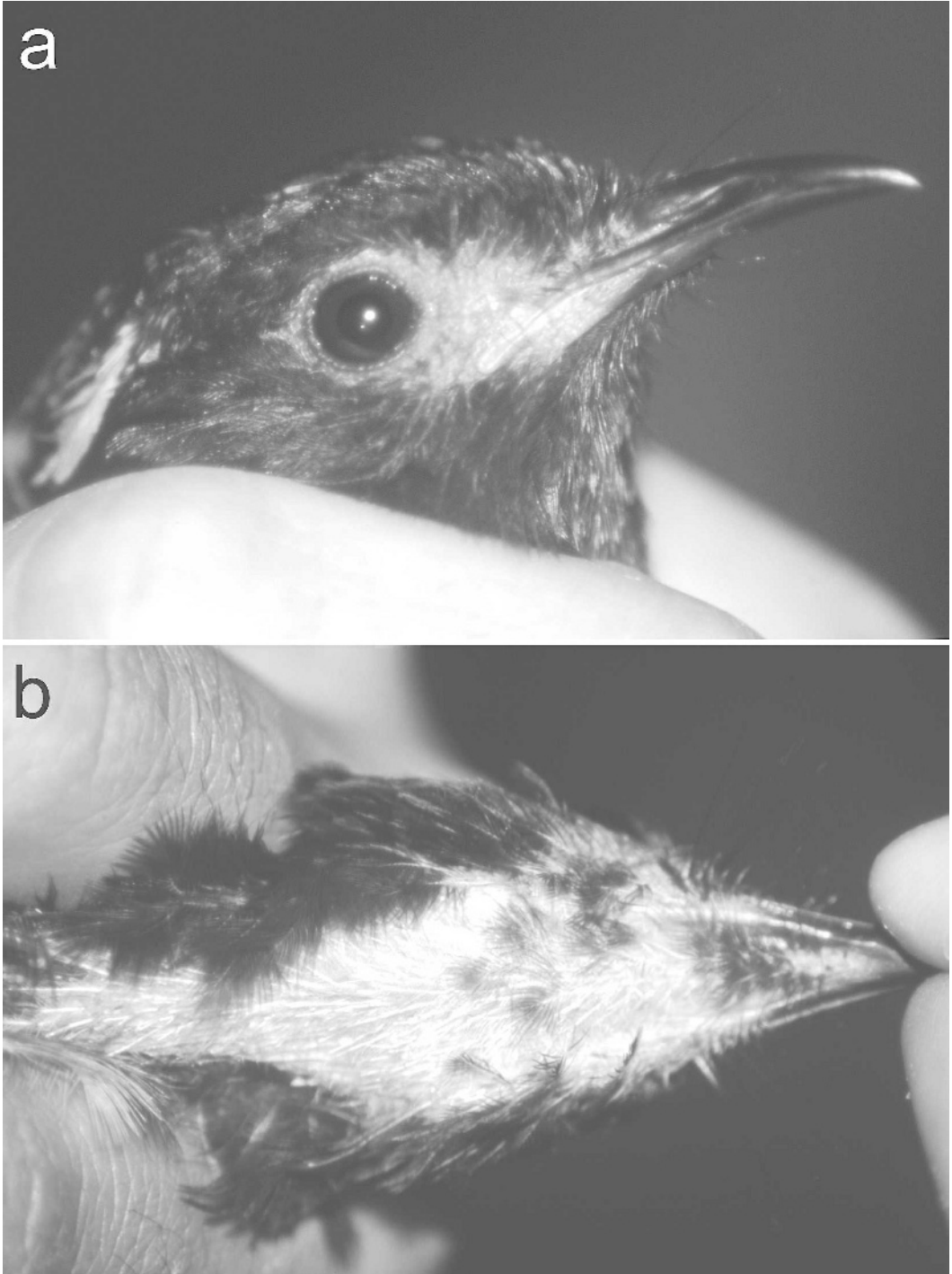


FIGURE 1. Suspected mite-induced feather loss in a male stitchbird characterized by patchy feather loss around the eyes (a) and the ventral neck (b).

feather loss around the eyes and between the eyes and beak (Fig. 1a). In severe cases, these lesions were more extensive and involved crusting around the base of the bill, and feather loss extending ventrally from the tip of the lower bill to the top of the carina of the breast (Fig. 1b). There was a significant positive correlation between the presence and severity of head lesions and the appearance and extent of ventral neck lesions (Spearman rank-order correlation: $r_s=0.56$, $n=54$, $P<0.001$) supporting the hypothesis that the lesions in the two areas were part of the same syndrome. Males were significantly more likely to exhibit lesions than females (24 of 25 males versus 15 of 29 females; Chi-Square: $\chi^2=13.1$, $df=1$, $P<0.001$) and of birds with lesions, males were more likely to have lesions extending to the ventral neck area (12 of 24 versus 4 of 15 females; Fisher's exact test: $P=0.038$). Louseflies (Diptera: Hippoboscidae) were observed in the feathers of males significantly more often than in females (17 of 25 males versus 9 of 29 females; Chi-square: $\chi^2=7.35$, $df=1$, $P=0.006$), although there was no correlation between the presence of flies and the presence of lesions (21 of 26 birds with louseflies had lesions versus 18 of 28 birds without louseflies; Chi-square: $\chi^2=1.8$, $df=1$, $P=0.18$).

In June 2003, 30 male and 28 female stitchbirds were caught and had their lesions described in order to compare the prevalence and severity of lesions at two different times of the year: 1) post-molting prebreeding (June), and 2) pre-molting postbreeding (February). In June, lesions were relatively rare (males=17%, females=11%) and were restricted to the face and ventral beak; no ventral neck lesions were observed. Lesion scores for each of the three areas examined (face, beak, and neck) were summed and compared between the June and February groups. The severity of lesions was significantly lower in June for males (June= 0.18 ± 0.06 ; February= 3.86 ± 0.51 ; Mann-Whitney U : $Z=6.11$, $n_1=25$, $n_2=30$,

$P<0.001$) and females (June= 0.12 ± 0.07 ; February= 1.29 ± 0.29 ; $Z=3.47$, $n_1=28$, $n_2=29$, $P=0.003$). Males were not more likely than females to have lesions at this time of year (Chi-square: $\chi^2=0.43$, $df=1$, $P=0.51$), nor were males more likely than females to have more extensive lesions (Mann-Whitney U : $Z=0.52$, $n_1=28$, $n_2=30$, $P=0.59$).

A likely cause for the condition was first suggested in November 2001, when a 5-yr-old male stitchbird exhibiting facial and ventral-neck feather loss was found dead inside a nest box. Skin samples from the affected areas were preserved in 10% buffered formalin and processed routinely for histology (stained with hematoxylin and eosin, sectioned at 5 μ m). Histologic examination revealed a generalized loss of feather follicles, and extensive areas of epidermal orthokeratotic hyperkeratosis, which was most severe at the base of the skin folds. Several subcorneal pustules were present in the hyperkeratotic areas and approximately 6–8 cross-sections of individual burrowing mites were found beneath the stratum corneum in each skin section examined (Fig. 2). The mites each had a round or ovoid body, short legs, and were often associated with irregular focal areas of acanthosis in the adjacent epidermis. Subsequently, five male stitchbirds that died of other causes, but lacked lesions, were examined histologically; none had any evidence of these mites in the corresponding areas of their skin.

In an attempt to isolate this burrowing mite, a deep skin scraping of the lesions of 25 affected birds was attempted in February 2002; glycerol was applied to the lesion and a #20 scalpel blade was used to collect superficial skin tissue. Scrapings were examined under magnification after being concentrated onto a microscope coverslip via suspension in 1 M sucrose. Four of the 25 samples contained a feather mite (identified by Maria Minor as *Hemialges* spp.; Figs. 3a, b), but none of the ovoid burrowing mites were isolated. Although this potentially reflects a lack

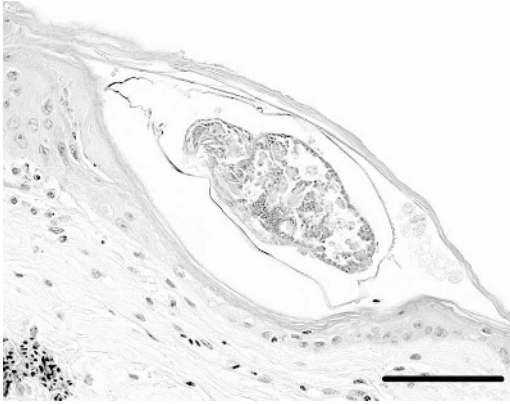


FIGURE 2. Hematoxylin and eosin stain of a 5- μ m-thick skin section taken from a lesion on the neck of a dead male stitchbird. Within the stratum corneum, the cross-section of a burrowing mite consistent with *Knemidocoptes* spp. is clearly visible (arrow). Bar=100 μ m.

of association between the burrowing mites and the lesions being sampled, it is probable that this sampling method was inadequate because of two factors: 1) the burrowing mites are usually beneath the stratum corneum; thus, this makes them difficult to dislodge during a skin scraping (c.f., skin scrapings for *Sarcoptes scabiei*; Scott et al., 2001), and 2) the lesions were small and could not be properly sampled because of overlying denuded feather

shafts; this resulted in the blade often scraping the feathers rather than the skin.

In November 2002, we caught an adult male stitchbird with extensive 3 mm-thick, proliferative crusting around his eyes and head, and associated feather loss; this caused distortion of the eyelid margins and an inability to properly close his eyes (Fig. 4a). The reason for the severity of the lesions in this particular bird was that he had lost his left foot, and thus was unable to preen his head. From the crusts, a large number of burrowing mites were concentrated onto a coverslip via suspension in 1 M sucrose and identified from photomicrographs by Allan Heath as *Knemidocoptes* spp. (Fig. 3c). This mite has been recorded from the skin of at least three other avian species in New Zealand (budgerigar *Melopsittacus undulatus*, red-crowned kakariki *Cyanoramphus novaezealandiae novaezealandiae*, and the domestic fowl *Gallus domesticus*; Shoshana and Uri, 1993; Bishop and Heath, 1998), and was consistent with those found in the histologic skin sections described above (the samples are held in permanent storage at the Institute of Veterinary, Animal, and Biomedical Sciences, Massey University, NZ; pathology reference No. 32802). In

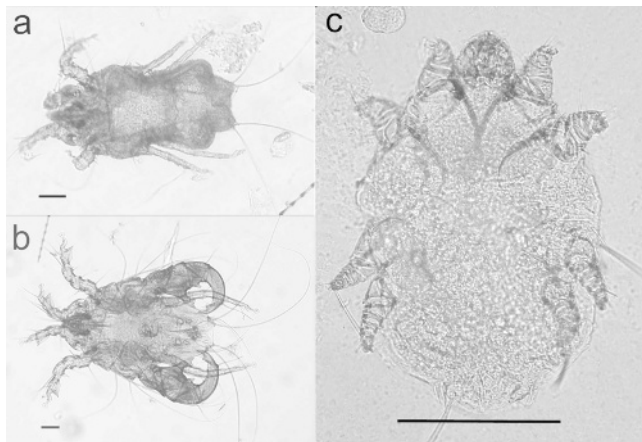


FIGURE 3. Various mites recovered from skin scrapings and crusts of adult male stitchbirds. Several feather mites were recovered as seen in (a) and (b). The burrowing mite, *Knemidocoptes* spp., in (c) is believed responsible for the feather-losing condition described. Bars=100 μ m.

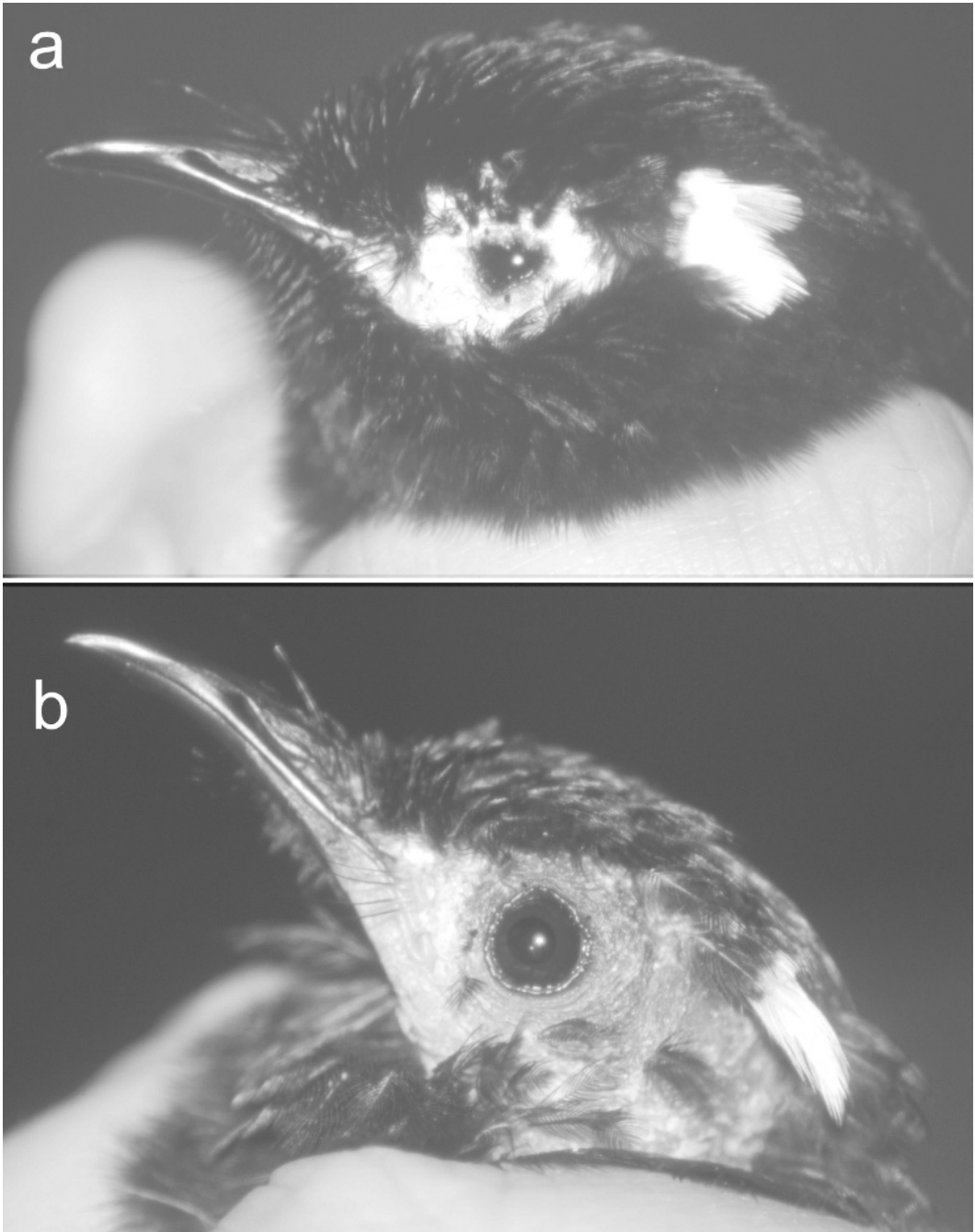


FIGURE 4. The male stitchbird used for a therapeutic trial of an oral miticide (Ivermectin 200 $\mu\text{g}/\text{kg}$). (a) shows the bird immediately pretreatment with severe skin crusting and obvious deformation of the eyelid margins. Five weeks posttreatment the bird showed no crusting and normal function of the eyelid margins (b). The skin around the eyes appeared healthy with the exception of some hyperpigmentation and feather loss.

order to determine whether these mites were responsible for the crusting lesions, the bird was administered an oral miticide effective against *Knemidocoptes* (Ivermectin 200 µg/kg; Ivomec® liquid for sheep, 800 µg/ml, MSD-AgVet) and recaptured 5 wk later for assessment of this therapeutic trial. At recapture, all crusting lesions around the eyes and under the feathers on his head had disappeared and his eyelids appeared to be functioning normally (Fig. 4b). This response to miticide treatment was compatible with our hypothesis that *Knemidocoptes* was the primary cause of the dermatitis.

The likelihood of stitchbirds surviving the winter was not significantly different for birds with lesions versus those without (13 of 15 birds without lesions survived versus 36 of 39 birds with lesions; Fisher's exact test: $P=0.61$). The presence of lesions did not significantly affect the weight or condition of females at the time of measurement (weight; t -test: $t=0.85$, $df=26$, $P=0.40$; condition; $t=0.86$, $df=26$, $P=0.39$; males could not be compared because there was only one male without lesions) nor was the severity of mite lesions correlated with the weight or condition of birds at the time of examination in February 2002 (Pearson product-moment correlation; male weight: $r=-0.05$, $n=25$, $P=0.81$; female weight: $r=0.16$, $n=28$, $P=0.40$; male condition: $r=0.28$, $n=25$, $P=0.16$; female condition: $r=-0.16$, $n=28$, $P=0.39$). This suggests that any need to treat or eradicate the mites is currently not justified. However, because the Tiritiri Matangi population is earmarked as a source population for future translocations of this species, conservation managers will need to consider carefully these results. It might still be necessary to establish whether this condition exists outside of the study population prior to future stitchbird transfers, because limiting the spread of diseases is a focus of current translocation efforts in New Zealand.

The higher prevalence and severity of

lesions in males during the breeding season suggests that they are encountering a higher parasite challenge during this period, or that they are more susceptible to parasite infection during breeding. This difference between the sexes could come about from differences in contact between conspecifics (and, hence, parasite exposure and spread), or differences in susceptibility associated with immune function. In stitchbirds, it is thought that their high susceptibility to aspergillosis is at least in part due to a testosterone-mediated reduction in immune function (Alley et al., 1999). In other species, an interaction between parasite fecundity and the host immune system that exhibits a seasonality directly related to male hormone profiles has been shown (reviewed in Folstad and Karter, 1992).

Biopsies from the lesions of other affected stitchbirds are still needed to confirm the hypothesis that the *Knemidocoptes* found in this study are responsible for the facial and ventral-neck lesions seen in the wider population. However, despite the small amount of data available, the weight of evidence points to these mites being a causative agent for the following reasons: 1) small ovoid burrowing mites, their size and shape consistent with *Knemidocoptes*, were found in large numbers in the stratum corneum of lesions in an affected bird, and were not found in corresponding areas of skin in unaffected birds; 2) large numbers of *Knemidocoptes* were found in the skin crusts on the head of a severely affected bird, and these lesions resolved and mites disappeared after the administration of an oral miticide; and 3) in all birds the lesions were restricted to the area around the beak and head, which is a common distribution in avian knemidocoptic mange or "scaly-face" disease (Madill, 1987; Ritchie et al., 1994). Unfortunately, because the stitchbird is an endangered species and recovery efforts are ongoing, skin samples from affected birds will have to continue being obtained opportunistically, and thus,

it could be some time before a definitive diagnosis can be made.

We thank T. Makan, Å. Berggren, S. Jack, I. Fraser, T. Henry, R. Stamp, B. Walter, R. Walter, and I. Price for support in the field; the technical staff at Massey University for processing the histopathology; and A. Heath and M. Minor for help in identifying the mites. Å. Berggren, D. Pence, and an anonymous referee commented on a previous draft of this paper. This research was supported by the New Zealand Lotteries Commission, J. S. Watson Conservation Trust, and the Supporters of Tiritiri Matangi Inc. All work was carried out under a research permit from the New Zealand Department of Conservation and had Massey University animal ethics approval.

LITERATURE CITED

- ALLEY, M. R., I. CASTRO, AND J. E. B. HUNTER. 1999. Aspergillosis in hihi (*Notiomystis cincta*) on Mokoia Island. *New Zealand Veterinary Journal* 47: 88–91.
- ARMSTRONG, D. P., AND J. G. EWEN. 2001. Testing for food limitation in reintroduced hihi populations: contrasting results for two islands. *Pacific Conservation Biology* 7: 87–92.
- BISHOP, D. M., AND A. C. G. HEATH. 1998. Special Issue: Parasites of birds in New Zealand—checklist of ectoparasites 25: 13–31.
- FOLSTAD, I., AND A. J. KARTER. 1992. Parasites, bright males, and the immunocompetence handicap. *American Naturalist* 139: 603–622.
- HIGGINS, P. J., J. M. PETER, AND W. K. STEELE. 2001. Stitchbird. In *Handbook of Australian, New Zealand and Antarctic Birds*, Vol. 5, P. J. Higgins, J. M. Peter and W. K. Steele (eds.). Oxford University Press, Melbourne, Victoria, Australia, pp. 954–966.
- LOW, M. 2005. Male force and female resistance: Context and patterns of copulation in the New Zealand stitchbird. *Journal of Avian Biology* 36: 436–448.
- . 2006. Sex, age and season influence morphometrics in the New Zealand stitchbird (hihi; *Notiomystis cincta*). *Emu* 106: 297–304.
- MADILL, D. 1987. Parasitic diseases. In *Everybird: A guide to bird health*, P. Macwhirter (ed.). Inkata Press, Melbourne, Victoria, Australia, pp. 45–59.
- RITCHIE, B. W., G. J. HARRISON, AND L. R. HARRISON. 1994. *Avian medicine: Principles and application*. Wingers, Fort Worth, Florida, 1394 pp.
- SCOTT, D. W., W. H. MILLER, AND C. E. GRIFFIN. 2001. *Muller and Kirk's small animal dermatology*, 6th Edition, W. B. Saunders Company, Ltd., Philadelphia, Pennsylvania, 1528 pp.
- SHOSHANA, R., AND B. URI. 1993. Knemidocoptes mites on feathers of the red fronted parakeet. In *Proceedings of the European Conference on Avian Medicine and Surgery*, Utrecht, The Netherlands. 3–6 March 1993, pp. 329–331.
- TAYLOR, S., I. CASTRO, AND R. GRIFFITHS. 2005. Hihi/stitchbird (*Notiomystis cincta*) recovery plan 2004–2009, New Zealand Department of Conservation, Wellington, New Zealand, 31 pp.
- WILSON, L. R. 1997. *The ecology and management of honeyeaters in Northern New Zealand*. M.Sc. Thesis, University of Auckland, New Zealand, 153 pp.

Received for publication 15 June 2004.