

## **Tubulopapillary Mammary Carcinoma in a Brown Bear (*Ursus arctos*)**

Authors: Nak, Deniz, Cangul, I. Taci, Nak, Yavuz, Cihan, Huseyin, and Celimli, Nureddin

Source: Journal of Wildlife Diseases, 44(2) : 505-508

Published By: Wildlife Disease Association

URL: <https://doi.org/10.7589/0090-3558-44.2.505>

---

BioOne Complete ([complete.BioOne.org](https://complete.BioOne.org)) is a full-text database of 200 subscribed and open-access titles in the biological, ecological, and environmental sciences published by nonprofit societies, associations, museums, institutions, and presses.

Your use of this PDF, the BioOne Complete website, and all posted and associated content indicates your acceptance of BioOne's Terms of Use, available at [www.bioone.org/terms-of-use](https://www.bioone.org/terms-of-use).

Usage of BioOne Complete content is strictly limited to personal, educational, and non - commercial use. Commercial inquiries or rights and permissions requests should be directed to the individual publisher as copyright holder.

---

BioOne sees sustainable scholarly publishing as an inherently collaborative enterprise connecting authors, nonprofit publishers, academic institutions, research libraries, and research funders in the common goal of maximizing access to critical research.

## Tubulopapillary Mammary Carcinoma in a Brown Bear (*Ursus arctos*)

Deniz Nak,<sup>1,5</sup> I. Taci Cangul,<sup>2</sup> Yavuz Nak,<sup>1</sup> Huseyin Cihan,<sup>3</sup> and Nureddin Celimli<sup>4</sup> <sup>1</sup> Department of Obstetrics and Gynecology, Faculty of Veterinary Medicine, University of Uludag, 16190 Bursa, Turkey; <sup>2</sup> Department of Pathology, Faculty of Veterinary Medicine, University of Uludag, 16190 Bursa, Turkey; <sup>3</sup> Department of Internal Medicine, Faculty of Veterinary Medicine, University of Uludag, 16190 Bursa, Turkey; <sup>4</sup> Department of Surgery, Faculty of Veterinary Medicine, University of Uludag, 16190 Bursa, Turkey; <sup>5</sup> Corresponding author (email: dnak@uludag.edu.tr)

**ABSTRACT:** A 28-yr-old, nulliparous female brown bear (*Ursus arctos*) at the Karacabey Ovakurusu Bear Sanctuary presented with an enlargement of the mammary gland. Three other nodules were also noted in the proximity of the mammary gland and over the vulva. Clinical, hematologic, ultrasonographic, and radiologic examinations were performed; the enlarged mammary gland was removed and the other masses were also excised. Histopathologic examination revealed tubulopapillary carcinoma of the mammary gland, and the other masses were diagnosed as epidermoid cysts. This is the first reported case of tubulopapillary mammary carcinoma accompanied by epidermoid cysts in a bear.

**Key words:** Brown bear, mammary tumor, tubulopapillary carcinoma, *Ursus arctos*.

There is limited information about naturally occurring tumors in wildlife. In Ursidae, only a few cases of neoplasms have been documented, including mandibular osteoma (Ozyigit et al., 2006); squamous cell carcinoma (Natalie et al., 2005); laryngeal squamous cell carcinoma (Rotstein et al., 2005); osteosarcomas in the maxilla (Momotani et al., 1988), fibula, and tibia (Ponomarev and Khutorianskii, 1995); and carcinomas of the bile ducts (Moulton, 1961; Gosselin and Kramer, 1984) and thyroid gland (Hellmann et al., 1991). To the best of our knowledge, there are no reports of mammary tumors in bears. However, in the order Carnivora (of which the bear is a member), mammary tumors are among the most commonly observed neoplasms (Argyle, 1998; Johnston et al., 2001). In cats, mammary tumors are mostly malignant (Moulton, 1990), while mammary tumors in dogs have a more favorable prognosis. In this

paper, we describe a case of tubulopapillary mammary carcinoma in a brown bear (*Ursus arctos*).

A 28-yr-old, nulliparous female brown bear at the Karacabey Ovakurusu Bear Sanctuary was referred with enlargement of the left mammary gland. The animal had been freely ranging in the sanctuary with 60 other bears and came in contact with humans only for feeding in areas where additional food was provided. The enlargement of the left mammary gland was noted by the care takers, and the responsible veterinarian was informed. A decision was made to perform a close examination of the animal as well as an operation, if indicated. The bear was immobilized with xylazine (2 mg/kg, Rompun Dry Substance®, Bayer, Istanbul, Turkey) and ketamine hydrochloride (7 mg/kg, Alfamine®, Alfasan International B.V., Woerden, the Netherlands) by dart using a blow pipe. In inspecting the animal, it was found that the left mammary gland was enlarged due to the formation of nodular structures within the gland. Three additional nodules (two in the caudal proximity of the mammary gland and one over the vulva) were also found (Fig. 1). The body temperature, respiration, and pulse rates were recorded, and the external palpable lymph nodes were examined. Blood samples were collected from the jugular vein and hematologic parameters were analyzed using an Abbott Cell-Dyn 3500 hematology analyzer (GMI Inc., Ramsey, Minnesota, USA). The abdomen was evaluated for the presence of any other masses via B-

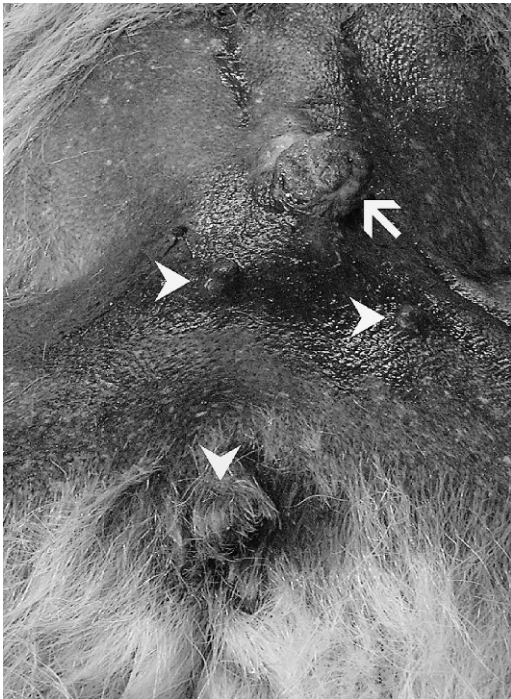


FIGURE 1. The enlarged mammary gland (arrow) and the nodular structures in close proximity to the mammary gland (arrowheads) and over the vulva (arrowhead).

mode and Directional Power (DirPwr) Doppler ultrasonography using an ultrasound scanner with a 5–10 MHz linear-array transducer (Terason Portable Ultrasonography System; Teratech Corporation, Burlington, Massachusetts, USA). Furthermore, all masses were also evaluated to assess the size, shape, echogenicity, tumor border definition, echopattern, and presence and distribution of vascular flow. Lateral and ventrodorsal radiographs of the thorax and abdomen were obtained. After all the examinations, a total mastectomy of the left mammary gland was performed, and the other masses were also excised. Macroscopically, the removed mammary gland was  $8.5 \times 6 \times 4$  cm in size, cream-white, and had lobular structure. A few cystic structures up to 2.5 cm diameter were observed on cut surface. The other masses were round- to oval-shaped and were between  $1.5 \times 1.5$  cm to  $2 \times 2.5$  cm in size. Their cut surfaces revealed well-

demarcated areas filled with cream-colored, friable content. All masses were fixed in formalin and processed routinely for histopathologic examination.

Mammary tumors are commonly observed in middle-aged to old, nulliparous dogs, and about half of the malignant tumors have metastasized by the time of presentation (Argyle, 1998; Johnston et al., 2001). The animal in our case was 28 yr old and had never given birth. All clinical examination parameters were within normal limits and no pathology was observed on palpation of the external lymph nodes. The erythrocyte count ( $7.64 \text{ m}/\mu\text{l}$ ), hemoglobin ( $16.4 \text{ g/dl}$ ), hematocrit (35.0%), mean corpuscular volume (MCV) ( $45.8 \text{ fl}$ ), mean corpuscular hemoglobin (MCH) ( $21.4 \text{ pg}$ ), mean corpuscular hemoglobin concentration (MCHC) ( $46.8 \text{ g/dl}$ ), and total leukocyte ( $7.04 \text{ k}/\mu\text{l}$ ) and platelet ( $446 \text{ k}/\mu\text{l}$ ) counts were also within normal limits (Kusak et al., 2005). However, many cancer patients have a mild normocytic, non-regenerative anemia associated with chronic disease, and infected mammary tumors may lead to increased neutrophil counts. Reduced platelet counts, bleeding tendencies, and an increase in blood clotting times should alert the clinician to the possibility of disseminated intravascular coagulation (Argyle, 1998).

Diagnostic imaging methods are an invaluable tool in the overall assessment and staging of a tumor patient. Thoracic and abdominal radiography should be performed to investigate any evidence of metastatic disease (Argyle, 1998). The most common sites of metastasis for all malignant mammary tumor types are the lungs and regional lymph nodes. Other reported sites of metastasis include the adrenal glands, kidney, heart, liver, bone, brain, eyes, nose, spleen, uterus, ovary, urethra, and skin (Argyle, 1998; Johnston et al., 2001). Abdominal ultrasonography can be very useful where transcoelomic spread is suspected from survey abdominal radiographs or for evaluating the abdominal viscera for metastatic deposits

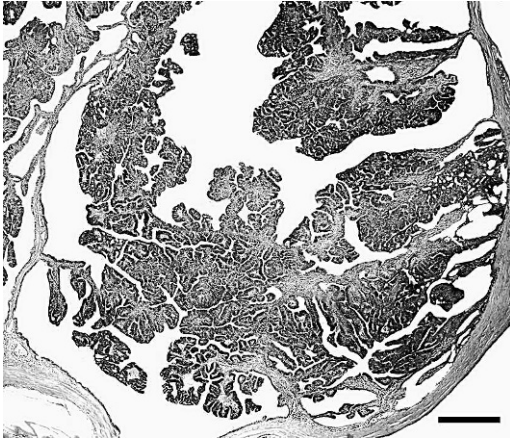


FIGURE 2. Enlarged tubules filled with coalescing multibranched papillae. H&E stain, Bar=500  $\mu$ m.

(Argyle, 1998). In our case, there were no specific pathologic findings related with metastasis, based on the thoracic and abdominal radiography. Ultrasonography of the abdomen did not reveal any pathologic structures in the abdominal organs. In our case, it was difficult to estimate how long ago the mass had formed because the animals were freely ranging and could only be occasionally observed.

In canine mammary tumors, ultrasonographic characteristics have been suggested to have a correlation with histopathologic changes. Ultrasonographic examination of the tissue composition and tumor vascularity, in particular, may have a value in presumptive diagnosis (Nyman et al., 2006). In our case, ultrasonography of the left mammary gland revealed an irregular shape, undefined borders, varying internal echopattern, and moderate, diffuse vascularity. The other masses had a regular shape, well-defined borders, homogenous hypoechoic internal echogenicity, and no internal vascularity.

Histopathologic examination revealed that the mass in the mammary gland was composed of enlarged tubules which were almost completely filled with coalescing multibranched papillae (Fig. 2). The epithelium lining the papillae consisted of cuboidal to columnar cells with large




FIGURE 3. Other nodules were filled with keratin flakes and diagnosed as epidermoid cysts. H&E stain, Bar=500  $\mu$ m.

round to ovoid hyperchromatic nuclei supported by moderate amounts of fibrous stroma. Mononuclear cell infiltration and minor hemorrhages accompanied by siderocyte accumulations were observed within the papillary stroma and among the tubules. Mitotic rate was moderate to high (2–3 per 400 $\times$  field) and bizarre mitotic figures were occasionally observed. In some areas, the tubules were distended and cystic areas had formed; the diagnosis of tubulopapillary carcinoma was made. The other nodules were keratin-filled cavities (Fig. 3) lined by squamous epithelium. Those lesions were well-circumscribed and clearly demarcated from the adjacent normal dermis; the diagnosis of epidermoid cysts was made (Hillyer et al., 2003; Rosai, 2004).

Cutaneous cysts are uncommon in animals and have generally been described as being epidermal or dermoid. Epidermoid cysts can be congenital and are thought to arise following entrapment and subsequent growth of primordial epithelial cells during closure of the neural tube or alternatively, traumatic sequestration of epidermal cells can lead to acquired cyst formation (Hillyer et al., 2003). Differential diagnoses for the masses included dermoid cysts, infundibular cysts, sarcoids, hypodermiasis, and collagenolytic granuloma.



Surgery is always recommended in cases of canine mammary neoplasia because it permits complete removal of localized tumors as well as the debulking of invasive tumors in order to optimize adjunctive therapies (Argyle, 1998; Johnston et al., 2001). In our case, during follow-up on the animal, no recurrences were observed 6 mo after the operation and the animal was in good health. To the best of our knowledge, this is the first report in a bear of a mammary carcinoma accompanied by epidermoid cysts.

#### LITERATURE CITED

- ARGYLE, D. J. 1998. The mammary gland. In BSAVA manual of small animal reproduction and neonatology, G. M. Simpson, G. C. W. England and M. Harvey (eds.). British Small Animal Veterinary Association, Cheltenham, UK, pp. 53–59.
- GOSSELIN, S. J., AND L. W. KRAMER. 1984. Extrahepatic biliary carcinoma in sloth bears. *Journal of the American Veterinary Medical Association* 185: 1314–1316.
- HELLMANN, J., R. HOFMEISTER, AND R. GOLTENBOTH. 1991. The occurrence of tumors in large bears (Ursidae): A literature review and six case descriptions. *Berliner und Münchener Tierärztliche Wochenschrift* 104: 262–268.
- HILLYER, L. L., A. P. JACKSON, G. C. QUINN, AND M. J. DAY. 2003. Epidermal (infundibular) and dermoid cysts in the dorsal midline of a three-year-old thoroughbred-cross gelding. *Veterinary Dermatology* 14: 205–209.
- JOHNSTON, S. D., M. V. ROOT KUSTRITZ, AND P. N. S. OLSON. 2001. *Canine and Feline Theriogenology*. WB Saunders Company, Philadelphia, Pennsylvania, 592 pp.
- KUSAK, J., R. B. RAFAJ, Z. ZVORCH, D. HUBER, J. FORSEK, L. BEDRICA, AND V. MRLJAK. 2005. Effects of sex, age, body mass, and capturing method on hematologic values of brown bears in Croatia. *Journal of Wildlife Diseases* 41: 843–847.
- MOMOTANI, E., H. AOKI, Y. ISHIKAWA, AND T. YOSHINO. 1988. Osteosarcoma in the maxilla of a brown bear (*Ursus arctos*). *Veterinary Pathology* 25: 527–529.
- MOULTON, J. E. 1961. Bile-duct carcinomas in two bears. *Cornell Veterinarian* 51: 285–293.
- (ed.). 1990. Tumors of the mammary gland. In *Tumors in domestic animals*, 3rd Edition. University of California Press, Berkeley California, pp. 518–552.
- NATALIE, D., M. S. MYLNICZENKO, A. L. MANHARTH, L. A. CLAYTON, R. FEINMEHL, AND M. ROBBINS. 2005. Successful treatment of mandibular squamous cell carcinoma in a Malayan sun bear (*Helarctos malayanus*). *Journal of Zoo and Wildlife Medicine* 36: 346–348.
- NYMAN, H. T., O. L. NIELSON, F. J. MCEVAY, M. H. LEE, T. MARTINUSSEN, E. HELMANN, AND A. T. KRISTENSE. 2006. Comparison of B-mode and Doppler ultrasonographic findings with histologic features of benign and malignant mammary tumors in dogs. *American Journal of Veterinary Research* 67: 985–991.
- OZYIGIT, M. O., N. AYTUG, AND H. CIHAN. 2006. Mandibular osteoma in a brown bear (*Ursus arctos*). In *Proceedings of the 6th scientific meeting of the European Association of Zoo- and Wildlife Veterinarians (EAZWV)*, May 24–28, 2006. Budapest, Hungary, pp. 91–93.
- PONOMARKOV, V. I., AND A. A. KHUTORIANSKII. 1995. A case of osteosarcoma in a white polar bear. *Arkiv Patologii* 57: 81–83.
- ROSAI, J. 2004. Skin. In *Rosai and Ackerman's surgical pathology*, 9th Edition, J. Rosai (ed.). Mosby, New York, pp. 93–245.
- ROTSTEIN, D. S., P. GAVETT, AND B. WOLFE. 2005. Laryngeal squamous cell carcinoma in a North American black bear (*Ursus americanus*). *Journal of Zoo and Wildlife Medicine* 36: 543–545.

*Received for publication 10 January 2007.*