

## **RANAVIRUS INFECTION OF FREE-RANGING AND CAPTIVE BOX TURTLES AND TORTOISES IN THE UNITED STATES**

Authors: Johnson, April J., Pessier, Allan P., Wellehan, James F. X., Childress, April, Norton, Terry M., et al.

Source: Journal of Wildlife Diseases, 44(4) : 851-863

Published By: Wildlife Disease Association

URL: <https://doi.org/10.7589/0090-3558-44.4.851>

---

The BioOne Digital Library (<https://bioone.org/>) provides worldwide distribution for more than 580 journals and eBooks from BioOne's community of over 150 nonprofit societies, research institutions, and university presses in the biological, ecological, and environmental sciences. The BioOne Digital Library encompasses the flagship aggregation BioOne Complete (<https://bioone.org/subscribe>), the BioOne Complete Archive (<https://bioone.org/archive>), and the BioOne eBooks program offerings ESA eBook Collection (<https://bioone.org/esa-ebooks>) and CSIRO Publishing BioSelect Collection (<https://bioone.org/csiro-ebooks>).

Your use of this PDF, the BioOne Digital Library, and all posted and associated content indicates your acceptance of BioOne's Terms of Use, available at [www.bioone.org/terms-of-use](http://www.bioone.org/terms-of-use).

Usage of BioOne Digital Library content is strictly limited to personal, educational, and non-commercial use. Commercial inquiries or rights and permissions requests should be directed to the individual publisher as copyright holder.

---

BioOne is an innovative nonprofit that sees sustainable scholarly publishing as an inherently collaborative enterprise connecting authors, nonprofit publishers, academic institutions, research libraries, and research funders in the common goal of maximizing access to critical research.

# RANAVIRUS INFECTION OF FREE-RANGING AND CAPTIVE BOX TURTLES AND TORTOISES IN THE UNITED STATES

April J. Johnson,<sup>1</sup> Allan P. Pessier,<sup>2</sup> James F. X. Wellehan,<sup>1</sup> April Childress,<sup>1</sup> Terry M. Norton,<sup>3,11</sup> Nancy L. Stedman,<sup>4,12</sup> David C. Bloom,<sup>5</sup> William Belzer,<sup>6</sup> Valorie R. Titus,<sup>7,8</sup> Robert Wagner,<sup>9</sup> Jason W. Brooks,<sup>10</sup> Jeffrey Spratt,<sup>3,13</sup> and Elliott R. Jacobson<sup>1,14</sup>

<sup>1</sup> Department of Small Animal Clinical Sciences, College of Veterinary Medicine, University of Florida, Gainesville, Florida 32610, USA

<sup>2</sup> Division of Pathology, Conservation and Research for Endangered Species, Zoological Society of San Diego, San Diego, California 92112-0551, USA

<sup>3</sup> Wildlife Conservation Society, St. Catherines Island Wildlife Survival Center, 182 Camellia Road, Midway, Georgia 31320, USA

<sup>4</sup> Athens Diagnostic Laboratory, College of Veterinary Medicine, University of Georgia, Athens, Georgia 30602, USA

<sup>5</sup> Department of Molecular Genetics and Microbiology, College of Medicine, University of Florida, Gainesville, Florida 32610-0266, USA

<sup>6</sup> Box Turtle Conservation Trust, 304 E Bassell Avenue, Oil City, Pennsylvania 16301, USA

<sup>7</sup> Department of Biological Sciences, Binghamton University, Binghamton, New York 13902-6000, USA

<sup>8</sup> Brookhaven National Laboratory, Upton, New York 11973, USA

<sup>9</sup> Division of Laboratory Animal Resources, School of Medicine, University of Pittsburgh, Pittsburgh, Pennsylvania 15261, USA

<sup>10</sup> Animal Diagnostic Laboratory, College of Agricultural Sciences, Orchard Road, The Pennsylvania State University, University Park, Pennsylvania 16802-1110, USA

<sup>11</sup> Current address: St. Catherines Island Foundation, 182 Camellia Road, Midway, Georgia 31320, USA; and Georgia Sea Turtle Center, 214 Stable Road, Jekyll Island, Georgia 31527, USA

<sup>12</sup> Current address: Wyeth Research, 1 Burtt Road, Andover, Massachusetts 01810, USA

<sup>13</sup> Current address: The Nature Conservancy, Southeast Georgia Field Office, PO Box 484, Darien, Georgia 31305, USA

<sup>14</sup> Corresponding author (email: JacobsonE@mail.vetmed.ufl.edu)

**ABSTRACT:** Iridoviruses of the genus *Ranavirus* are well known for causing mass mortality events of fish and amphibians with sporadic reports of infection in reptiles. This article describes five instances of *Ranavirus* infection in chelonians between 2003 and 2005 in Georgia, Florida, New York, and Pennsylvania, USA. Affected species included captive Burmese star tortoises (*Geochelone platynota*), a free-ranging gopher tortoise (*Gopherus polyphemus*), free-ranging eastern box turtles (*Terrapene carolina carolina*), and a Florida box turtle (*Terrepenne carolina bauri*). Evidence for *Ranavirus* infection was also found in archived material from previously unexplained mass mortality events of eastern box turtles from Georgia in 1991 and from Texas in 1998. Consistent lesions in affected animals included necrotizing stomatitis and/or esophagitis, fibrinous and necrotizing splenitis, and multicentric fibrinoid vasculitis. Intracytoplasmic inclusion bodies were rarely observed in affected tissues. A portion of the major capsid protein (MCP) gene was sequenced from each case in 2003–2005 and found to be identical to each other and to *Frog virus 3* (FV3) across 420 base pairs. *Ranavirus* infections were also documented in sympatric species of amphibians at two locations with infected chelonians. The fragment profiles of *HindIII*-digested whole genomic DNA of *Ranavirus*, isolated from a dead Burmese star tortoise and a southern leopard frog (*Rana utricularia*) found nearby, were similar. The box turtle isolate had a low molecular weight fragment that was not seen in the digestion profiles for the other isolates. These results suggest that certain amphibians and chelonians are infected with a similar virus and that different viruses exist among different chelonians. Amphibians may serve as a reservoir host for susceptible chelonians. This report also demonstrated that significant disease associated with *Ranavirus* infections are likely more widespread in chelonians than previously suspected.

**Key words:** FV3, iridovirus, *Ranavirus*, reptiles, tortoises, turtles.

## INTRODUCTION

It has been suggested that chelonian (turtles and tortoises) populations face a more serious threat than that posed by the well-publicized decline of amphibian

populations (Klemens, 2000). Two thirds of all species of freshwater turtles and tortoises are currently listed as threatened on the International Union for Conservation of Nature (IUCN) Red List of Threatened Species (Turtle Conservation Fund, 2002).

Chelonians have low fecundity, low juvenile survival rates, and long adult life spans, a life-history strategy in which loss of adult animals (such as loss by disease) has a significant impact on population recovery (Heppell, 1998). Emerging infectious diseases have been increasingly recognized as factors influencing wildlife health and populations (Harvell et al., 1999; Daszak et al., 2000). Although mycoplasmosis has been postulated to contribute to declines of some tortoise species (USFWS, 1994), the cause(s) of mass mortality events in wild chelonian populations often remains undetermined (Flanagan, 2000; Dodd, 2001).

Among the emerging diseases of wildlife, iridoviruses, in the genus *Ranavirus*, are well known for causing mass mortality events of fish and amphibians (Langdon and Humphrey, 1987; Daszak et al., 1999; Green et al., 2002). Iridovirus infections have also been sporadically described in reptiles, including snakes (Hyatt et al., 2002), lizards (Marshall et al., 2005) and chelonians. In chelonians, iridovirus infections have been reported in captive Hermann's tortoises (*Testudo hermanni*; Heldstab et al., 1982; Muller et al., 1988; Marschang et al., 1999), farmed soft-shelled turtles (Chen et al., 1999) and captive eastern box turtles (*Terrapene carolina carolina*; De Voe et al., 2004). Two ranaviruses identified in an exotic tortoise (*Testudo horsfieldii*) and a box turtle in the United States were found to be closely related to frog virus 3 (FV3) and designated as tortoise virus 5 (TV5) and turtle virus 3 (TV3), respectively (Mao et al., 1997). The only reports of iridovirus infections in free-ranging chelonians involved a gopher tortoise (*Gopher polyphemus*) in Florida, USA (Westhouse et al., 1996), and a box turtle in Tennessee, USA (Allender et al., 2006), with signs of respiratory disease.

This report identifies *Ranavirus* infections in five recent chelonian deaths or mortality events from Georgia, Florida, New York, and Pennsylvania, USA, and in archived material recovered from previ-

ously unexplained mass mortality events in 1991 from Georgia, USA, and in 1998 from Texas, USA. This demonstrates a previously undescribed geographic extent of chelonian *Ranavirus* infections and suggests that ranaviruses may be more important pathogens of free-ranging chelonians than anticipated from previous reports. We also present molecular evidence for an identical or similar virus in frogs in the vicinity of one of the chelonian epizootics, suggesting that amphibians could serve as reservoir hosts for chelonians.

## MATERIALS AND METHODS

### Animals

**Burmese star tortoises:** Three female and two male captive Burmese star tortoises (*Geochelone platynota*) were kept in an outdoor enclosure at St Catherine's Island Wildlife Survival Center, Georgia (31°40'N, 81°10'W) since April 2001. In early June 2003, two female and one male tortoise began showing clinical signs, consisting of nasal discharge, conjunctivitis, and severe subcutaneous edema of the neck (Fig. 1A). The tortoises were treated with antimicrobials and were soaked daily for 90 min in warm water.

One female tortoise died 3 days after developing clinical signs, and yellow-white caseous plaques were observed on the tongue at necropsy. Oral antiviral therapy and intracoelomic fluids were then initiated in the surviving tortoises. Subsequently, six adult southern leopard frogs (*Rana utricularia*) were collected from within the tortoise pens and one was collected from a pond nearby. One of the frogs from the pen was found moribund, whereas others appeared healthy. All frogs were euthanatized with a concentrated solution of methane tricaine sulfonate (MS-222) followed by decapitation. Tissues (see below) from the dead tortoise and the leopard frogs were submitted for histopathology, virus isolation, and polymerase chain reaction (PCR) for determining presence of certain DNA sequences of *Ranavirus* and *Herpesvirus*.

**Gopher tortoise:** A wild gopher tortoise (*Gopherus polyphemus*) was found circling on a road in north-central Florida (29°86'N, 82°22'W) on 25 July 2003 and brought to the University of Florida, College of Veterinary Medicine Zoological Medicine Service, for

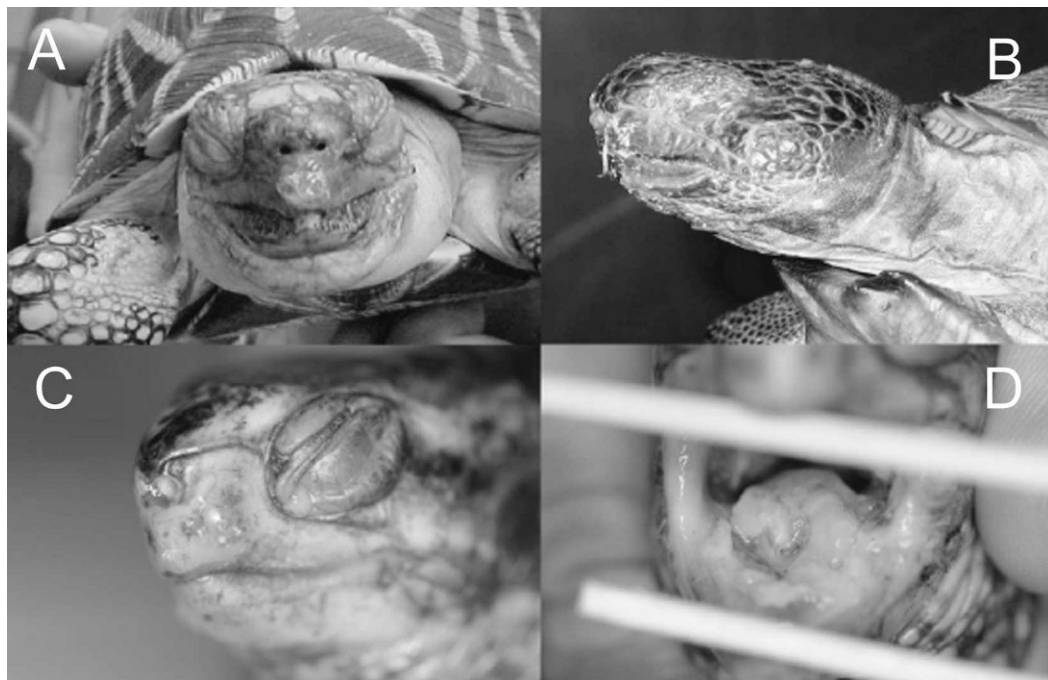


FIGURE 1. Gross lesions associated with iridovirus infections in turtles and tortoises. (A) Photograph of the Burmese star tortoise with nasal discharge and palpebral and cervical edema. (B) Photograph of the wild Gopher tortoise with nasal discharge and palpebral edema. (C) Photograph of the wild Florida box turtle with palpebral edema and ocular discharge. (D) Photograph of caseous plaques in the oral cavity of a box turtle.

evaluation and treatment. On presentation it exhibited palpebral swelling and ocular and nasal discharge (Fig. 1B). The tortoise was treated with intracoelomic fluid twice daily; was allowed to soak in shallow, warm water for 20 min a day; and was started on antimicrobial therapy. The tortoise's condition continued to decline, and it was euthanized with intravenous Beuthanasia-D solution (Schering-Plough Animal Health Corp., Kenilworth, New Jersey, USA) on 29 July 2003. A complete necropsy was performed, and tissues were submitted for histopathology, PCR, and virus isolation.

**Eastern box turtles:** A 200-ha, gated and fenced area within a private nature sanctuary in Venango County, Pennsylvania, (41°43'N, 79°93'W) was created as a study site for relocated box turtles. All box turtles within the study site were radiotelemetered and tracked regularly, and no box turtles were present at the site before the release of the relocated turtles. During the summer of 2003, there were 32 adult and 34 head-started juvenile turtles. Turtles were observed every 5 days to determine their health status and location. From 15 August to 20 November 2003, 15

(23%) of the 66 turtles died. Box turtles had lived in this sanctuary without signs of illness for 4 yr preceding this epizootic. Many of the turtles were considered healthy approximately 4 to 8 days before being found either moribund or dead. Nine of the turtles were found dead, whereas six were found moribund with palpebral edema, ocular discharge, and fluid draining from the mouth. Moribund turtles were taken out of the preserve, treated with an ophthalmic ointment in the eyes, soaked daily in warm water, and given a temperature gradient. Two turtles were started on antimicrobials and one of the two also received a parasiticide. All moribund turtles died within hours to days after being found exhibiting signs of illness. In May 2004, three freshly dead green frog tadpoles (*Rana clamitans*) with marked cutaneous erythema were collected from a pond at the nature preserve. Tissues from five turtles collected in 2003 and from the tadpoles collected in 2004 were submitted for histopathology, PCR, and virus isolation.

Two wild box turtles were found moribund with ocular discharge and swelling, as well as aural abscesses and yellow caseous plaques in the oral cavity in Suffolk County, New York,



USA (40°51'N, 72°52'W) on 2 August 2005. They were observed near the edge of a drying pond that is used by many pond-breeding amphibians, including green frogs (*Rana clamitans*) and bullfrogs (*Rana catesbeiana*). These animals were taken to a local wildlife rehabilitator, where one died overnight. The carcass was then put in a freezer for later evaluation. The other had the aural abscesses drained and was treated with antimicrobials, but its health continued to decline until its death on 1 September 2005. This turtle was put on ice and, along with the frozen specimen, sent to the University of Florida for histopathology, PCR, and virus isolation.

**Florida box turtle:** A wild Florida box turtle (*Terrepenne carolina bauri*), found in north central Florida (29°42'N, 82°23'W) in October 2004, was submitted to the Zoological Medicine Service, College of Veterinary Medicine, University of Florida, for treatment. The box turtle exhibited palpebral edema, nasal and ocular discharge (Fig. 1C), and had yellow-white caseous plaques in the oral cavity (Fig. 1D). The turtle was administered fluid intracoelomically with B vitamins daily and was started on analgesics to alleviate pain. Because of failure to respond to therapy and a poor prognosis, the turtle was euthanized 3 days after admission with intravenous Beuthanasia-D solution. A complete necropsy was performed and tissues submitted for histopathology, PCR, and virus isolation.

**Past mortality events:** Tissues from two previous box turtle epizootics of undetermined etiology were examined. In July and August 1991, more than 30 eastern box turtles were found dead in, or near, water sources in Murray county (34°45'N, 84°47'W), northwest Georgia, USA (Dodd, 2001). Two moribund turtles were found exhibiting lethargy and had ocular discharge and caseous white plaques in the oral cavity. One turtle also had a subcutaneous abscess caudal to the left eye. Both turtles were submitted for necropsy. In 1998, several eastern box turtles and other unspecified turtle species died suddenly in a private collection in Texas, USA (Dodd, 2001). Archived paraffin blocks for histologic examination were obtained from two box turtles from the Georgia, USA, and one box turtle from Texas, USA, die off and were re-evaluated using light and transmission electron microscopy.

### Necropsy and histopathology

At necropsy, tissues were collected from all major organ systems of the following tortoises, turtles, and amphibians: Burmese star tortoise

(*n*=1), gopher tortoise (*n*=1), eastern box turtles (Pennsylvania [*n*=5], Georgia [*n*=2], New York [*n*=1], and Texas [*n*=1], USA), Florida box turtle (*n*=1), southern leopard frog (*n*=7), and green frog tadpoles (*n*=3). Tissues were fixed in neutral-buffered 10% formalin, dehydrated in graded alcohols, embedded in paraffin, sectioned at 6  $\mu$ m, and stained with hematoxylin and eosin. Tongue, liver, and spleen of each chelonian were collected and frozen at -80 C for detecting DNA sequences of *Ranavirus* and *Herpesvirus* using PCR and virus isolation. Tongue, liver, and spleen of each amphibian were likewise collected and frozen at -80 C for subsequent detection of DNA sequences of *Ranavirus* using PCR and virus isolation.

### Nucleotide amplification, sequencing, and sequence analysis

DNA was extracted from chelonian and amphibian tissues, and cells were cultured for virus isolation using the DNeasy kit (Qiagen, Valencia, California, USA). Five 5- $\mu$ m-thick, paraffin-embedded sections from box turtles from the 1991 and 1998 mortality events were extracted using the DNeasy kit, following the protocol for paraffin-embedded tissue. Sense primer (5'-GACTTGGCCACTTATGAC-3') and antisense primer (5'-GTCTCTGGAGAA-GAAGAA-3'), as previously described (Mao et al., 1997), were used to amplify approximately 500 base pairs in the N terminus portion of the *Ranavirus* major capsid protein (MCP) gene. A 50- $\mu$ l reaction mixture was run, which contained 4 ml extracted DNA; 1  $\mu$ M of each primer; 200  $\mu$ M each of dATP, dCTP, dGTP, and dTTP; and 2.5 U of *Taq* DNA polymerase and PCR buffer containing 50 mM KCl, 10 mM Tris-HCl, and 1.5 mM MgCl<sub>2</sub> (Eppendorf, Westbury, New York, USA). The mixtures were amplified in a thermal cycler (PCR Sprint, Thermo Hybaid, Ashford, Middlesex, UK) with an initial denaturation at 94 C for 2.5 min, followed by 25 cycles of denaturation at 94 C for 30 sec.; annealing at 50 C for 30 sec; extension at 72 C for 30 sec., and a final extension step at 72 C for 10 min, as previously described (Marschang et al., 1999). The same extracted DNA from the chelonian tissues was evaluated by PCR for the presence of chelonian herpesvirus(es). A nested consensus PCR was performed, as previously described, to detect a portion of the herpesvirus DNA dependent DNA polymerase (VanDevanter et al., 1996).

Any PCR products were resolved in 1% agarose gels, and bands were excised and purified using the QIAquick gel extraction kit

(Qiagen). Products were sequenced in both directions directly using the Big-Dye Terminator Kit (Perkin-Elmer, Branchburg, New Jersey) and analyzed on ABI 377 automated DNA sequencers at the University of Florida's Sequencing Center.

### Virus isolation

Turtle heart cells (TH-1; American Type Cell Culture [ATCC], Manassas, Virginia, USA) were seeded into 25-cm<sup>2</sup> flasks (Costar, Corning, New York, USA). Cells were cultured in Dulbecco's Modified Eagle Medium (DMEM, Gibco, Carlsbad, California, USA), supplemented with 5% fetal bovine serum (Gibco), gentamicin (60 mg/l; Sigma, St. Louis, Missouri, USA), penicillin G (120,000 U/l), streptomycin (120,000 U/l), and amphotericin B (300 µg/l) (Sigma), and cultured to confluency. A small piece of spleen or liver from each case was homogenized in separate 5-ml tissue grinders containing DMEM. Part of each homogenate was applied to a flask of confluent monolayer of TH-1 cells, whereas the other was passed through a 0.45-µm filter (Costar) onto another flask of cells. Cells were incubated at 28 C. Flasks were observed daily for cytopathic effect (CPE).

### Transmission electron microscopy

Second-passage TH-1 cell monolayers (75-mm<sup>2</sup> flasks), inoculated with first-passage isolates from homogenates of kidney tissue collected at necropsy from the Burmese star tortoise and the gopher tortoise, were examined by transmission electron microscopy (TEM). Cells were harvested 3 days after inoculation (2 days after observation of CPE) and centrifuged at 4,500 × G for 10 min. Supernatant was discarded, and the remaining pellet was suspended in Trump's fixative (4% paraformaldehyde, 1% glutaraldehyde). Cells were postfixed in osmium tetroxide, dehydrated in graded alcohols, and embedded in Spurr's resin. Ultrathin sections were stained with uranyl acetate and lead citrate and were viewed using a Hitachi H7000 transmission electron microscope at the University of Florida Electron Microscopy Laboratory.

Paraffin-embedded spleen from a box turtle from the 1991 mass mortality event in Georgia, USA, and paraffin-embedded trachea from a box turtle from Texas, USA, from the 1998 mass mortality event were deparaffinized in xylene, embedded in Spurr's resin, sectioned for TEM, and examined as described for cell culture.

Skin from the necropsied Burmese star tortoise was placed in Trump's solution

(McDowell and Trump, 1976) and submitted to the Athens Diagnostic Laboratory, University of Georgia for TEM. Tissue was postfixed in osmium tetroxide, dehydrated in graded alcohols, and embedded in epoxy. Ultrathin sections were stained with uranyl acetate and lead citrate and examined with a JEOL JSM-1210 transmission electron microscope.

### Restriction enzyme analysis

Frog virus 3 was obtained from ATCC and served as the positive control for comparative purposes with the viruses isolated in this study. Frog virus 3 and second-passage isolates of tissue homogenates from the Burmese star tortoise and southern leopard frog that were collected at the same site, and a box turtle isolated from the Pennsylvania mortality event, were inoculated onto TH-1 cells. Once CPE was observed, viral DNA was radiolabeled with [methyl-<sup>3</sup>H] thymidine, extracted, and digested with the endonuclease *Hind*III, as previously described (Mao et al., 1999). Restricted DNA fragments were separated on a 0.7% agarose gel, after which, the gel was impregnated with Enhance (Perkin Elmer, Wellesley, Massachusetts, USA) according to the manufacturer's directions, and the radiolabeled fragments were detected by fluorography.

## RESULTS

Findings are summarized in Table 1 and were similar in the Burmese star tortoise, gopher tortoise, and box turtles that were examined. The most commonly observed lesions were necrotizing and ulcerative stomatitis or esophagitis, fibrinous and necrotizing splenitis, and multicentric fibrinoid vasculitis. Lesions in the oral cavity and esophagus were characterized by near-diffuse mucosal erosion and ulceration with surfaces covered by a thick coagulum comprised of fibrin, degenerate heterophils, sloughed epithelial cells, and bacterial colonies (Fig. 2). Lesions in the spleen consisted of disruption of the white pulp, and to a lesser degree, the surrounding red pulp, by deposits of fibrin admixed with karyorrhectic debris and by infiltrations of small numbers of heterophils (Fig. 3). There was frequently mild to marked red pulp congestion and/or hemorrhage. Fibrinoid vasculitis with thrombosis was observed in

TABLE 1. Pathologic, virologic, and polymerase chain reaction (PCR) findings in tortoises and box turtles infected with *Ranavirus*.<sup>a</sup>

Species, state, year	Histologic lesions	Inclusion bodies observed	PCR for <i>Ranavirus</i> MCP gene sequences	Virus isolation	Electron microscopy of tissues
Burmese star tortoise, Georgia, USA, 2003	S, E, Spl, H, G, C, K, V	Yes (endothelial cells, tongue and hematopoietic cells)	Positive	Positive	Positive
Gopher tortoise, Florida, USA, 2003	S, Spl, H, C, K, V	Yes (hematopoietic cells)	Positive	Positive	NP
Box turtle, Pennsylvania, USA, 2003	S, E, Spl, G, T, V	Yes (endothelial, esophagus, stomach, trachea)	Positive	Positive	NP
Box turtle, Pennsylvania, USA, 2003	E, Spl, V, H	No	Positive	Positive	NP
Box turtle, Pennsylvania, USA, 2003	E, Spl, V, H	No	Positive	Positive	NP
Box turtle, Florida, USA, 2004	S, Spl	No	Positive	Positive	NP
Box turtle, New York, USA, 2005	S, Spl, G, T, K, V	Yes (tongue, stomach)	Positive	Positive	NP
Box turtle, Texas, USA, 1998	Spl, T, H	Yes (trachea)	NP	NP	Positive
Box turtles, Georgia, USA, 1991	Spl	Yes (spleen)	NP	NP	Positive

<sup>a</sup> MCP = major capsid protein; S = stomatitis; E = esophagitis; Spl = splenitis; H = hematopoietic tissue necrosis; G = gastritis; C = conjunctivitis; K = glomerulonephritis; T = tracheitis; V = vasculitis; NP = not performed.

splenic-sheathed capillaries (ellipsoids) in all animals and, to varying degrees, in other locations, including oral mucosa, esophagus, stomach, intestine, skin, lung, heart, and liver. Several animals had mild to moderate degrees of necrosis of hematopoietic tissue in the kidney, liver, and bone marrow. Multifocal necrotizing tracheitis, gastritis, or glomerulonephritis were observed in three animals, whereas conjunctivitis was observed in two. In five of nine cases examined histologically, rare basophilic intracytoplasmic inclusion bodies suggestive of iridovirus infection were observed within epithelial cells of the oral mucosa, esophagus, stomach and trachea, and/or within

endothelial cells, macrophages (Fig. 4), and hematopoietic progenitor cells.

Necrosis of hepatic and renal hematopoietic tissues with rare basophilic intracytoplasmic inclusion bodies consistent with iridovirus infection was observed in the moribund southern leopard frog from the Burmese star tortoise pen in Georgia, USA, and in one green frog tadpole from the site in Pennsylvania, USA.

**PCR and sequence analysis**

PCR for the *Ranavirus* MCP gene yielded DNA fragments approximately 420 base pairs in length. After sequencing of the fragments, and exclusion of the primer, the

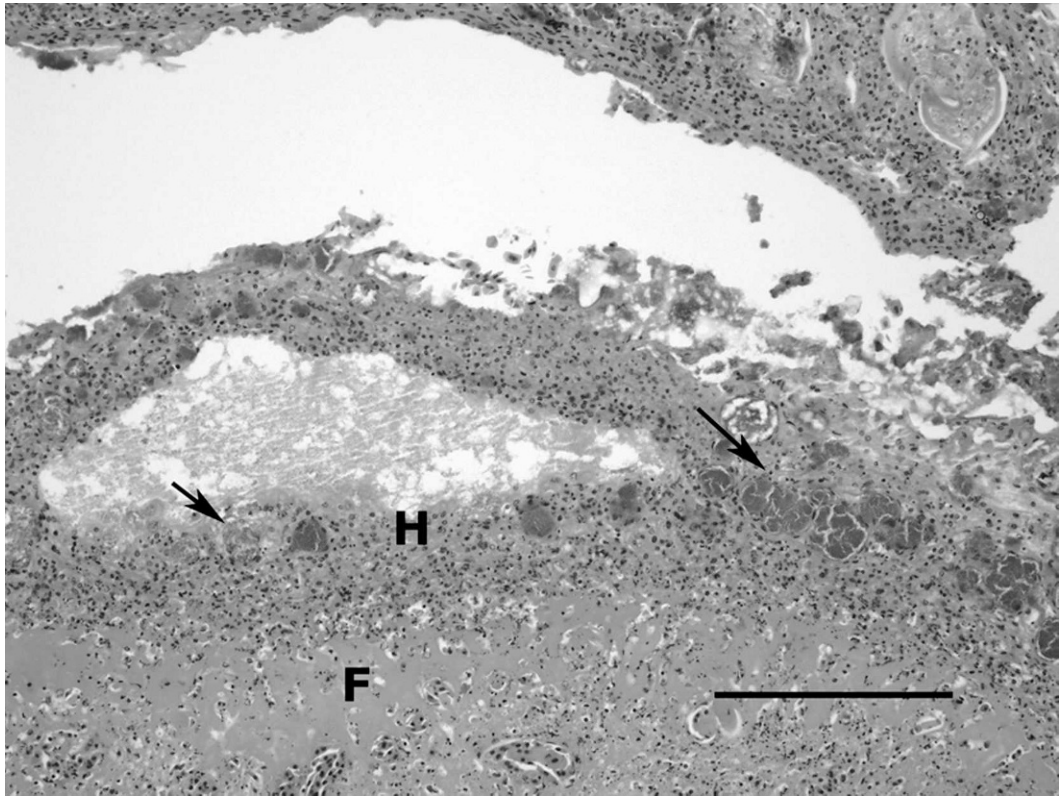


FIGURE 2. Esophagus, eastern box turtle. There is diffuse necrosis and ulceration of the mucosa and replacement by fibrin (F), infiltrations of heterophils (H), and superficial bacterial colonies (arrows). H&E stain. Bar=200  $\mu$ m.

sequences of the gopher tortoise, star tortoise, all box turtles, southern leopard frog, and green frog were all identical. The sequences were compared with known sequences in GenBank (National Center for Biotechnology Information [NCBI], Bethesda, Maryland, USA), European Molecular Biology Laboratory Nucleotide Sequence Database (EMBL-Bank; Cambridge, UK), and Data Bank of Japan (Mishima, Shizouka, Japan) databases using TBLASTX (NCBI; Altschul et al., 1997). The TBLASTX results for the sequences all showed the highest score with FV3 capsid protein gene (GenBank accession AF157769). Polymerase chain reaction of DNA extracted from paraffin-embedded sections of tissue from box turtles from the 1991 and 1998 die offs were negative. All tortoises and box turtle samples were

negative by PCR for the presence of herpesvirus.

#### Virus isolation

All TH-1 cells infected with tissue homogenates from the dead turtles and tortoises had cytopathic effects (CPE) that consisted of cell rounding and lysis 2 to 3 days postinoculation. Flasks that contained both filtered tissue homogenate as well as unfiltered tissue homogenate showed CPE. The Burmese star tortoise isolate was also passaged onto fathead minnow cells (ATCC), which subsequently exhibited similar CPE.

#### Transmission electron microscopy

Using TEM, the cell cultures infected with tissue homogenates from the Burmese



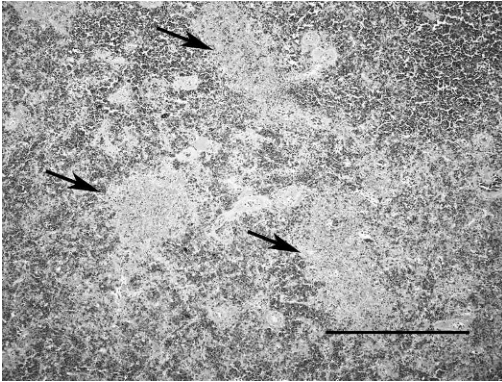


FIGURE 3. Spleen, eastern box turtle. There is disruption of the white and red pulp with deposits of fibrin (arrow) admixed with karyorrhectic debris, and infiltrations of small numbers of heterophils. H&E stain. Bar=500  $\mu$ m.

star and gopher tortoises showed large numbers of icosahedral shaped viral particles that were consistent in size (approximately 130 nm) and shape with an iridovirus (Fig. 5). Similar viral particles were observed within intracytoplasmic inclusion bodies in endothelial cells and macrophages of the skin in the Burmese star tortoise, within the cytoplasm of unidentified cells in the spleen of a 1991 box turtle from Georgia, USA, and within intracytoplasmic inclusion bodies of degenerate respiratory epithelial cells of the

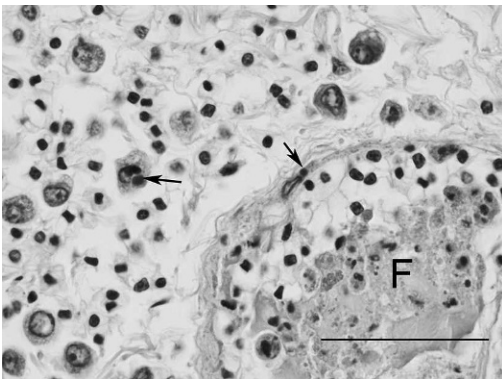


FIGURE 4. Epicardium, Burmese star tortoise. Arrows depict basophilic intracytoplasmic inclusion bodies in a macrophage and endothelial cell. The lumen of the blood vessel contains a fibrin thrombus (F). H&E stain. Bar=50  $\mu$ m.

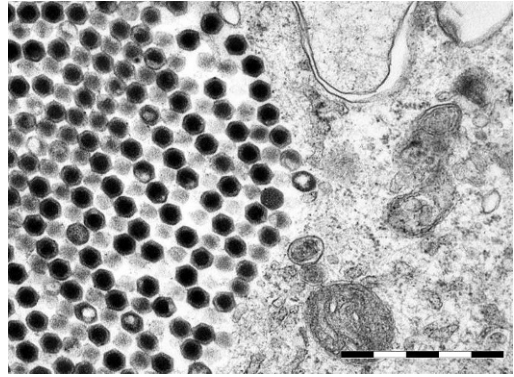


FIGURE 5. Transmission electron micrograph (TEM) of *Terrapene* heart cells inoculated with liver tissue from the Burmese star tortoise demonstrating cytoplasmic arrays of iridovirus-like particles. Uranyl acetate and lead citrate stain. Bar=1  $\mu$ m.

trachea in the 1998 box turtle from Texas, USA (Fig. 6).

#### Restriction enzyme analysis

Whole viral genomic endonuclease restriction using *Hind*III demonstrated identical restriction patterns between the Burmese star tortoise isolate and southern leopard frog isolate. Both had identical profiles to FV3 (Fig. 7). Compared with the other isolates, the box turtle isolate from the Pennsylvania, USA, site had a slightly different pattern. It had a similar restriction

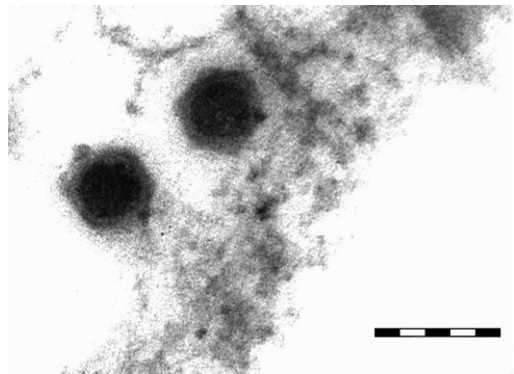


FIGURE 6. Transmission electron micrograph (TEM) of paraffin embedded spleen from a box turtle that died in 1991 in Georgia, USA. There are icosahedral virus particles compatible with an iridovirus. Bar=200 nm.

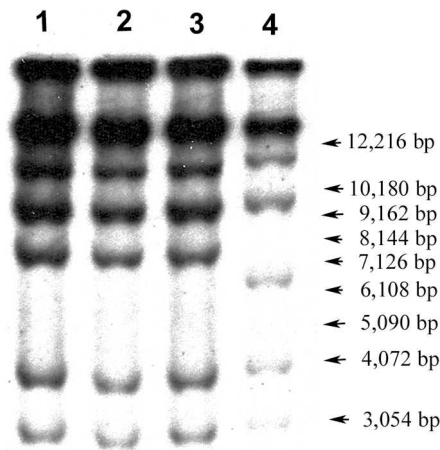


FIGURE 7. *Ranavirus* DNA radiolabeled with [methyl- $^3\text{H}$ ] thymidine and digested with the endonuclease *Hind*III. Lanes 1, 2, 3, and 4 represent *Ranavirus* DNA fragments from Frog virus 3, Burmese star tortoise, Southern leopard frog, and box turtle respectively. Sizes (in Kb) of the fragments are shown to the right.

pattern to TV3 and TV5, as previously described by Mao et al. (1997) for isolates from a box turtle and Russian tortoise, respectively.

## DISCUSSION

Emerging infectious diseases are those that have newly appeared in a population or have previously existed but are rapidly increasing in incidence or geographic range (Morse, 1995). The findings reported here suggest that iridovirus infections in chelonians fill this description, and are emerging pathogens of chelonians. Infections are being discovered in new populations of turtles, and the incidence is either increasing, or our ability to detect the disease in these animals is increasing. Infections in chelonians are more geographically widespread than has been previously documented. Previous reports from the United States had identified chelonian iridovirus infections in a wild gopher tortoise in Florida, USA (Westhouse et al., 1996), captive box turtles in North Carolina, USA (De Voe et al., 2004), one free-ranging box turtle in

Tennessee, USA (Allender et al., 2006), and in two chelonians, where the location was not reported (Mao et al., 1997). Here, we have identified more infections within a 2 yr period in Georgia, Florida, Pennsylvania, and New York, USA, than previously described, indicating either an increase in the incidence of disease and/or the detection the infection. Identification of iridovirus-like particles in the mortality event in 1998 expands the new geographic range further to include Texas, USA. We also have described infection in a Burmese star tortoise, a species that has previously not been documented to be susceptible to iridovirus infections.

Reports of mortality events involving large numbers of box turtles and gopher tortoises have been documented in which etiologies were never definitively identified (Dodd, 2001; Rossell et al., 2002; Seigel et al., 1996). This report demonstrates, by re-evaluation of archived samples, that at least some turtles in these mortality events (Dodd, 2001) have been infected with a virus(es) compatible with iridovirus and mortalities may have been caused by infection with these viruses. Polymerase chain reaction results from these cases were negative; however, it is unknown how long tissues had been fixed in formalin before being embedded into paraffin. Formalin fixation has been shown to degrade DNA and could result in false-negative results (Tokuda et al., 1990). Still, TEM of the same tissues showed virus particles consistent in size and shape with iridovirus.

The histologic lesions in the chelonians in this report were relatively nonspecific; intracytoplasmic basophilic inclusion bodies that could be suggestive of iridovirus infection (Heldstab and Bestetti, 1982; Bollinger et al., 1999; Marschang et al., 1999; Docherty et al., 2003) were present in just five of nine cases. Clinical and pathologic differential diagnoses for the animals in this report before the confirmation of iridoviruses by molecular methods, virus isolation, and/or TEM, included

septicemia, based on the fibrinous splenitis and multicentric vasculitis, and chelonian herpesvirus infection (Johnson et al., 2005), based on the lesions of necrotizing stomatitis. Bacteria could not be demonstrated in the splenic lesions by tissue Gram stain, and all animals were negative by PCR for herpesvirus infection. Experimental inoculation of box turtles (*Terrapene ornata ornata*) and red eared sliders (*Trachemys scripta elegans*) with the *Ranavirus* isolate obtained from the Burmese star tortoise of this report replicated the lesions of multicentric vasculitis and fibrinous splenitis (Johnson et al., 2007), further supporting the diagnosis of iridovirus infection in the naturally occurring cases. Inclusion bodies were also rare in the experimentally inoculated turtles and in another recently reported natural outbreak of *Ranavirus* infection in captive box turtles (De Voe et al., 2004), reinforcing the observation that inclusions are an inconsistent finding in chelonian iridovirus infections. In both the 1991 Georgia, USA, box turtle case and an experimentally infected box turtle, iridovirus virions were demonstrable by TEM, despite a lack of observed inclusion bodies, suggesting that TEM may be a useful diagnostic tool, especially in cases that do not have appropriate samples for molecular diagnostics or virus isolation. Overall, the findings in this report suggest that iridovirus infections should be considered as part of the differential diagnosis in chelonians with lesions of stomatitis, splenitis, and multicentric vasculitis. Retrospective examination of other historic cases with these nonspecific lesions may yield additional diagnoses of chelonian iridovirus infection.

Aural abscesses (middle and inner ear infections below the tympanic scale) have been seen in box turtles (Jackson et al., 1972; Jacobson, 1981) and a variety of other chelonians (Graham-Jones, 1961; Keymer, 1978a,b). We received one of two wild box turtles that, in addition to caseous oral plaques, had aural abscesses. A variety of

bacteria, including *Corynebacterium* sp., *Pantoea agglomerans*, *Escherichia coli*, *Aeromonas hydrophila*, *Morganella morganii*, *Citrobacter*, *Enterobacter*, *Proteus vulgaris*, and *Pseudomonas* sp. have been cultured from these lesions (Willer et al., 2003). Although the route of infection probably involves retrograde migration of microorganisms up the eustachian tube, the pathogenesis of the disease is poorly understood. Organochlorine contaminants have been implicated as possible causes of these abscesses (Tangredi and Evans, 1997; Holladay et al., 2001). At this time, there is no evidence to implicate *Ranavirus* as a causative agent of aural abscesses in box turtles.

All chelonian and amphibian isolates in this study shared 100% sequence identity across a portion of the major capsid protein gene. The major capsid protein gene sequence is highly conserved among iridoviruses, although one study has shown enough diversity to distinguish closely related isolates (Tidona et al., 1998). Mao et al. (1997) compared MCP sequences and restriction enzyme patterns of whole genomic DNA of 10 vertebrate iridoviruses, including one virus isolated from a box turtle (TV3) and another from a Russian tortoise (TV5). Although the sequence obtained from a portion of the TV3 MCP gene indicated that it was identical to that of FV3, a restriction enzyme analysis using *HindIII* and *XbaI* showed a different restriction pattern between the two isolates. Our study found a similar result. An isolate from a box turtle from the Pennsylvania, USA, die off shared 100% sequence identity with FV3 across a portion of the MCP gene; however, using *HindIII*, the whole viral genomic restriction enzyme analysis pattern for the box turtle isolate differed slightly from that of FV3. A low-molecular weight fragment was present in the box turtle isolate in our report and was also present for TV3 and TV5 in the report by Mao et al. (1997). This suggests that the MCP gene may be too conserved to



determine whether different animals are infected with a similar virus.

An interesting and potentially significant finding was the presence of similar viruses, as determined by *HindIII* restriction enzyme analysis, in the Burmese star tortoise and a moribund southern leopard frog found within its pen. This suggests that both animals may have been infected with the same virus. Interclass infections have been shown previously in a natural setting where sympatric species of amphibians and fish were infected with the same virus species (Mao et al., 1999) as well as through experimental transmission studies (Moody and Owens, 1994). There are several ways that chelonians and amphibians might be exposed to the same virus. Previous studies in salamanders have shown that transmission can occur through cannibalism of infected individuals (Jancovich et al., 2001; Pearman et al., 2004). Box turtles are omnivorous, and tortoises, although normally herbivorous, may opportunistically feed on carrion. This was confirmed when animal caretakers at the site of the Burmese star tortoise death in Georgia, USA, observed a radiated tortoise (*Geochelone radiata*) and a Burmese black mountain tortoise (*Manouria emys phayrei*), both normally considered herbivorous, eating dead amphibians in nearby pens. There could also be a common environmental source of virus, such as shared bodies of water. Iridoviruses are quite resistant and thought to be capable of persisting in water sources for an extended time (Daszak et al., 1999). Iridoviruses create systemic infections, and thus, a vector-borne route of transmission might also be a way that both amphibians and chelonians could become infected.

In summary, this report demonstrates that *Ranavirus* is a significant pathogen of chelonians and suggests that amphibians might serve as a source of infection for chelonians; or possibly, this virus exists at a low level of infection in chelonian populations that occasionally is induced

into lethal expression by other stressors. Epidemiologic studies on wild populations where outbreaks have occurred are needed to sort out these various possibilities. Although our study is limited to ranaviral infection of certain chelonians in the United States, because ranaviruses are considered a global threat to amphibian populations, based on the lack of host specificity, high virulence, and global distribution (Daszak et al., 1999), they should likewise be considered a global threat to chelonian populations.

#### ACKNOWLEDGMENTS

This work was funded by grant D04Z0-11 from the Morris Animal Foundation and the Batchelor Foundation, College of Veterinary Medicine, University of Florida. We thank A. Childress, for laboratory support, S. Seibert and B. Atkinson for field support, and M. Robinson and K. Dodd for providing necropsy reports and archived materials. We thank D. Heard for providing Figure 1C, 1D. We thank Dr. J. Stanley and K. Goodblood of the Buttermilk Hill Nature Sanctuary for access to their chelonian and amphibian populations. We also thank L. Schneider at the University of Florida Electron Microscopy Core Laboratory for TEM support.

#### LITERATURE CITED

- ALLENDER, M. C., M. M. FRY, A. R. IRIZARRY, L. CRAIG, A. J. JOHNSON, AND M. JONES. 2006. Intracytoplasmic inclusions in circulating leukocytes from an eastern box turtle (*Terrapene carolina carolina*) with iridoviral infection. *Journal of Wildlife Diseases* 42: 677–84.
- ALTSCHUL, S. F., T. L. MADDEN, A. A. SCHÄFFER, J. ZHANG, Z. ZHANG, W. MILLER, AND D. J. LIPMAN. 1997. Gapped BLAST and PSI-BLAST: A new generation of protein database search programs. *Nucleic Acid Research* 25: 3389–402.
- BOLLINGER, T. K., J. MAO, D. SCHOCK, R. M. BRIGHAM, AND V. G. CHINCHAR. 1999. Pathology, isolation and preliminary molecular characterization of a novel iridovirus from tiger salamanders in Saskatchewan. *Journal of Wildlife Diseases* 35: 413–29.
- CHEN, Z. X., J. C. ZHENG, AND Y. L. JIANG. 1999. A new iridovirus isolated from soft-shelled turtle. *Virus Research* 63: 147–151.
- DASZAK, P., L. BERGER, A. A. CUNNINGHAM, A. D. HYATT, D. E. GREEN, AND R. SPEARE. 1999. Emerging infectious diseases and amphibian



- population declines. *Emerging Infectious Diseases* 5: 735–48.
- , A. A. CUNNINGHAM, AND A. D. HYATT. 2000. Emerging infectious diseases of wildlife—Threats to biodiversity and human health. *Science* 287(5452): 443–449.
- DE VOE, R., K. GEISSLER, S. ELMORE, D. ROTSTEIN, G. LEWBART, AND J. GUY. 2004. Ranavirus-associated morbidity and mortality in a group of captive eastern box turtles (*Terrapene carolina carolina*). *Journal of Zoo and Wildlife Medicine* 35: 534–543.
- DOCHERTY, D. E., C. U. METEYER, J. WANG, J. MAO, S. T. CASE, AND V. G. CHINCHAR. 2003. Diagnostic and molecular evaluation of three iridovirus-associated salamander mortality events. *Journal of Wildlife Diseases* 39(3): 556–66.
- DODD, K. C. 2001. North American box turtles: A natural history. University of Oklahoma Press, Norman, Oklahoma, 231 pp.
- FLANAGAN, J. 2000. Disease and health considerations. In *Turtle conservation*, M. W. Klemens (ed.). Smithsonian Institution Press, Washington, D.C., pp. 85–95.
- GRAHAM-JONES, O. 1961. Some clinical conditions affecting the North African tortoise (“Greek” tortoise), *Testudo graeca*. *Veterinary Record* 73: 313–321.
- GREEN, D. E., K. A. CONVERSE, AND A. K. SCHRADER. 2002. Epizootiology of sixty-four amphibian morbidity and mortality events in the USA, 1996–2001. *Annals of the New York Academy of Science* 969: 323–39.
- HARVELL, C. D., K. KIM, J. M. BURKHOLDER, R. R. COLWELL, P. R. EPSTEIN, D. J. GRIMES, E. E. HOFMANN, E. K. LIPP, A. D. OSTERHAUS, R. M. OVERSTREET, J. W. PORTER, G. W. SMITH, AND G. R. VASTA. 1999. Emerging marine diseases—Climate links and anthropogenic factors. *Science* 285: 1505–1510.
- HELDSTAB, A., AND G. BESTETTI. 1982. Spontaneous viral hepatitis in a spur-tailed Mediterranean land tortoise (*Testudo hermanni*). *Journal of Zoo Animal Medicine* 13: 113–120.
- HEPPELL, S. S. 1998. Application of life-history theory and population model analysis to turtle conservation. *Copeia* 2: 367–75.
- HOLLADAY, S. D., J. C. WOLF, S. A. SMITH, D. E. JONES, AND J. L. ROBERTSON. 2001. Aural abscesses in wild caught box turtles (*Terrapene carolina carolina*). Possible role of organochlorine-induced hypovitaminosis A. *Ecotoxicology and Environmental Safety* 48: 99–106.
- HYATT, A. D., M. WILLIAMSON, B. E. COUPAR, D. MIDDLETON, S. G. HENGSTBERGER, A. R. GOULD, P. SELLECK, T. G. WISE, J. KATTENBELT, A. A. CUNNINGHAM, AND J. LEE. 2002. First identification of a ranavirus from green pythons (*Chondropython viridis*). *Journal of Wildlife Diseases* 38: 239–252.
- JACKSON, C. G., M. FULTON, AND M. M. JACKSON. 1972. Cranial asymmetry with massive infection in a box turtle. *Journal of Wildlife Diseases* 8: 275–277.
- JACOBSON, E. R. 1981. Diseases of Reptiles, Part II: Infectious diseases. *Compendium on Continuing Education for the Practicing Veterinarian* 3: 195–200.
- JANCOVICH, J. K., E. W. DAVIDSON, J. F. MORADO, B. L. JACOBS, AND J. P. COLLINS. 2001. Transmission of the *Ambystoma tigrinum* virus to alternative hosts. *Diseases of Aquatic Organisms* 46: 159–163.
- JOHNSON, A. J., A. P. PESSIER, J. F. X. WELLEHAN, R. BROWN, AND E. R. JACOBSON. 2005. Identification of a novel herpesvirus from a California desert tortoise (*Gopherus agassizii*). *Veterinary Microbiology* 111: 107–116.
- , ———, AND E. R. JACOBSON. 2007. Experimental transmission of a *Ranavirus* in western ornate box turtles (*Terrapene ornata ornata*) and red-eared sliders (*Trachemys scripta elegans*). *Veterinary Pathology* 44: 285–297.
- KEYMER, I. F. 1978a. Diseases of chelonians: (1) Necropsy survey of tortoises. *Veterinary Record* 103: 548–552.
- . 1978b. Diseases of chelonians: (2) Necropsy survey of terrapins and turtles. *Veterinary Record* 103: 577–582.
- KLEMENS, M. W. 2000. Turtle conservation. Smithsonian Institution Press, Washington, D.C., 334 pp.
- LANGDON, J. S., AND J. D. HUMPHREY. 1987. Epizootic haematopoietic necrosis, a new viral disease in redfin perch, *Perca fluviatilis* L., in Australia. *Journal of Fish Diseases* 10: 289–297.
- MAO, J., R. P. HEDRICK, AND V. G. CHINCHAR. 1997. Molecular characterization, sequence analysis and taxonomic position of newly isolated fish iridoviruses. *Virology* 229: 212–20.
- , D. E. GREEN, G. FELLERS, AND V. G. CHINCHAR. 1999. Molecular characterization of iridoviruses isolated from sympatric amphibians and fish. *Virus Research* 63: 45–52.
- MARSCHANG, R. E., P. BECHER, H. POSTHAUS, P. WILD, H.-J. THIEL, U. MÜLLER-DOBLIES, E. F. KALETA, AND L. N. BACCARIANI. 1999. Isolation and characterization of an iridovirus from Hermann’s tortoises (*Testudo hermanni*). *Archives of Virology* 144: 1909–1922.
- , S. BRAUN, AND P. BECHER. 2005. Isolation of a ranavirus from a gecko (*Uroplatus fimbriatus*). *Journal of Zoo and Wildlife Medicine* 36: 295–300.
- MCDOWELL, E. M., AND B. F. TRUMP. 1976. Historical fixatives suitable for diagnostic light and electron microscopy. *Archives of Pathology and Laboratory Medicine* 100: 405–414.
- MOODY, N. J. G., AND L. OWENS. 1994. Experimental demonstration of the pathogenicity of a frog

- virus, *Bohle iridovirus*, for a fish species, barramundi *Lates calcarifer*. *Diseases of Aquatic Organisms* 18: 95–102.
- MORSE, S. S. 1995. Factors in the emergence of infectious diseases. *Emerging Infectious Diseases* 1: 7–15.
- MÜLLER, M., N. ZANGGER, AND T. DENZLER. 1988. Iridovirus—epidemie bei der griechischen landschildkröte (*Testudo hermanni hermanni*). In *Verhandlungsbericht des 30 Internationalen Symposiums über die Erkrankungen der Zoo und Wildtiere*, Sofia, Bulgaria, 11–15 May, pp. 271–274. [In German.]
- PEARMAN, P. B., T. W. GARNER, M. STRAUB, AND U. F. GREBER. 2004. Response of the Italian agile frog (*Rana latastei*) to a ranavirus, frog virus 3: A model for viral emergence in naive populations. *Journal of Wildlife Diseases* 40: 660–669.
- ROSSELL, C. R., I. M. ROSSELL, M. M. ORRACA, AND J. W. PETRANKA. 2002. Epizootic disease and high mortality in a population of Eastern box turtles. *Herpetological Review* 33: 99–101.
- SEIGEL, R. A., R. B. SMITH, AND N. A. SEIGEL. 2003. Swine flu or 1918 pandemic? Upper respiratory tract disease and sudden mortality of gopher tortoises (*Gopherus polyphemus*) on a protected habitat in Florida. *Journal of Herpetology* 37: 137–44.
- TANGREDI, B. P., AND R. H. EVANS. 1997. Organochlorine pesticides associated with ocular, nasal, or otic infection in the eastern box turtle (*Terrapene carolina carolina*). *Journal of Zoo and Wildlife Medicine* 28: 97–100.
- TIDONA, C. A., P. SCHNITZLER, R. KEHM, AND G. DARAI. 1998. Is the major capsid protein of iridoviruses a suitable target for the study of viral evolution? *Virus Genes* 16: 59–66.
- TOKUDA, Y., T. NAKANURE, K. SATONAKA, S. MAEDA, K. DOI, S. BABA, AND T. SUGIYAMA. 1990. Fundamental study on the mechanisms of DNA degradation in tissues fixed in formaldehyde. *Journal of Clinical Pathology* 43: 748–751.
- TURTLE CONSERVATION FUND. 2002. A global action plan for conservation of tortoises and freshwater turtles: Strategy and funding prospectus 2002–2007. M.T.C. Printing, Leominster, Massachusetts, pp. 12–15.
- UNITED STATES FISH AND WILDLIFE SERVICE. 1994. Desert tortoise (Mojave population) recovery plan. U.S. Fish and Wildlife Service, Portland, Oregon, 73 pp.
- VANDEVANter, D. R., P. WARRENER, L. BENNETT, E. R. SCHULTZ, S. COULTER, R. L. GARBER, AND T. M. ROSE. 1996. Detection and analysis of diverse herpesviral species by consensus primer PCR. *Journal of Clinical Microbiology* 34: 1666–1671.
- WESTHOUSE, R. A., E. R. JACOBSON, R. K. HARRIS, K. R. WINTER, AND B. L. HOMER. 1996. Respiratory and pharyngo-esophageal iridovirus infection in a gopher tortoise (*Gopherus polyphemus*). *Journal of Wildlife Diseases* 32: 682–686.
- WILLER, C. J., G. A. LEWBART, AND C. LEMONS. 2003. Aural abscesses in wild eastern box turtles, *Terrapene carolina carolina*: Aerobic bacterial isolates and distribution of lesions. *Journal of Herpetological Medicine and Surgery* 13: 4–9.

*Received for publication 24 June 2006.*