

Sarcocystis IN WHITE-TAILED DEER

Authors: KARSTAD, LARS, and TRAINER, D. O.

Source: Bulletin of the Wildlife Disease Association, 5(1) : 25-26

Published By: Wildlife Disease Association

URL: <https://doi.org/10.7589/0090-3558-5.1.25>

BioOne Complete (complete.BioOne.org) is a full-text database of 200 subscribed and open-access titles in the biological, ecological, and environmental sciences published by nonprofit societies, associations, museums, institutions, and presses.

Your use of this PDF, the BioOne Complete website, and all posted and associated content indicates your acceptance of BioOne's Terms of Use, available at www.bioone.org/terms-of-use.

Usage of BioOne Complete content is strictly limited to personal, educational, and non - commercial use. Commercial inquiries or rights and permissions requests should be directed to the individual publisher as copyright holder.

BioOne sees sustainable scholarly publishing as an inherently collaborative enterprise connecting authors, nonprofit publishers, academic institutions, research libraries, and research funders in the common goal of maximizing access to critical research.

Sarcocystis IN WHITE-TAILED DEER

Frequently, in recent years, we have made chance observations of sarcosporidian parasites in deer, moose, caribou and wapiti. Although their occurrence is documented in several cervid species (Karstad, L. (Editor) 1964. Wildl. Dis. #43), we could find no references to sarcosporidia in white-tailed deer (*Odocoileus virginianus*).

A study was carried out in 1966 and 1967 to determine the frequency of *Sarcocystis* sp. in white-tailed deer from several areas of North America.

Methods

Cross-sections of tongues taken from deer killed by hunters and from deer killed in the course of other research, were fixed in 10% formalin, embedded in paraffin, sectioned and stained with hematoxylin and eosin. Specimens were obtained from deer in Texas, Wisconsin and Ontario. One 6 to 8 μ thick cross-section of tongue per deer was examined. In some cases sections of diaphragm of similar size also were examined. Infection rates were calculated, and when appropriate information was available, separated on the basis of sex and age data.

Results and Discussion

Although they were not seen grossly, *Sarcocystis* sp. were detected microscopically in approximately 80% of the 208 white-tailed deer examined and infection was common in all of the geographic sites studied (Table 1).

TABLE 1. Rates of Sarcosporidia Infections in White-tailed Deer

Source	No. Infected/ Total	No. Males Infected/ Total Males	No. Females Infected/ Total Females
Griffith Is. Ontario	14/20	5/8	9/12
Bruce Co. Ontario	21/30	7/13	11/14
Frontenac Co. Ontario	13/20	Unknown	Unknown
Welder Refuge Texas	43/53	Unknown	Unknown
Black River Falls Wisconsin	25/33	14/20	11/13
Bayfield Co. Wisconsin	13/14	5/6	8/8
Douglas Co. Wisconsin	18/19	7/7	11/12
Price Co. Wisconsin	17/19	10/10	7/9
Total	164/208	48/64	57/68

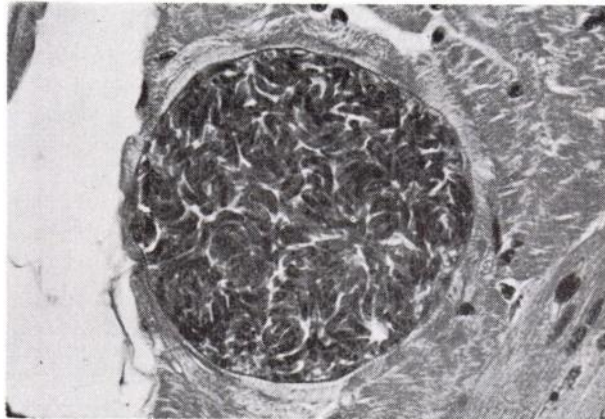


FIGURE 1. *Sarcocystis* cyst in striated muscle of the tongue of a white-tailed deer. Hematoxylin-eosin X 1600.

Sarcocystis cysts in white-tailed deer appeared to be similar in structure to those of other species. A representative cyst is shown in figure 1. Numbers of sarcosporidia cysts per histologic section varied from none to 20. The tongue appeared to be a more consistent source of *Sarcocystis* than did the diaphragm. In one sampling of deer on the Welder Refuge, Texas, 19 of 26 or 73% of the tongues were positive for *Sarcocystis*, whereas only 25% of the diaphragm specimens from these same deer were found to contain sarcosporidia.

As may be expected, higher rates of infection were found in adults, than in fawns. In one sampling of deer on Griffith Island, Ontario, in December, 1967, only 1 of 6 tongue sections from fawns contained *Sarcocystis*, while 13 of 14 tongues from adults were infected. In all areas, the infection rates recorded are minimal, since some low infections were probably missed with the screening procedure used. The infection rates for males and females were approximately equal (Table 1).

There was no evidence of pathogenicity of *Sarcocystis* in any of the deer examined.

Summary

Sarcocystis sp. were found in histologic sections of tongue muscles from 164 of 208 white-tailed deer from Ontario, Wisconsin and Texas. Rates of infection in all areas were similar.

Acknowledgements

This study was supported in part by a grant from the Government of Ontario through the Conjoint Committee of the Ontario Department of Lands and Forests and University of Guelph. Assistance in collection of specimens was provided by Caleb Glazener, Welder Wildlife Foundation, Sinton, Texas; James B. Hale, Wisconsin Department of Natural Resources; William Holsworth, University of Western Ontario; and Andrew L. Fletch, University of Guelph.

LARS KARSTAD

and

D. O. TRAINER

Section of Zoonoses and Wildlife Diseases
Ontario Veterinary College
University of Guelph, Guelph, Ontario

Department of Veterinary Science
University of Wisconsin
Madison, Wisconsin, U.S.A.

September 10, 1968