

A HELMINTHOLOGICAL SURVEY OF WILD MINK IN WISCONSIN

Authors: DORNEY, ROBERT S., and LAUERMAN, LLOYD H.

Source: Bulletin of the Wildlife Disease Association, 5(1) : 35-36

Published By: Wildlife Disease Association

URL: <https://doi.org/10.7589/0090-3558-5.1.35>

The BioOne Digital Library (<https://bioone.org/>) provides worldwide distribution for more than 580 journals and eBooks from BioOne's community of over 150 nonprofit societies, research institutions, and university presses in the biological, ecological, and environmental sciences. The BioOne Digital Library encompasses the flagship aggregation BioOne Complete (<https://bioone.org/subscribe>), the BioOne Complete Archive (<https://bioone.org/archive>), and the BioOne eBooks program offerings ESA eBook Collection (<https://bioone.org/esa-ebooks>) and CSIRO Publishing BioSelect Collection (<https://bioone.org/csiro-ebooks>).

Your use of this PDF, the BioOne Digital Library, and all posted and associated content indicates your acceptance of BioOne's Terms of Use, available at www.bioone.org/terms-of-use.

Usage of BioOne Digital Library content is strictly limited to personal, educational, and non-commercial use. Commercial inquiries or rights and permissions requests should be directed to the individual publisher as copyright holder.

BioOne is an innovative nonprofit that sees sustainable scholarly publishing as an inherently collaborative enterprise connecting authors, nonprofit publishers, academic institutions, research libraries, and research funders in the common goal of maximizing access to critical research.

A HELMINTHOLOGICAL SURVEY OF WILD MINK IN WISCONSIN

Helminth parasites of wild mink (*Mustela vison*) have been investigated by numerous parasitologists in North America (see review by Erickson, 1946, Am. Midl. Nat. 36: 494-509). This paper presents results of examining 47 wild mink carcasses submitted to us for necropsy after skinning by trappers. All animals were trapped at Horicon Marsh (Dodge County), Wisconsin, in the fall and winter 1958-59. The external musculature, frontal sinuses, lungs, trachea, kidneys, urinary bladder, and gastrointestinal tract were examined for evidence of parasitic infection. In addition, bile was microscopically examined for helminth ova. All helminths were placed in FAA and later identified.

The parasites we found (Table 1) have all been previously identified from mink in the United States. The incidence of *Filaroides* (Table 1) deserves some comment since it is not based on the positive identification of the worms themselves. Anderson (1962, Can. J. Zool. 40: 893-920) identified 3 genera of metastrongyles in Ontario mink. Based on his descriptions, our mature female fragments, tentatively identified as *Filaroides martis*, could not be *Perostrongylus pridhami* (Anderson, 1963, Can. J. Zool. 41: 801-809) because in our samples they had a width range of 224-448 μ . In Anderson's material female *P. pridhami* had a maximum width of only 145 μ , while his female *F. martis* had a maximum width of 400 μ . Since the other metastrongyle found by Anderson (*Crenosoma hermani*) occurred in the bronchi, in the absence of positive identification of male fragments it is likely the tightly coiled worm masses which we recovered within nodules in the lung tissue are referable to *F. martis*.

The *Capillaria* sp. we observed were found in both the stomach and small intestine. The 23 male capillarids recovered from the stomachs exhibited differences in length of caudal alae and bursal rays (papillae) at variance with the 7 males collected from the small intestines (103-139 μ compared to 80-96 μ and 19-39 μ compared to 6-10 μ see Figs. 1 and 2). The females collected from both sites were similar. Whether these populations of capillarids are distinct at the species level, we feel must await future experimental transmission. However, the male capillarid populations

TABLE 1. Occurrence of helminths in wild mink trapped at Horicon Marsh, Wisconsin.

Species	Occurrence	
	Ratio ¹	Per cent
<i>Alaria mustelae</i>	41/47	87
<i>Euparyphium beaveri</i> (Yamaguti, 1958) ²	7/47	15
<i>Corynosoma constrictum</i>	3/47	6
<i>Capillaria</i> sp.	35/47	74
<i>Filaroides martis</i>	18/42	43
<i>Skrjabinogylus nasicola</i>	35/41	85
<i>Molineus patens</i>	1/47	2

1. Ratio infected to total examined. In those cases in which the sample size is less than 47 frontal sinuses and lungs were unsuitable for examination.

2. *E. melis*, redescribed by Beaver (1941) and renamed by Yamaguti (1958).

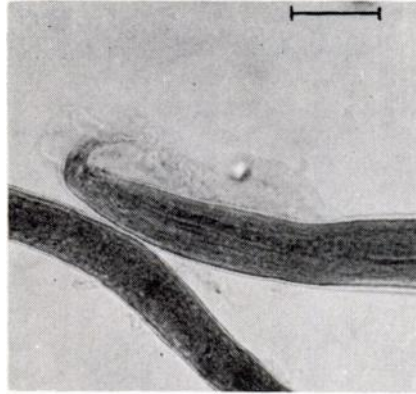


FIGURE 1. Posterior of male *Capillaria* sp. recovered from the stomach of a mink. The bursa (left) with its bursal ray and the caudal alae overlap. Scale is 50 μ .

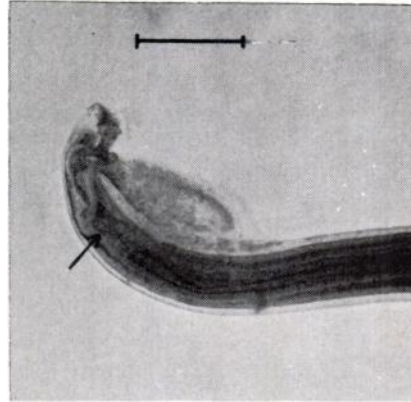


FIGURE 2. Posterior of male *Capillaria* sp. recovered from the intestine of a mink. The filiform tip (see arrow) of the spicule is recurved in this particular specimen. The bursa lies to the left and the caudal alae (slightly out of focus) above and to the right. Scale is 50 μ .

we observed from the stomach resemble a single male described from the stomach of a Scottish weasel as *Capillaria mustelorum* by Cameron and Parnell (1933. Proc. Royal Physical Soc. Edin. 22: 133-154), while the male intestinal capillarids we observed resemble those described under the same name (*C. mustelorum*) from the intestinal tract of mink collected at Horicon Marsh, Wisconsin, by Read (1949. J. Parasitol. 35: 223-230).

The presence of a helminth-induced gastritis in some mink may be worth comment. Large numbers of capillarids which we recovered from the stomachs of five mink apparently irritated the musoca to an extent sufficient to cause it to turn bright red.

The single occurrence of *Molineus patens* was a male which had spicules 149 and 158 μ in length. This, as well as spicule shape, differentiated our specimen from *Molineus mustelae* (Schmidt, 1965, J. Parasitol. 51: 164-168) described from two long-tailed weasels in Montana.

We would like to thank Mr. Harold Mathiak, Wisconsin Conservation Department for securing the carcasses and Dr. A. C. Todd, Department of Veterinary Science, University of Wisconsin, for the use of his laboratory. Dr. Roy C. Anderson and Mrs. MayBelle Chitwood assisted us in preparation of this manuscript.

ROBERT S. DORNEY and LLOYD H. LAUERMAN, JR.

University of Waterloo
Waterloo, Ontario; and
Biological Specialties
Middleton, Wisconsin

October 30, 1968