

## THE BUFFLEHEAD (*Bucephala albeola*): A NEW HOST RECORD FOR *Plasmodium*

Authors: KOCAN, R. M., and KNISLEY, J. O.

Source: Journal of Wildlife Diseases, 7(1) : 35

Published By: Wildlife Disease Association

URL: <https://doi.org/10.7589/0090-3558-7.1.35>

---

The BioOne Digital Library (<https://bioone.org/>) provides worldwide distribution for more than 580 journals and eBooks from BioOne's community of over 150 nonprofit societies, research institutions, and university presses in the biological, ecological, and environmental sciences. The BioOne Digital Library encompasses the flagship aggregation BioOne Complete (<https://bioone.org/subscribe>), the BioOne Complete Archive (<https://bioone.org/archive>), and the BioOne eBooks program offerings ESA eBook Collection (<https://bioone.org/esa-ebooks>) and CSIRO Publishing BioSelect Collection (<https://bioone.org/csiro-ebooks>).

Your use of this PDF, the BioOne Digital Library, and all posted and associated content indicates your acceptance of BioOne's Terms of Use, available at [www.bioone.org/terms-of-use](http://www.bioone.org/terms-of-use).

Usage of BioOne Digital Library content is strictly limited to personal, educational, and non-commercial use. Commercial inquiries or rights and permissions requests should be directed to the individual publisher as copyright holder.

---

BioOne is an innovative nonprofit that sees sustainable scholarly publishing as an inherently collaborative enterprise connecting authors, nonprofit publishers, academic institutions, research libraries, and research funders in the common goal of maximizing access to critical research.

## THE BUFFLEHEAD (*Bucephala albeola*): A NEW HOST RECORD FOR *Plasmodium*

During banding operations on Chesapeake Bay (Cove Point, Maryland) in January 1970, an adult male bufflehead (*Bucephala albeola*) was found dead near the trapping area. Necropsy revealed that the bird was in poor flesh but had vegetable matter and pieces of crab in its proventriculus and gizzard. Two Number 6 lead shot were found embedded in the muscle of the neck and 10 *acanthocephala* were in the large intestine. Blood films and tissue impressions were positive for *Plasmodium*. The spleen and liver appeared normal even though parasitemia was over 1 percent.

The blood film made from the bufflehead had schizonts, gametocytes, and various immature stages. Although all stages of the erythrocytic cycle were numerous, it was not possible to make a positive diagnosis. Figure 1 shows the most com-

mon forms observed in the original blood film. Mature schizonts (10-12  $\mu$ ) were most frequently located polar and to one side of the host cell nucleus, only slightly displacing it. The mean merozoite count was 20 (16-26) per mature schizont. Mature gametocytes (7-9  $\mu$ ) also were located polar and lateral to the nucleus but more frequently distorted the host cell.

By the time the *Plasmodium* was discovered the bird had been dead at least 36 hours. At this time pieces of spleen, liver, and lung were minced in 0.9 percent NaCl and the suspended cells inoculated intravenously into a 5-day-old Pekin duckling. Serial transfers of whole blood through ducklings every 4 days for 2 weeks failed to produce an infection of sufficient intensity for an accurate identification of the parasite.

No record of *Plasmodium* in the bufflehead could be found in the literature, and the only records of malaria in diving ducks which could be found were by Savage and McTavish (1951, *Parasitology* 37: 533-4) and Kocan (1968, *Bull. Wildlife Disease Assoc.* 4: 86-87).

It is worth noting that the level of parasitemia was rather high for the time of year the duck was collected. Normally malaria infections are latent by fall or winter and relapses do not occur until spring. The high parasitemia in this duck may have followed a depressed immunity resulting from other factors such as the lead shot and *acanthocephala* described above. Death of the bird was probably the result of a combination of these factors.

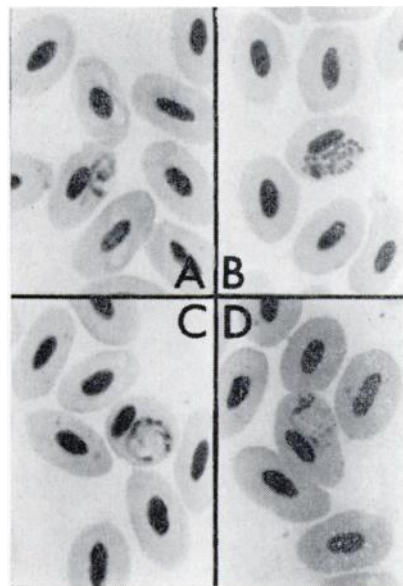


FIGURE 1. Erythrocytic stages seen in peripheral blood film of bufflehead: A, trophozoite; B, mature schizont; C, macrogametocyte; D, microgametocyte.

R. M. KOCAN and J. O. KNISLEY, JR.  
Bureau of Sport Fisheries and Wildlife  
Patuxent Wildlife Research Center  
Laurel, Maryland 20810

May 11, 1970