

OSSEOUS METAPLASIA IN THE ADRENAL CORTEX OF A TWO-TOED SLOTH

Authors: BROWN, RICHARD J., and ROBINSON, F. R.

Source: Journal of Wildlife Diseases, 7(1) : 46-48

Published By: Wildlife Disease Association

URL: <https://doi.org/10.7589/0090-3558-7.1.46>

The BioOne Digital Library (<https://bioone.org/>) provides worldwide distribution for more than 580 journals and eBooks from BioOne's community of over 150 nonprofit societies, research institutions, and university presses in the biological, ecological, and environmental sciences. The BioOne Digital Library encompasses the flagship aggregation BioOne Complete (<https://bioone.org/subscribe>), the BioOne Complete Archive (<https://bioone.org/archive>), and the BioOne eBooks program offerings ESA eBook Collection (<https://bioone.org/esa-ebooks>) and CSIRO Publishing BioSelect Collection (<https://bioone.org/csiro-ebooks>).

Your use of this PDF, the BioOne Digital Library, and all posted and associated content indicates your acceptance of BioOne's Terms of Use, available at www.bioone.org/terms-of-use.

Usage of BioOne Digital Library content is strictly limited to personal, educational, and non-commercial use. Commercial inquiries or rights and permissions requests should be directed to the individual publisher as copyright holder.

BioOne is an innovative nonprofit that sees sustainable scholarly publishing as an inherently collaborative enterprise connecting authors, nonprofit publishers, academic institutions, research libraries, and research funders in the common goal of maximizing access to critical research.

OSSEOUS METAPLASIA IN THE ADRENAL CORTEX OF A TWO-TOED SLOTH

The two-toed sloth, *Choloepus didactylus*, is a vertebrate that inhabits forests in Venezuela, northern Brazil, and occasionally Peru (Walker, 1964, *Mammals of the World*, 491).

The subject of this report was a 15 year-old male two-toed sloth that was found dead in the exhibit area of a zoo. Gross necropsy findings included acute enteritis in the area where a large amount of sand and a fragment of an orange were obstructing the small intestine. In addition, it had a mild focal dermatitis of undetermined etiology, involving the skin of the right leg. No other gross abnormality was seen. At the time of this necropsy, normal tissues were being taken for histological studies of various

animals; therefore, specimens were taken from all organs of the sloth. All tissues from this animal were within normal limits histopathologically, with possibly the following exception: within the cortex of one adrenal gland was a small oval focus of bone spicules and bone marrow elements (Fig. 1). Spicules of bone made up the periphery of the bony area and also traversed the center of the structure. As expected, the spicules contained both lacunae and haversian systems. In the spaces between the spicules, there was a network of connective tissue and reticulum which supported aggregates of bone marrow elements, including erythroid and myeloid cells. Numerous mature erythrocytes were also noted among the erythropoietic elements. On the surface of the




FIGURE 1. Island of bone metaplasia in the adrenal cortex of a two-toed sloth. H & E stain, X 20.

spicules of bone were many osteoblasts and an occasional triangular shaped osteoclast (Fig. 2). This bony structure compressed the adjacent zona reticularis and

zona fasciculata, but no inflammation was present. There were no islands of bony metaplasia in the other organs, including the opposite adrenal gland.

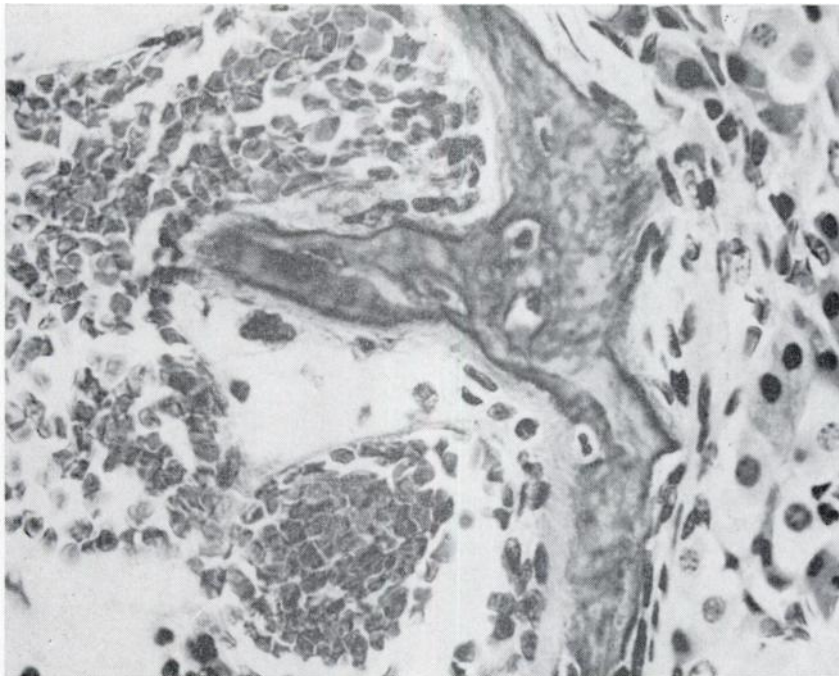


FIGURE 2. Spicule of bone in the area of osseous metaplasia of the adrenal with osteoblasts and an occasional osteoclast. H & E stain, X 525.

Discussion

Bone marrow in the adrenal of man was recognized by Grenke (Path. Suppl. 7, 311-325) in 1905, but no mention was made of actual bone. Kruse (1924, Anat. Rec. 28: 289-294), along with Arnold (1966, Path. Anat. 35: 64-107) and Oberling (1929, P. l'etude de cancer. 18: 234-246), considered such bone and bone marrow presence in the adrenal gland as ectopia. In rats, Schardein, et al (1968, Path. Vet. 5: 238-252) reported fat, bone, and marrow elements in the adrenal cortex; they called this a myelolipoma.

There is some evidence in man that adrenal calcification and perhaps ensuing ossification occur secondary to hemor-

rhage due to the trauma of birth associated with abnormal fetal position (Gabriele and Scheehan, 1964, Amer. J. of Roentgenography. 91: 656-658). A history of difficult birth could not be obtained in our animal, however.

Wooley (1915, J. Lab. and Clin. Med. 1: 502-508) reported bone with marrow in tuberculosis of the adrenal in man. He also pointed out that there is a relationship between blood supply and bone formation, and that ligation of the renal vasa often results in bone or marrow formation. Wooley also listed three hypotheses to account for heterotopic bone formation: (1) embryonal nests of osteo-

genic tissue, misplaced during development with proper stimuli or changed physiologic conditions producing bone or marrow; (2) embolism of bone marrow cells by way of the blood stream; (3) metaplasia.

Metaplasia occurs under several conditions: vitamin A deficiency, neoplasia, and chronic inflammation in foci of resolving hemorrhage. Also, bony metaplasia is often reported in area of wound healing (Smith and Jones, 1966, *Veterinary Pathology*, 93). The appearance of bone in the adrenal gland in the case reported here would seem to be an example of connective tissue metaplasia.

Connective tissue metaplasia occurs chiefly in association with chronic inflammation. The development of bone spicules where bone is usually absent is one of the best examples of connective tissue metaplasia. Bony metaplasia is also found frequently in the lungs of old dogs. These canine lungs often contain islands of bony metaplastic tissue that appear in the interstitial areas and usually are not associated with large blood vessels and respiratory passages. In these areas, for some reason that is yet to be explained,

connective tissue cells assume the character of osteoblasts and lay down bony trabeculae which contain bone marrow elements. Usually the tendency in metaplasia is to replace cells of greater differentiation with cells of lesser differentiation, as in our case where cells of the adrenal cortex were replaced by osteoblasts. The cause and the mechanisms of this connective tissue metaplasia are not clear. In the case of bone formation in new locations, perhaps a mild, chronic inflammation that has since resolved itself may somehow disorganize the chemical organizers that determine which way and just how far differentiation will go (Anderson, 1966, *Pathology*, 45-46).

Perhaps the occurrence of bone in the adrenal cortex of the two-toed sloth is a frequent finding and if so, could be considered normal. Two necropsies on two-toed sloths have been performed by one of us (RJB) and there was no osseous metaplasia in the adrenal glands. This adrenal change in animals is not common, and this is believed to be the first reported case of bony metaplasia in the adrenal gland of the South American two-toed sloth.

Summary

Osseous metaplasia was observed in the adrenal gland of a two-toed sloth and erythroid and myeloid elements were identified between the bony spicules.

Background information on the South American two-toed sloth is presented along with some theoretical aspects of bony metaplasia.

Acknowledgements

Opinions or conclusions contained in this report are those of the authors and do not necessarily reflect the views or endorsement of the U.S. Air Force and the U.S. Navy.

The material for this report is from the National Zoological Park, Washington, D.C.

The authors wish to acknowledge the kind assistance of Robert H. Edwards, M.D., in the preparation of the paper.

RICHARD J. BROWN

Major, USAF, VC

Chief, Comparative Pathology

Naval Aerospace Medical Research
Laboratory

Naval Aerospace Medical Center
Pensacola, Florida 32512

F. R. ROBINSON

Lt. Col., USAF, VC

Aerospace Pathology Division
Armed Forces Institute of Pathology
Washington, D.C. 20305

June 3, 1970