

MULTIPLE CONGENITAL SPLENIC CYSTS IN WILD TROUT

Authors: ROBERTS, RONALD J., and MACRITCHIE, G.

Source: Journal of Wildlife Diseases, 7(3) : 155-156

Published By: Wildlife Disease Association

URL: <https://doi.org/10.7589/0090-3558-7.3.155>

The BioOne Digital Library (<https://bioone.org/>) provides worldwide distribution for more than 580 journals and eBooks from BioOne's community of over 150 nonprofit societies, research institutions, and university presses in the biological, ecological, and environmental sciences. The BioOne Digital Library encompasses the flagship aggregation BioOne Complete (<https://bioone.org/subscribe>), the BioOne Complete Archive (<https://bioone.org/archive>), and the BioOne eBooks program offerings ESA eBook Collection (<https://bioone.org/esa-ebooks>) and CSIRO Publishing BioSelect Collection (<https://bioone.org/csiro-ebooks>).

Your use of this PDF, the BioOne Digital Library, and all posted and associated content indicates your acceptance of BioOne's Terms of Use, available at www.bioone.org/terms-of-use.

Usage of BioOne Digital Library content is strictly limited to personal, educational, and non-commercial use. Commercial inquiries or rights and permissions requests should be directed to the individual publisher as copyright holder.

BioOne is an innovative nonprofit that sees sustainable scholarly publishing as an inherently collaborative enterprise connecting authors, nonprofit publishers, academic institutions, research libraries, and research funders in the common goal of maximizing access to critical research.

MULTIPLE CONGENITAL SPLENIC CYSTS IN WILD TROUT

RONALD J. ROBERTS and G. MACRITCHIE, Department of Veterinary Pathology,
University of Glasgow Veterinary School, Glasgow, Scotland

Abstract: Two wild brown trout (*Salmo trutta*) removed from a small pool in the River Clyde, Scotland, had gross abnormalities of the splenic tissue. Histopathology showed that they both possessed multiple splenic cysts, which in view of the close similarities in the scale readings of the two fish, and the rarity of the condition, suggested that both were from the same spawning, and that the cysts were congenital.

INTRODUCTION

Cystic conditions of animals are usually congenital or parasitic in origin. Records of cystic conditions in fish, other than those associated with peritoneal parasites, are rare. The kidney and ovary appear to be the most frequent sites for non-parasitic cysts^{2,3,5,6,7,8} although Smith and Little⁴ have described a multiple cystic liver in an elasmobranch (*Torpedo californica*) which may have been non-

parasitic in origin. The purpose of the present paper is to record the occurrence of a polycystic spleen in two wild trout (*Salmo trutta*) caught in one pool of a Scottish river.

Two wild female trout (18 cms.) in good physical condition were removed from a small pool in the headwaters of the River Clyde during pollution studies. Necropsy revealed splenic abnormalities. Blocks of tissue from all viscera were processed for routine histopathology.

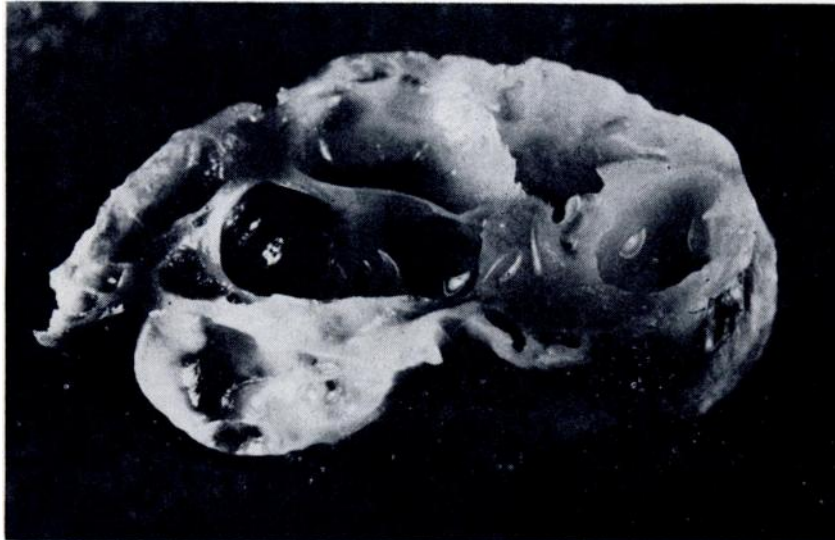


Figure 1. Cysts in spleen of wild trout. x10.

RESULTS

The spleen of each fish was grossly enlarged and contained numerous straw-coloured cysts, 0.2 to 0.4 cms. in diameter, protruding from the substance. No more than one third of the total splenic tissue was normal in colour and consistency. The cysts contained clear fluid.

Examination of haematoxylin and eosin stained paraffin sections showed that most of the cysts were lined by a single layer of endothelial cells, although some appeared to have no lining. It is possible that in the case of these latter cysts the lining, which was very delicate, may have been lost in processing.

The non-cystic splenic tissue was normal, apart from a reduction in the number of melanin deposits in the reticulo-endothelial centres¹ and the normal tissue extended to the junction with the cystic lining. None of the cysts was pedunculate, as was the case with some of the cysts described by Smith and Little⁴ and there was no compression of the splenic tissue

around the cysts. There were no abnormalities in any other organs.

Examination of the scales of the fish showed an analogous life history. They were 4+ age group trout with no spawning marks and very similar age ring distribution.

DISCUSSION

Although a large number of fish from this river have been examined in the past few years, no lesions such as those described above have been observed and the dearth of descriptions of such lesions also indicates their rarity. It is unlikely that a parasite system could exist on such a low intermediate host infection rate, and no evidence of parasitic organisms or inflammatory response was obtained. A congenital origin for the cysts is the most acceptable. The finding of two fish, of the same age class and scale history, with a rare congenital anomaly suggests that they may have arisen from the same spawning.

Acknowledgements

We wish to thank Messrs. Wm. Shearer for reading the scales, P. Soulsby and A. I. Wilson for assistance and A. Finnie for the photograph.

LITERATURE CITED

1. ELLIS, A. E. 1970. Personal communication.
2. JOHNSTONE, J. 1913. Diseased conditions of fishes. *Proc. Liverpool Biol. Soc.* 27: 196-218.
3. JOHNSTONE, J. 1915. Diseased and abnormal conditions of marine fishes. *Proc. Liverpool Biol. Soc.* 29: 80-118.
4. SMITH, A. C., and M. F. LITTLE. 1969. Liver lesions produced by hydatid-like cysts in an elasmobranch, the electric ray, *Torpedo californica*. *Nat. Cancer Inst. Monograph* 31: 251-254.
5. STOLK, A. 1954. Polycystic kidneys in the viviparous cyprinodonts *Lebistes reticulatus* X *helleri*, and the hybrid X. *helleri* X *P. maculatus*. *Proc. Kon. Ned. Ak. Wetensch C.* 57: 652-658.
6. STOLK, A. 1955a. Polycystic kidneys in the clearacid *Hyphessobrycon callistus*. *Proc. Kon. Ned. Ak. Wetensch* 58: 63-69.
7. STOLK, A. 1955b. Polycystic kidneys in the veiltail *Carassius auratus*. *Proc. Kon. Ned. Ak. Wetensch* 58: 70-73.
8. WILES, M. 1969. Fibrous and cystic lesions in the ovaries of aged Atlantic cod (*Gadus morhua*): a Preliminary Report. *J. Fish Res. Bd. Canada* 26: 3242-3246.

Received for publication December 30, 1970