

CONTRACAECIASIS IN PELICANIFORM BIRDS 1

Author: HUIZINGA, HARRY W.

Source: Journal of Wildlife Diseases, 7(3) : 198-204

Published By: Wildlife Disease Association

URL: <https://doi.org/10.7589/0090-3558-7.3.198>

The BioOne Digital Library (<https://bioone.org/>) provides worldwide distribution for more than 580 journals and eBooks from BioOne's community of over 150 nonprofit societies, research institutions, and university presses in the biological, ecological, and environmental sciences. The BioOne Digital Library encompasses the flagship aggregation BioOne Complete (<https://bioone.org/subscribe>), the BioOne Complete Archive (<https://bioone.org/archive>), and the BioOne eBooks program offerings ESA eBook Collection (<https://bioone.org/esa-ebooks>) and CSIRO Publishing BioSelect Collection (<https://bioone.org/csiro-ebooks>).

Your use of this PDF, the BioOne Digital Library, and all posted and associated content indicates your acceptance of BioOne's Terms of Use, available at www.bioone.org/terms-of-use.

Usage of BioOne Digital Library content is strictly limited to personal, educational, and non-commercial use. Commercial inquiries or rights and permissions requests should be directed to the individual publisher as copyright holder.

BioOne is an innovative nonprofit that sees sustainable scholarly publishing as an inherently collaborative enterprise connecting authors, nonprofit publishers, academic institutions, research libraries, and research funders in the common goal of maximizing access to critical research.

CONTRACAECIASIS IN PELICANIFORM BIRDS[†]

HARRY W. HUIZINGA, Department of Biological Sciences, Illinois State University,
Normal, Illinois 61761

Abstract: The ascaroid nematodes *Contracaecum spiculigerum* and *C. multipapillatum* were recovered in large numbers from the proventriculus of four species and 66 individuals of pelicaniform birds collected in Connecticut, Florida and South Dakota. Both species of nematodes were commonly observed to penetrate the mucosal wall of the proventriculus where they caused gross hemorrhages and ulcerations. Microscopic lesions consisted of compression atrophy of the glandular mucosa with generalized inflammatory infiltrations. *Contracaecum* may serve a beneficial role in the digestive physiology of cormorants by crawling through and breaking up ingested fish which facilitates the entrance of digestive enzymes. Wild-captured nestling cormorants held in captivity until maturity lost their nematode infections in three months suggesting that *Contracaecum* has a short life span.

INTRODUCTION

Ascaroid nematodes in the genus *Contracaecum* are common parasites in the proventriculus of pelicaniform birds where they have been observed in large numbers during stomach content analysis,^{2,8} and it has been suggested that they contribute to the death of birds.⁷ The life cycle of *C. spiculigerum* from fish-eating birds includes a copepod as possible first intermediate host and various fish as either first or second intermediate hosts.^{4,5} The parasite is often observed to penetrate into the wall of the proventriculus and cause lesions. The purpose of this paper is to give the results of a parasite survey that was conducted during a larger study of the histories of two species of *Contracaecum* from fish-eating birds.³ Lesions caused by the penetration of the nematodes into the proventriculus are described and a possible relationship of *Contracaecum* to the digestive physiology of pelicaniform birds is discussed.

MATERIALS AND METHODS

Host birds were killed with a shotgun and examined for parasites immediately or within a few hours. The proventricu-

lus was opened with a scissors in a dish of water and examined for numbers and types of worms and gross lesions. The proventriculus was soaked overnight in tap water and then scraped to free larval stages which had burrowed into the mucosa. Nematodes were fixed in 70% ethyl alcohol, cleared for study in lactophenol and identified.^{4,9,12} Proventriculus tissue containing representative lesions was photographed and then fixed in 10% neutral formalin, embedded in paraffin and stained with hematoxylin and eosin. The sex of birds was determined by gonadal examination.

RESULTS

Nematodes recovered

1. *Contracaecum spiculigerum*

Forty-five of 47 double-crested cormorants, *Phalacrocorax auritus*, collected at Noank, Connecticut during 1964 to 1965 were infected with *Contracaecum spiculigerum* and a total of 1521 nematodes was recovered. The mean number of worms for several collection dates within each month are given for convenience of presentation (Table 1). The worm burden ranged from 0 to 160 with

[†] Part of this study is from a Ph.D. dissertation, Department of Zoology and Entomology, University of Connecticut.

a grand mean of 32.4 worms per bird. There was no correlation between the sex of bird and parasite burden. Nine of the 47 cormorants had lesions in the mucosal wall of the proventriculus caused by nematode attachment.

The main food items recovered from the proventriculus of 30 cormorants were the following species of fish: *Tautoglabrus adspersus*, cunner, found in the stomach of 22 birds; *Pseudopleuronectes americanus*, winter flounder, 7; *Myoxocephalus octodecimspinosus*, sculpin, 7; *Menidia menidia*, silversides,³; *Anchoa* sp., anchovy, 1; *Fundulus heteroclitus*, killifish, 1; and *Tautoga onitis*, blackfish,

1. Larval stages of *Contracaecum* sp. were found encapsulated in the mesenteries of naturally infected fish including the cunner, flounder, killifish and sculpin. These encapsulated larvae were comparable in size and morphology to the immature stages of *C. spiculigerum* observed within the proventriculus of several cormorants (Table 1).

Eleven European cormorants, *Phalacrocorax carbo carbo*, collected at Noank, Connecticut during 1964 were infected with a total of 828 *C. spiculigerum*. The worm burden ranged from 5 to 183 with a grand mean of 75.3 worms per bird (Table 2). Although not measured,

Table 1. Sex and mean numbers of *Contracaecum spiculigerum* from Double-Crested Cormorants collected at Noank, Connecticut, 1964-65.

No. Birds Examined	Month Examined	Sex and Mean Numbers of Worms Recovered			
		Male	Female	Immature	Totals
10	July 1964	8.1	7.8	18.7	34.6
7	Aug. 1964	10.4	7.7	20.4	38.6
5	Sept. 1964	13.2	18.2	17.8	49.2
20	Oct. 1964	9.2	9.7	11.3	30.1
2	Nov. 1964	2.5	3.0	2.5	8.0
3	April 1965	6.3	3.7	3.0	13.6
47	Mean	9.1 ± 8.6	9.2 ± 10.6	14.0 ± 18.0	32.4 ± 3.16

Table 2. Sex and numbers of *Contracaecum spiculigerum* from European Cormorants collected at Noank, Connecticut, 1964-65.

Sex of Bird	Date Captured	Worms Recovered			Total
		Male	Female	Immature	
F	9-28-64	5	8	107	120
M	10-7-64	67	50	66	183
M	10-14-64	4	1	2	7
M	10-14-64	12	12	62	86
F	10-24-64	2	12	9	23
M	11-2-64	29	67	10	106
F	11-2-64	3	2	0	5
M	11-2-64	36	46	0	82
F	11-2-64	12	28	11	51
M	11-9-64	12	2	9	23
F	11-25-64	58	76	8	142
5F	Total	240	304	284	828
6M	Mean	21.8 ± 22.9	27.6 ± 27.6	25.8 ± 35.7	75.3 ± 59.0

worms recovered from the European cormorant were visibly larger than those from the double-crested cormorant. The following fish were found in the stomach contents of the European cormorant: cunner, tautog and sculpin.

C. spiculigerum was found in lesser numbers in two non-pelicaniform birds: the black-crowned night heron, *Nycticorax nycticorax* and American merganser, *Mergus americanus*, collected at Noank, Connecticut during 1965.

Individual specimens of the brown pelican, *Pelicanus occidentalis*, and the Florida sub-species of the double-crested cormorant, *P. auritus floridanus*, collected during January 1966 at Sarasota, Florida were infected with 200 and 50 *C. spiculigerum*, respectively. Although measurements were not made, worms recovered from the pelican were markedly larger than those previously recovered from cormorants.

Two double-crested cormorants collected at Dry Lake, South Dakota on June 22, 1970 were infected with *C. spiculigerum* in numbers comparable to the data given in Table 1. Two young cormorants, approximately 2 to 3 weeks old, were removed from the nest at the Dry Lake, South Dakota rookery on June 22, 1970 and held in captivity for several months until mature. The birds were given a diet of frozen fish supplemented with multiple vitamins. Eggs of *C. spiculigerum* were observed in the feces of these birds on June 23, 1970 and at weekly intervals until the birds spontaneously stopped passing eggs during the week of October 1 to 7, 1970. Worms were not found in these birds upon necropsy following death of unknown causes during January 1971.

2. *Contracaecum multipapillatum*

A second species, *C. multipapillatum*, was found in the proventriculus of six water turkeys, *Anhinga anhinga*, collected near Placida, Florida in July, 1965. Worms recovered from one bird were 56 males, 76 females and 26 immatures.

Pathological Observations

1. Gross Lesions

Adult and larval worms of *C. spiculigerum* were frequently observed to burrow into the mucosal wall of the proventriculus causing petechial hemorrhages, ecchymoses and erosive ulcerations (Figures 1, 2). However, the majority of the worms were usually found lying unattached within the lumen of the proventriculus. *C. multipapillatum* penetrated into the proventriculus of the anhinga more frequently than did *C. spiculigerum* in the cormorant (Figure 3). Penetration was restricted to the glandular mucosa and worms were not observed to enter the thick underlying muscle layers of the proventriculus. The nematodes of both species attached firmly with their anterior mouth parts and were difficult to pull free (Figure 4).

2. Microscopic Lesions

Histological examination revealed adult worms of *C. multipapillatum* embedded in the mucosal wall of the proventriculus where they caused compression atrophy of the glandular portion (Figure 5). In some sections, an inflammatory reaction was observed in the mucosa adjacent to burrowing worms. The inflammatory changes consisted of focal accumulations of lymphocytic and lymphoblastic cells which had infiltrated into the submucosa, muscularis mucosa and muscle layers of the proventriculus (Figure 6).

DISCUSSION

Owre⁸ reported the common occurrence of *Contracaecum* spp. in the stomachs of birds in the families Anhingidae, Pelicanidae and Phalacrocoracidae collected in Florida. The nematodes were often observed penetrating into the stomach wall (proventriculus) and into the flesh of ingested fish. He theorized that the nematode may serve a mutualistic role by crawling into and breaking up food masses, thereby aiding in digestion. He also suggested that, in the absence of food, the parasites may feed upon the host alimentary tract. Penner⁹ described ulcers in the stomachs of sea lions produced by the burrowing habits

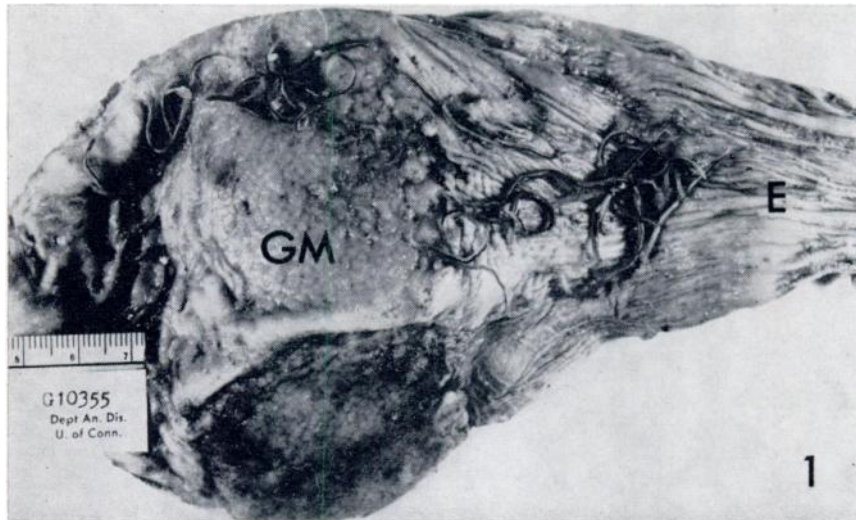


Figure 1. Proventriculus of double-crested cormorant opened to show characteristic numbers of *C. spiculigerum*. Note glandular mucosa (GM), and esophagus (E).

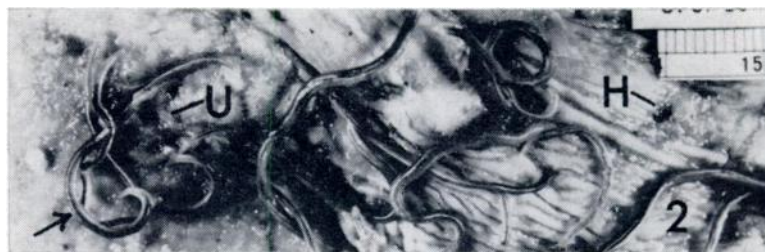

Figure 2. Close-up of portion of Figure 1, showing attached worm (arrow) with resultant hemorrhage (H) and ulceration (U) of mucosa.



Figure 3. Lateral view of cut portion of proventriculus wall of anhinga with *C. multipapillatum* attached to and extending from glandular mucosa (actual size).

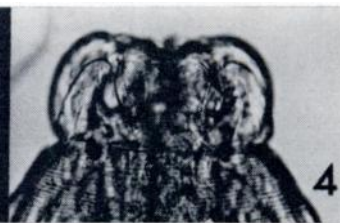

Figure 4. Anterior end of *C. multipapillatum*. Note lips used for attachment (X130).

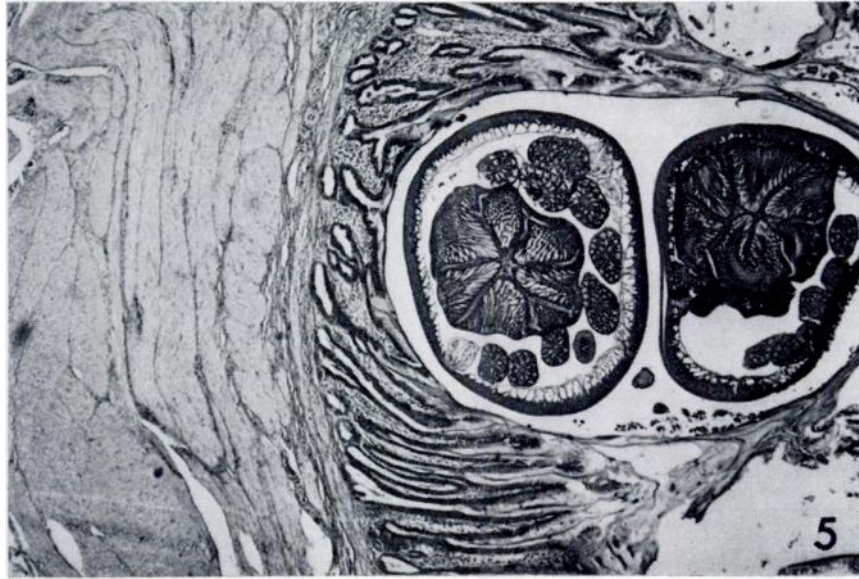


Figure 5. Section of tissue in Figure 3, with nematodes embedded in mucosa and causing compression atrophy (X130).

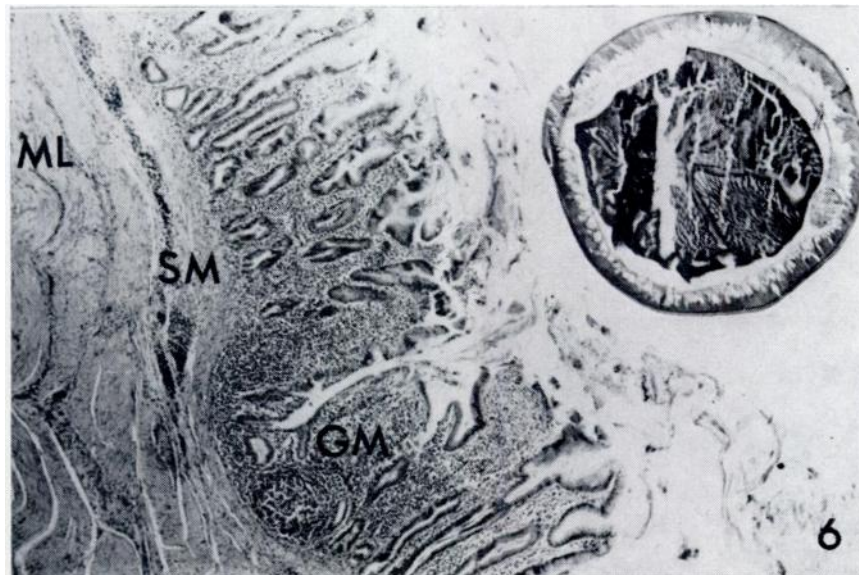


Figure 6. As Figure 5, but showing inflammatory response throughout glandular mucosa (GM), submucosa (SM), and muscle layers (ML) (X130).

of *Contracaecum* spp. Vik¹¹ observed the penetration of "anisakis-type" larvae into the stomach wall of porpoises with resulting ulcers. Van Theil et al.¹⁰ observed an acute abdominal disease syndrome in man caused by larval anisakid nematodes of herring.

In the present study, both *C. spiculigerum* and *C. multipapillatum* penetrated into the mucosa of the proventriculus where they caused lesions. It was concluded that mucosal penetration is a common behavior of *Contracaecum spiculigerum* which shows a wide range of host specificity in birds of the Order Pelicaniformes. However, it has not been established that this parasite is capable of causing illness or death. Individual birds found dead or dying, that also have heavy nematode infections, should be examined carefully for other disease-causing agents.

Contracaecum spp. was observed crawling through and apparently feeding upon ingested fish tissue within the bird's proventriculus, which confirms the observations of Owre.⁸ However, the parasites were found embedded in the proventriculus whether or not fish food was present. There was no evidence that the worms were feeding upon the host tissue as an alternate to ingested food, and histochemical study is needed to clarify this problem. The presence of large numbers of penetrating nematodes had no observable effect upon the condition of the birds examined. The habit of attachment appears to anchor the worms against the abrasive movement of undigested bone material which is passing from the proventriculus into the intestine.

The movement of *Contracaecum* through the food bolus within the proventriculus appears to aid the bird's digestive process by mechanically breaking up and facilitating the entrance of digestive enzymes into the food. As such, the worms may provide a benefit to the bird, but in view of their penetration habit, *Contracaecum* cannot be considered a mutualistic organism.⁸ That *Contracaecum* has both parasitic and mutualistic tendencies serves to illustrate the well-known overlap between various categories of symbiosis.¹

The observation that three week old nestling cormorants passed eggs of *C. spiculigerum* in the feces suggests that the young birds had acquired patent adult worms at a very early age by either of two possible methods: 1. ingestion of fish containing infective larval stages with subsequent maturation of the worms, and 2. passage of mature worms from the parent bird along with regurgitated fish. Since the worms were found to penetrate into ingested fish and the parent cormorants were observed to feed their young by regurgitation of stomach contents, the second method is most probable. In addition, it is unlikely that the encapsulated larval stage from fish could have undergone the necessary molts and development to the patent adult worm within the period of three weeks. The spontaneous loss of infection in captive cormorants after three months suggests that *C. spiculigerum* may have a short life span. This might explain why pelicaniform birds do not become superinfected during a lifetime of ingesting fish containing infective larvae.

Acknowledgements

I am grateful to Dr. James H. L. Mills, College of Veterinary Medicine, University of Saskatchewan, Saskatoon, Canada, for providing some of the histopathological interpretations and figures given in this paper while he was a member of the Department of Animal Diseases, University of Connecticut.

LITERATURE CITED

1. CHENG, T. C. 1970. *Symbiosis*. Pegasus, N.Y. 250 p.
2. DICKENSON, P. 1951. Stomach contents of New Zealand inland shags. Aust. J. Mar. and Freshwater Res. 2: 245-253.

3. HUIZINGA, H. W. 1966. Comparative studies on the life cycle and tissue invasion of two species of *Contracaecum* from piscivorous birds. Unpublished doctoral dissertation, Univ. Conn., Storrs, 97 p.
4. HUIZINGA, H. W. 1966. Studies on the life cycle and development of *Contracaecum spiculigerum* (Rudolphi, 1809) (Ascaroidea: Heterocheilidae) from marine piscivorous birds. J. Elisha Mitchell Sci. Soc. 82: 181-195.
5. HUIZINGA, H. W. 1967. The life cycle of *Contracaecum multipapillatum* (von Drasche, 1882) Lucker, 1941 (Nematoda: Heterocheilidae). J. Parasit. 53: 368-375.
6. LUCKER, J. J. 1941. A redescription of *Contracaecum multipapillatum* (von Drasche, 1882) (Nematoda: Anisakinae). J. Parasit. 27: 505-512.
7. OGLESBY, L. C. 1960. Heavy nematode infestation of white pelican. The Auk. 79: 354.
8. OWRE, O. T. 1962. Nematodes in birds of the Order Pelicaniformes. The Auk. 79: 114.
9. PENNER, L. R. 1941. The commissary of the zoo—parasitic problems. Zoonoos. 13: 7.
10. VAN THIEL, P. H., F. C. KUIPERS, and R. T. ROSKAM. 1960. A nematode parasitic to herring causing acute abdominal syndromes in man. Trop. Geograph. Med. 2: 97-113.
11. VIK, R. 1964. Penetration of stomach wall by anisakis-type larvae in porpoises. Canad. J. Zool. 42: 513.
12. YAMAGUTI, S. 1961. Systema Helminthum. Vol. III. The Nematodes of Vertebrates. Parts I and II. Interscience Pub., Inc. N.Y. 1251 p.

Received for publication March 17, 1971
