

CASEOUS LYMPHADENITIS IN PRONGHORNS (*Antilocapra americana*)

Authors: CLARK, KEITH A., ROBINSON, R. M., WEISHUHN, L. L.,
LITTON, G. W., and MARBURGER, R. G.

Source: Journal of Wildlife Diseases, 8(1) : 67-71

Published By: Wildlife Disease Association

URL: <https://doi.org/10.7589/0090-3558-8.1.67>

BioOne Complete (complete.BioOne.org) is a full-text database of 200 subscribed and open-access titles in the biological, ecological, and environmental sciences published by nonprofit societies, associations, museums, institutions, and presses.

Your use of this PDF, the BioOne Complete website, and all posted and associated content indicates your acceptance of BioOne's Terms of Use, available at www.bioone.org/terms-of-use.

Usage of BioOne Complete content is strictly limited to personal, educational, and non - commercial use. Commercial inquiries or rights and permissions requests should be directed to the individual publisher as copyright holder.

BioOne sees sustainable scholarly publishing as an inherently collaborative enterprise connecting authors, nonprofit publishers, academic institutions, research libraries, and research funders in the common goal of maximizing access to critical research.

CASEOUS LYMPHADENITIS IN PRONGHORNS (*Antilocapra americana*)

KEITH A. CLARK, R. M. ROBINSON, and L. L. WEISHUHN,
Department of Veterinary Pathology, Texas A&M University

G. W. LITTON and R. G. MARBURGER
Texas Parks & Wildlife Department

Abstract: Caseous lymphadenitis was diagnosed in two mature pronghorns on the basis of gross and histological examinations. Evidence suggests that the infection was acquired from domestic sheep, which had formerly occupied the same range.

Caseous lymphadenitis is the name usually given to *Corynebacterium ovis* infections.^{6,11,15,16,21,25} Domestic sheep are the most commonly affected animals^{2,6,8,9,15,16,21} where infection usually results from contamination of shearing wounds^{2,15,21} and is usually characterized by abscessed lymph nodes with occasional extension via the lymphatics to visceral organs.^{7,8,15} It is also reported to have caused arthritis,¹⁷ and hemolytic icterus²² in specific outbreaks in sheep. This infection less frequently affects cattle (where it is usually a wound infection),^{1,6,16,21} horses,^{9,12,13,20,26} mule deer (*Odocoileus hemionus*),^{10,11} and possibly rhinoceroses.²¹ Honess describes focal hepatic necrosis in two antelope fawns associated with an unidentified species of *Corynebacterium*.¹¹

This infection has been at various times (and in various species) called Priesz-Nocard Disease,^{20,21} caseous lymphadenitis, ulcerative lymphangitis^{9,21,26} or pseudotuberculosis.^{8,10} The organism has also been known as *Corynebacterium pseudotuberculosis*,^{12,18} and the bacillus of Priesz-Nocard.^{1,2,9} The characteristic structure of a caseous core surrounded by concentric lamellations of fibrous tissue is a distinguishing feature and occurs in these lesions in any affected organ.^{8,15}

Most infections are localized in lymphatics but may become generalized, affecting visceral organs. When fatalities occur, they are usually the result of large pleuro-pulmonary abscesses.^{8,15}

Infection is associated with soil contaminated with the bacteria; the exact source of contamination is questionable, but cultures from soil with a high content of sheep feces frequently yield *C. ovis*.^{2,23} The organism has been cultivated on sterile sheep feces⁸ and can remain viable in pus trapped in wool.²¹ There are many different strains of this species,^{4,5} and these vary in their ability to produce toxin, but all strains are toxigenic.⁵

This infection is very common in sheep and deer in the western U.S.A. and Canada.^{16,25} Its prevalence and effects in pronghorn herds, however, is unknown at this time.

HISTORY

In 1970, Texas Parks and Wildlife Department biologists reported that some herds of pronghorn in western Texas were not increasing in total numbers, even though normal fawn production apparently occurred. Large numbers of newborn animals were seen during the

Contribution of a cooperative project between the Texas Parks and Wildlife Department and the Department of Veterinary Pathology, College of Veterinary Medicine, and the Texas Agricultural Experiment Station, Texas A&M University supported by Texas Pittman-Robertson Project W-93-R.

spring and summer, but the annual censuses did not show the expected increases in total herd size. Reports from hunters and biologists indicated that many animals were observed each hunting season with pleural adhesions. An investigation was initiated in the spring of 1970 to attempt to determine what disease process, if any, was responsible for the poor herd reproductive performance. This question is still unanswered, and further studies are presently being conducted. This report describes an incidental finding of caseous lymphadenitis in two individuals.

MATERIALS AND METHODS

In August 1970, twelve pronghorns were collected from three ranches in different parts of western Texas. These animals were shot from the herd at random. From the first ranch, where reproduction was apparently satisfactory, three animals (one adult female and two fawns) were taken. From the second, where reproduction was less than optimum, three fawns were collected. On the third ranch, which consisted of over 97,000 acres, reproduction was considered to be unsatisfactory. Until about one year previously, this ranch had been heavily stocked with sheep, which had since been sold. Six animals were collected from this ranch, including three fawns, one female approximately 1½ years old, and two adult males, both over 2 years old. All fawns were approximately 4 months old. All twelve animals were examined by detailed necropsy and tissues were preserved for microscopic examination.

RESULTS

No gross or microscopic lesions were observed in any of the animals collected from the first two ranches. Two adult males from the third ranch had numerous hard yellow nodules of various size on both surfaces of the liver and scattered through the hepatic parenchyma (Figure 1). Both were fat, and appeared normal before death. *Haemonchus contortus* infestations were present in all three adult animals.

Microscopically, the nodules were areas of caseous necrosis surrounded by concentric rings of dense fibrous tissue were lymphocytes, macrophages, and immature fibroblasts at the periphery. Many nodules had mineralized centers (Figure 2). No organisms were demonstrable in tissue sections, either by routine or special staining techniques, including Gram, acid-fast and Gridley stains.

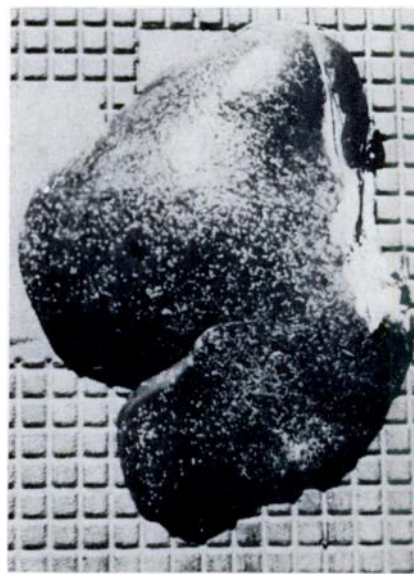


FIGURE 1. Gross appearance of pronghorn liver affected with caseous lymphadenitis.

DISCUSSION

Cultural confirmation is desirable; however, a diagnosis of caseous lymphadenitis is justified on the basis of characteristic lesions. The prevalence and effect of this condition in herds of pronghorn remains undetermined, but there can be little doubt as to their susceptibility, and the opportunity for exposure when they share a pasture with domestic sheep. This is uniquely demonstrated by the fact that this infection was only found in animals old enough to have been pastured with sheep. Definite proof is lacking, but this

is probably an example of an infection being transmitted from a domestic species to a wild one; it is less likely that the reverse could be possible, due to the low population density of the pronghorns,

and the fact that even though infected pronghorns were present, no new infections were detected in those too young to have been directly exposed to domestic sheep.

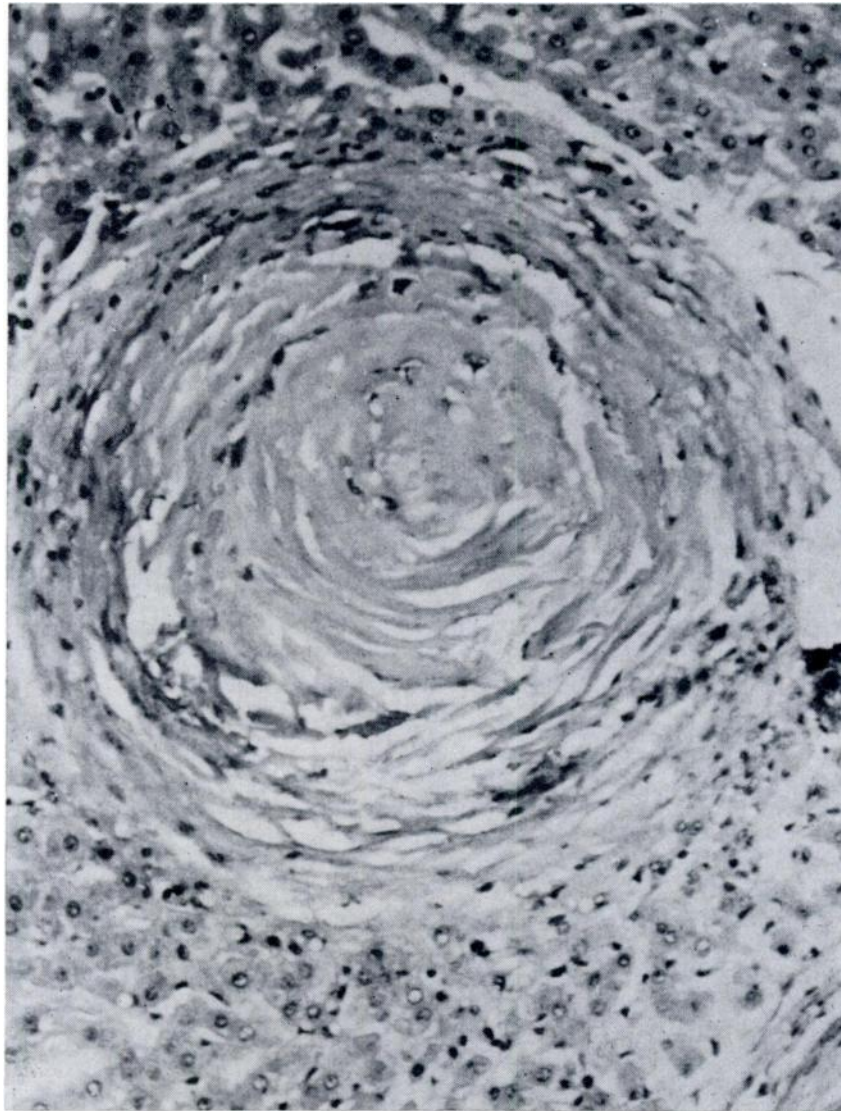


FIGURE 2. Caseous lymphadenitis, hepatic lesion. Concentric lamellations of fibrous tissue with lymphocytes and macrophages at the periphery. H&E X 200.

LITERATURE CITED

1. BULL, L. B. 1933. Infection of a cow with the Preisz-Nocard Bacillus. Aust. Vet. J. 9: 93-95.
2. BULL, L. B., and C. G. DICKINSON. 1933. Studies on infection by, and resistance to, the Preisz-Nocard Bacillus. III. Some preliminary observations on experimental and natural infections of the sheep. Aust. Vet. J. 9: 82-92.
3. CARNE, H. R. 1932. Jr. Council Sc. Ind. Res. 5: 98. Cited by Bull and Dickinson.
4. CARNE, H. R. 1939. A bacteriological study of 134 strains of *Corynebacterium ovis*. J. Path. Bact. 49: 313-328.
5. CARNE, H. R. 1940. The toxin of *Corynebacterium ovis*. J. Path. Bact. 51: 199-212.
6. CARNE, H. R., and R. C. CRAMP. 1932. The cause of caseous lymphadenitis of sheep in Australia. Aust. Vet. J. 8: 28-33.
7. CARNE, H. R., N. WICKHAM, and J. C. KATER. 1956. A toxic lipid from the surface of *Corynebacterium ovis*. Nature, Lond. 178: 701-702.
8. GILRUTH, J. A. 1902. Pseudo-tuberculosis in sheep. J. Comp. Path. 15: 324-344.
9. HALL, I. C., and R. V. STONE. 1916. The diptheroid bacillus of Preisz-Nocard from equine, bovine, and ovine abscesses. Ulcerative lymphangitis and caseous lymphadenitis. J. Inf. Dis. 18: 195-208.
10. HAMMERSLAND, H., and E. M. JONESCHILD. 1937. Pseudotuberculosis of deer. J.A.V.M.A. 91: 186-192.
11. HONESS, R. F., and K. B. WINTER. 1956. *Diseases of Wildlife in Wyoming*. Wyoming Game and Fish Commission Bulletin 9. 279 pp.
12. HUGHES, J. P., and E. L. BIBERSTEIN. 1959. Chronic equine abscesses associated with *Corynebacterium pseudotuberculosis*. J. Amer. Vet. Med. Assoc. 135: 559-562.
13. HUGHES, J. P., E. L. BIBERSTEIN, and W. P. C. RICHARDS. 1962. Two cases of generalized *Corynebacterium pseudotuberculosis* infection in mares. Cornell Vet. 52: 51-62.
14. HUMPHREYS, F. A., and R. J. GIBBONS. 1942. Some observations on Corynebacterial infections with particular reference to their occurrence in mule deer, *Odocoileus hemionus*, in British Columbia. Canad. J. Comp. Med. 6: 35-45.
15. JUBB, K. V. F., and P. C. KENNEDY. 1963. *Pathology of Domestic Animals*. Vol. 1. Academic Press, New York and London.
16. MADDY, K. T. 1953. Caseous lymphadenitis of sheep. J. Amer. Vet. Med. Assoc. 122: 257-259.
17. MARSH, H. 1947. *Corynebacterium ovis* associated with an arthritis in lambs. Am. J. Vet. Res. 8: 294-298.
18. McGRATH, T. T. 1929. On the presence of the bacillus of Preisz-Nocard in infected shear-cut wounds in sheep. Aust. Vet. J. 5: 148-149.
19. MERCHANT, I. A. 1935. A study of the Corynebacteria associated with diseases of domestic animals. J. Bact. 30: 95-116.
20. MITCHELL, C. A., and R. V. L. WALKER. 1944. Preisz-Nocard Disease. Study of a small outbreak occurring among horses. Canad. J. Comp. Med. 8: 3-10.
21. PURCHASE, H. A. 1944. An outbreak of ulcerative lymphangitis in cattle caused by *Corynebacterium ovis*. J. Comp. Path. 54: 238-247.

22. ROBINSON, E. M. 1928. Preliminary investigations into an icterus of sheep caused by a bacterium (bacterial icterus). 13th & 14th Onderstepoort Reports. pp. 733-741.
23. SEDDON, H. R., H. G. BELSCHNER, A. L. ROSE, and C. BLUMER. 1929. Further observations on the method of infection in caseous lymphadenitis of sheep. Aust. Vet. J. 5: 139-148.
24. EGHETTI, L., and F. D. MCKENNEY. 1941. Caseous lymphadenitis of deer (*Odocoileus hemionus*) in Washington. J. Amer. Vet. Med. Assoc. 98: 129-131.
25. WATSON, E. A. 1920. Ulcerative lymphangitis or "Preisz-Nocard Disease" of horses, with special reference to immune sera, toxin, and antitoxin. J. Amer. Vet. Med. Assoc. 57: 257-269.

Received for publication September 7, 1971
