

## **DUAL INFECTION OF AN AFRICAN FISH EAGLE WITH ACID-FAST BACILLI AND AN *Aspergillus* SP.**

Authors: KALINER, G., and COOPER, J. E.

Source: Journal of Wildlife Diseases, 9(1) : 51-55

Published By: Wildlife Disease Association

URL: <https://doi.org/10.7589/0090-3558-9.1.51>

---

The BioOne Digital Library (<https://bioone.org/>) provides worldwide distribution for more than 580 journals and eBooks from BioOne's community of over 150 nonprofit societies, research institutions, and university presses in the biological, ecological, and environmental sciences. The BioOne Digital Library encompasses the flagship aggregation BioOne Complete (<https://bioone.org/subscribe>), the BioOne Complete Archive (<https://bioone.org/archive>), and the BioOne eBooks program offerings ESA eBook Collection (<https://bioone.org/esa-ebooks>) and CSIRO Publishing BioSelect Collection (<https://bioone.org/csiro-ebooks>).

Your use of this PDF, the BioOne Digital Library, and all posted and associated content indicates your acceptance of BioOne's Terms of Use, available at [www.bioone.org/terms-of-use](http://www.bioone.org/terms-of-use).

Usage of BioOne Digital Library content is strictly limited to personal, educational, and non-commercial use. Commercial inquiries or rights and permissions requests should be directed to the individual publisher as copyright holder.

---

BioOne is an innovative nonprofit that sees sustainable scholarly publishing as an inherently collaborative enterprise connecting authors, nonprofit publishers, academic institutions, research libraries, and research funders in the common goal of maximizing access to critical research.

## DUAL INFECTION OF AN AFRICAN FISH EAGLE WITH ACID-FAST BACILLI AND AN *Aspergillus* SP.

G. KALINER and J. E. COOPER\*, Veterinary Research Laboratory, P.O. Kabete, Kenya

**Abstract:** Clinical, post-mortem and histological findings are described for an African fish eagle (*Haliaeetus vocifer*), which was naturally infected with acid-fast organisms. In addition to this infection, there was an invasion of the air sacs and, to a lesser extent the lungs, by an *Aspergillus* sp. The predominant clinical sign was dyspnoea and there were acid-fast organisms in lesions in the liver and kidney in addition to the respiratory tract.

### INTRODUCTION

Acid-fast infections in birds, usually with acid-fast *Mycobacterium* sp., have been reported frequently from domestic poultry.<sup>2,6</sup> In addition, tuberculosis due to *Mycobacterium* has been reported from a number of other species of birds including both captive and wild birds of prey.<sup>2,3,8,11</sup> In Kenya, avian tuberculosis has been diagnosed in poultry<sup>13</sup> but no records have been found of its occurrence in wild birds.

In this paper we wish to record granulomatous lesions associated with acid-fast organisms, which showed a number of features typical of avian tuberculosis, in a young African fish eagle. There was concurrent infection with an *Aspergillus* species.

### CLINICAL HISTORY

The specimen, an immature African fish eagle, was found in the Lake Nakuru National Park on 7th June 1971. It was unable to fly and in poor physical condition.

The bird was kept at the Baharini Wildlife Sanctuary in Nakuru and was fed on fish, beef, chicken heads and, occasionally, whole rats.

At the end of August, it was found to be thinner and, although still feeding

well, it showed dyspnoea on slight exertion. There was no response following a 5 day course of oxytetracycline (250 mg daily).

### CLINICAL FINDINGS

On 20th September the bird was very thin and weighed only 2160 g. Its feathers were dry and ragged and a number of lice (Mallophaga) were present. The eagle showed severe dyspnoea, opening its bill and raising its body at each exhalation. The respiratory rate was 32 per minute. Auscultation revealed respiratory râles over all of the air sacs and the lungs. On palpation fish bones were detected in the crop. The bird was able to stand and would eat pieces of chopped fish, but became very breathless on the slightest exertion. A drop of blood was taken from the brachial vein and smears prepared; a swab of faeces and two tracheal swabs were also taken. On the basis of the clinical signs and the lack of response to broad-spectrum antibiotics, aspergillosis was tentatively diagnosed.

Attempted therapy was carried out using pimaricin.\*\* A 1.25% suspension was prepared and in the absence of a nebulizer or spray, 4 ml of this was sprayed into the trachea using a 20 ml syringe and a narrow bore needle. There were no obvious ill effects arising from the treatment.

\*ON F.C.O./O.D.A. Secondment from the A.R.C. Institute for Research on Animal Diseases, Compton, Berkshire, England.

\*\*"Pimaricin": Royal Netherlands Fermentation Industries.

On the following day, 21st September, the bird's respiration rate was 36 per minute. It was given small pieces of fish, but appeared uncomfortable and tried to regurgitate.

On the 22nd September the bird showed dysphagia. By early evening the dyspnoea was worse and a further 2 ml pimaricin was administered as a fine spray intra-nasally.

The bird was found dead early the next day.

#### POST-MORTEM FINDINGS

Externally the bird was thin and the feathers were louse-infested, particularly on the breast. Its tail feathers and primaries showed traumatic damage.

Internally, the predominant lesions were in the respiratory tract. The walls of all air sacs were thickened and opaque with some deposits of yellowish-white debris. Both lungs contained much yellowish-white caseous material which was "nodular" in appearance. There was caseous yellow debris around the base of the heart. The liver was swollen, pale and friable and the ovary small and inactive. All other organs were apparently normal.

#### LABORATORY TESTS

The two tracheal swabs and a portion of fresh lung yielded an *Aspergillus* sp. when cultured on blood agar and Saboraud's agar. The species of *Aspergillus* was not determined but morphologically it resembled *A. fumigatus*. The faecal swab yielded no significant organisms on culture. Blood smears stained with Giemsa showed no protozoal parasites nor obvious abnormalities. The lice were examined by Dr. T. Clay of the British Museum (Natural History) and identified as *Colpocephalum napiforme* Rudow, 1869 and *Degeeriella regalis castanea* (Piaget, 1890).

#### HISTOLOGY

Pieces of lung, the wall of an air sac, liver and kidney were examined. The tissue was fixed in 10% buffered formol-

saline, embedded in paraffin and stained with haematoxylin and eosin and by the methods of Giemsa, Ziehl-Neelsen, Gram, von Kossa, periodic acid-Schiff and van Gieson, and Gordon-Sweet's stain for reticulin.

#### Lung:

Necrotic foci of various sizes were found, the centres of which showed only a small amount of nuclear debris. This caseous material was surrounded by a wall of palisade-like giant cells, with large vacuoles in their cytoplasm.

The nuclei of these giant cells lay in the poles of the cells away from the area of necrosis. Outside these cells was a stratified layer of epithelioid cells adjacent to which were some multinucleated giant cells. In a few giant cells, the nuclei were of low chromatin density and were situated on the periphery of the cell and corresponded morphologically to giant cells of the Langhans' type. Single lymphocytes and granulocytes were scattered among these cells. A small number of resorptive tubercles were seen. There was no indication of encapsulation by connective tissue nor deposition of calcium. Numerous acid-fast, gram-positive bacilli were found in the cytoplasm of the epithelioid and giant cells and, to a lesser extent, in the caseous material. Hyphae were seen, associated with cellular reaction, in a small, circumscribed area of one section.

#### Air sac:

The wall of the air sac was thickened with cellular infiltration and, in some areas, invasion by hyphae.

#### Liver:

Numerous small tubercle-like lesions were present. These were composed of epithelioid and giant cells and interwoven by a network of argyrophilic fibrils. Giant cells in the liver were mainly of the foreign body type, but there were also some of the Langhans' type. Some tubercles were surrounded by fibrocytes and fine collagenous fibres (Fig. 1), others by lymphocytes and granulocytes.

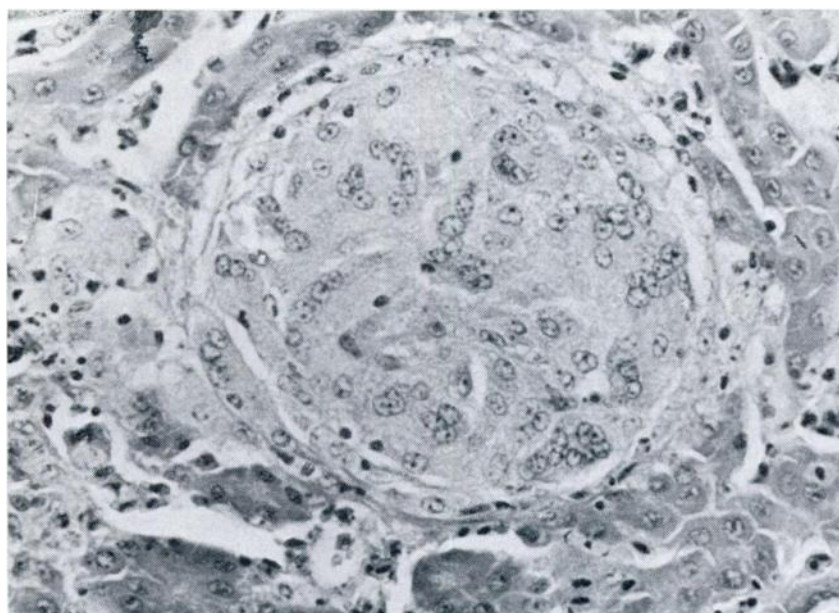


FIG. 1. Liver, small tubercle surrounded by fibrocytes and fine collagenous fibres. Van Gieson, x 40.

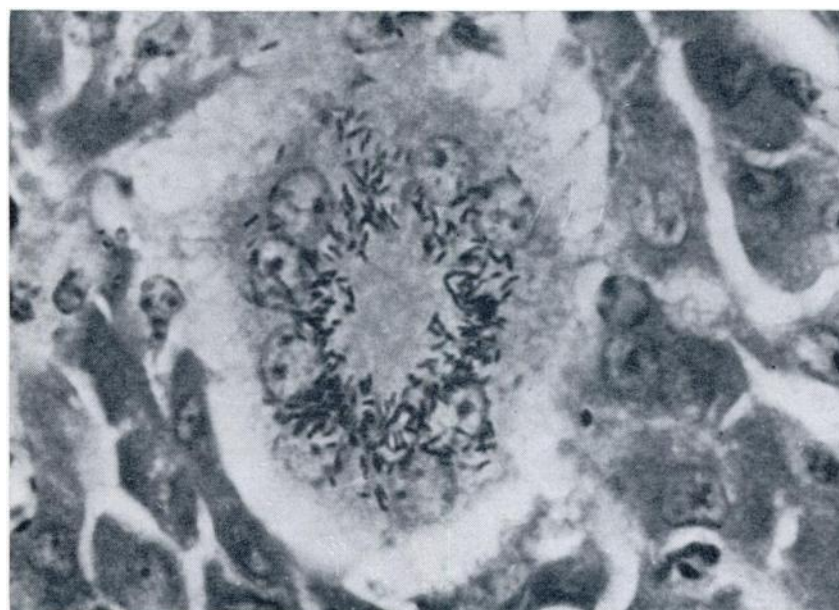


FIG. 2. Liver. Langhans' cell with acid-fast bacilli in the vicinity of the nuclei. Ziehl-Neelsen x 1000.

Small isolated foci of coagulative necrosis were seen on the periphery of a few tubercles. Calcification was not observed. The tubercles frequently lay in the adventitial zone of larger blood vessels, in the vicinity of which myeloblast-like cells could be found. Numerous acid-fast, gram-positive bacilli were seen in the cytoplasm of the granuloma cells. Within the Langhans' giant cells, the bacilli were situated in a rosette-like formation in the neighbourhood of the nuclei (Fig. 2). Some von Kupffer's cells were enlarged and these also contained acid-fast bacilli. Despite careful examination, vacuoles indicative of fatty infiltration could not be found in the parenchymal cells.

#### Kidney:

One small tubercle containing acid-fast bacilli was seen.

#### DISCUSSION

Material had not been stored and therefore, unfortunately, culture of the acid-fast organisms could not be carried out. However, from the morphological appearance of the organisms and the reaction they elicited, they were considered to be *Mycobacterium* sp. Mycobacterial infections in birds are usually contracted by ingestion,<sup>7</sup> and repeated intake of large numbers of mycobacteria are necessary to establish the infection.<sup>1</sup>

It is unwise to equate pathogenesis in domesticated birds with other species but in tuberculosis of the chicken the liver is macroscopically damaged in 95.1% of cases, the intestine in 72.5% and the lung in 41.3%. Lesions may therefore sometimes be absent in the intestine, but are almost invariably present in the liver.<sup>12</sup> Following Eber,<sup>9</sup> it is probable that the lesions in the lung of the fish eagle were mycobacterial and more advanced than

those seen in the liver, which were composed only of epithelioid and giant cells. In view of these findings, an inhalation route of infection cannot be excluded in this bird of prey.

The source of infection is obscure. The bird was in captivity for nearly 3 months before clinical signs were noted, but the course of tuberculosis in birds may be very protracted.<sup>8</sup> Wild fish eagles feed predominantly on fish, but also take carrion and such items of food could have been the source of infection, especially since atypical mycobacteria have been recorded from fish and amphibia in East Africa.<sup>15,16</sup> Gratzl and Köhler<sup>8</sup> describe atypical mycobacteria as being of low or no pathogenicity to poultry but one cannot assume that this applies to other avian species. Other possible sources of infection which cannot be excluded are the chicken heads, which originated from a local market and comprised part of the eagle's diet, or human contacts, since human tuberculosis is common in Kenya.<sup>10</sup> Unfortunately, the lung material of the eagle could not be cultured for mycobacteria and hence no further identification or typing of the acid-fast organisms, which might have offered information on their source, was possible.

In view of the nodular appearance of the lesions in the lung, possible differential diagnoses are aspergillosis, salmonellosis and coligranulomatosis.<sup>7,8</sup> Nodules can also be caused by parasites such as *Tetrathyridium* sp., *Cytodites nudus*, *Laminosioptes cysticola* and visceral larva migrans.<sup>9</sup>

An interesting feature of this case was the finding of both lesions caused by acid-fast bacilli and aspergillosis in the same bird. Aspergillosis is a common cause of mortality in captive birds of prey<sup>4,11</sup> and cases of concurrent aspergillosis and tuberculosis have been recorded previously by one of us (Cooper, unpublished) and elsewhere.<sup>11</sup>

#### Acknowledgements

We should like to thank Messrs. L. Frank and J. Hopcraft of the Baharini Wildlife Sanctuary who submitted the material and Dr. T. Clay of the British Museum (Natural History) for identifying the lice. This paper is published by permission of the Director of Veterinary Services, Kenya.

## LITERATURE CITED

1. BELLER, K. 1930. Geflügeltuberculose. Dtsch. tierärztl. Wschr. 38: 453-456.
2. BIESTER, H. E., and L. H. SCHWARTE. 1965. *Diseases of Poultry*. 5th ed. The Iowa State University Press, Ames, Iowa. 374-404.
3. COOPER, J. E. 1968. Tuberculosis in birds of prey. Vet. Rec. 82: 61.
4. ———. 1969. Some diseases of birds of prey. Vet. Rec. 84: 454-457.
5. EBER, A. 1924. Die Tuberkulose des Hausgeflügels. Z. Infektkrankh. Parasit. Krankh. Hyg. 25: 145-175.
6. EBER, R. 1925. Beitrag zur Histologie und Histogenese der spontanen Lebertuberkulose des Huhnes. Z. Infektkrankh. Parasit. Krankh. Hyg. 28: 130-149.
7. FRITZSCHE, K., and E. GERRIETS. 1962. Geflügelkrankheiten. 2. Auflg. Paul Parey, Berlin and Hamburg. 277-286.
8. GRATZL, E., and H. KOHLER. 1968. Spezielle Pathologie und Therapie der Geflügelkrankheiten. Ferdinand Enke, Stuttgart. 567-603.
9. KALINER, G. 1972. Vorkommen und Differentialdiagnose der Tetrathyridiose beim Haushuhn. Zbl. Vet. Med. B 19: 136-143.
10. KENT, P. W. 1971. The pattern of tuberculosis in East Africa. E. Afr. Med. J. 48: 450-455.
11. KEYMER, I. F. 1972. Diseases of birds of prey. Vet. Rec. 90: 579-594.
12. PALLASKE, G. 1967. Spezifische Entzündungen der Leber. In: E. Joest, *Handbuch der speziellen pathologischen Anatomie der Haustiere*. Edited by J. Dobberstein, G. Pallaske and H. Stünzi. 3rd ed., vol. 6, Paul Parey, Berlin and Hamburg. 159-178.
13. ANNUAL REPORT. 1966. Veterinary Department, Kenya. Government Printer. 44.
14. STEHLE, S. 1965. Krankheiten bei Greifvögel (Accipitres) und bei Eulen (Striges) mit Ausnahme der parasitären Erkrankungen. Inaug.-Diss., Univ. Hannover.
15. WADDINGTON, F. G. 1965. Report to the government of Kenya on a tuberculin test survey of cattle in Kenya. Report No. 2011, Food and Agriculture Organization of the United Nations, Rome.
16. WOODFORD, M. H. 1971. Tuberculosis in the african buffalo (*Syncerus caffer*) in the Queen Elizabeth National Park, Uganda. Inaug. Diss., Univ. Zürich.

Received for publication June 28, 1972