

A CASE OF ORCHITIS CAUSED BY *Brucella abortus* IN THE AFRICAN BUFFALO

Authors: KALINER, G., and STAAK, C.

Source: Journal of Wildlife Diseases, 9(3) : 251-253

Published By: Wildlife Disease Association

URL: <https://doi.org/10.7589/0090-3558-9.3.251>

The BioOne Digital Library (<https://bioone.org/>) provides worldwide distribution for more than 580 journals and eBooks from BioOne's community of over 150 nonprofit societies, research institutions, and university presses in the biological, ecological, and environmental sciences. The BioOne Digital Library encompasses the flagship aggregation BioOne Complete (<https://bioone.org/subscribe>), the BioOne Complete Archive (<https://bioone.org/archive>), and the BioOne eBooks program offerings ESA eBook Collection (<https://bioone.org/esa-ebooks>) and CSIRO Publishing BioSelect Collection (<https://bioone.org/csiro-ebooks>).

Your use of this PDF, the BioOne Digital Library, and all posted and associated content indicates your acceptance of BioOne's Terms of Use, available at www.bioone.org/terms-of-use.

Usage of BioOne Digital Library content is strictly limited to personal, educational, and non-commercial use. Commercial inquiries or rights and permissions requests should be directed to the individual publisher as copyright holder.

BioOne is an innovative nonprofit that sees sustainable scholarly publishing as an inherently collaborative enterprise connecting authors, nonprofit publishers, academic institutions, research libraries, and research funders in the common goal of maximizing access to critical research.

A CASE OF ORCHITIS CAUSED BY *Brucella abortus* IN THE AFRICAN BUFFALO

G. KALINER¹ and C. STAAK²

Abstract: Pathological changes are described in the testicle of a *Brucella*-infected, free-living African buffalo (*Syncerus caffer*).

INTRODUCTION

Little is known about brucellosis and its pathology in East African game animals, since it is difficult to isolate the causative organism under field laboratory conditions. The detection of antibodies does not allow the classification as "negative", "doubtful", and "positive" without a knowledge of the minimum titre which correlates with infection in the species in question. *Brucella abortus* biotype 3 was isolated from the inflamed testicle of a buffalo with an agglutination titre of 1:20 (32.5 I.U.).¹ This animal was shot in southern Tanzania. The same biotype of *Brucella abortus* was found by Staak² in cattle in Tanzania.

The pathological findings in a *Brucella*-infected buffalo are described.

METHODS AND MATERIALS

Forty-six buffalos were shot in August 1969 during a game cropping exercise at Mbalageti in northern Tanzania. Organs and blood sera were collected at post mortem examination. Sera were tested for *Brucella* agglutinating and complement-fixing antibodies according to the techniques of Alton and Jones.¹

Supramammary lymph nodes, inguinal lymph nodes and testicles, respectively, were ground in sterile nutrient broth and suspensions of these organs were injected subcutaneously into individual

guinea pigs. The same material was cultured on Bacto *Brucella* Agar (Difco Laboratories, Detroit, Michigan) and incubated aerobically and under 10% CO₂ atmosphere for 3 days.

Tissue taken for histological examination was fixed in 10% formalin, embedded in paraffin wax and stained with hematoxylin-eosin, Gordon-Sweet's stain for reticulin, Verhoeff's stain for elastica, and by the methods of van Gieson, von Kossa, and Giesma; also, Nicolle's stain for bacteria and Jacob's stain⁴ for *Brucella* were applied.

RESULTS

Of the 46 buffalos cropped, seven had agglutination titres to *Brucella* of 1:20 (31.25 I.U.) or higher. Six of these reactors did not show macroscopic lesions, and were bacteriologically negative. *Brucella abortus* biotype 3 was isolated from the testicle of one 4 year-old buffalo. The serum of this animal had titres of 1:40 by both the agglutination (62.5 I.U.) and the complement fixation tests.

GROSS FINDINGS

The left testicle from which the *Brucella* organism was isolated was enlarged (16.5 x 6.5 cm) as compared with the right ((14.0 x 5.5 cm). Large necrotic foci about 1.5 x 0.7 cm were found in

¹ Veterinary Research Laboratory, P.O. Kabete, Kenya.

² Veterinary Investigation Centre Arusha, P.O. Box 3084, Arusha, Tanzania.

³ "Brucellosis Reservoir in almost Uncontrollable Areas"; Paper presented to the Specialist Committee on Brucellosis and Tuberculosis, E.A.V.R.O. Muguga, Kenya, 17th April 1972.

the parenchyma near the tunica albuginea of the infected testicle. No macroscopic lesions were seen in the epididymis.

HISTOPATHOLOGIC FINDINGS

The intertubular outlines of connective tissue were broad and showed fibrosis in some places. Spermiogenesis was present in some tubules but was apparently disturbed in others. Numerous tubules were empty and were lined by one layer of epithelium of variable height. Others were filled by pyknotic cells or by filamentous or homogenous masses. Rarely, the necrotic epithelium showed demarcation from the lumen. In some areas, the basement membrane was undulating, and around some tubules it was markedly swollen (Fig. 1). In other areas, histiocytes and plasma cells were found adjacent to the tubules. Numerous pyknotic cells were lying outside the basement membrane of a few seminiferous tubules. The morphology of these cells was similar to those present in the lumen of other seminiferous tubules. Granulomata of varying size and necrotic foci surrounded by lymphocytes and histiocytes were seen in the interstitium of the testicle. The

granulomata showed calcification and minimal encapsulation. The cell types consisted of lymphocytes, histiocytes, epitheloid and multinucleated giant cells. The majority of the giant cells were of Langhans' type. The endoplasm of some of the giant cells was granular or vacuolated or contained flakes of calcium of variable size. Giant cells of the foreign body type were found in small numbers. In some of the granulomata there were small, thin-walled blood vessels. Large necrotic areas were divided by fine septae of connective tissue. In these compartments the contours of seminiferous tubules filled with cell debris were visible. In the zones of cellular reaction to the necrotic foci, there was coagulation necrosis of the tubules, some of which contained large calcified concretions. Fibrosis of the intima was often found in larger arteries. A few of the smaller arteries had thickened walls or oedema of the media, with increased cells of undetermined type which almost occluded the lumen. Some thin-walled small vessels, situated in the tunica albuginea, showed perivascular or juxta-vascular infiltration of lymphocytes and histiocytes.

No *Brucella* organisms were seen in the sections examined.

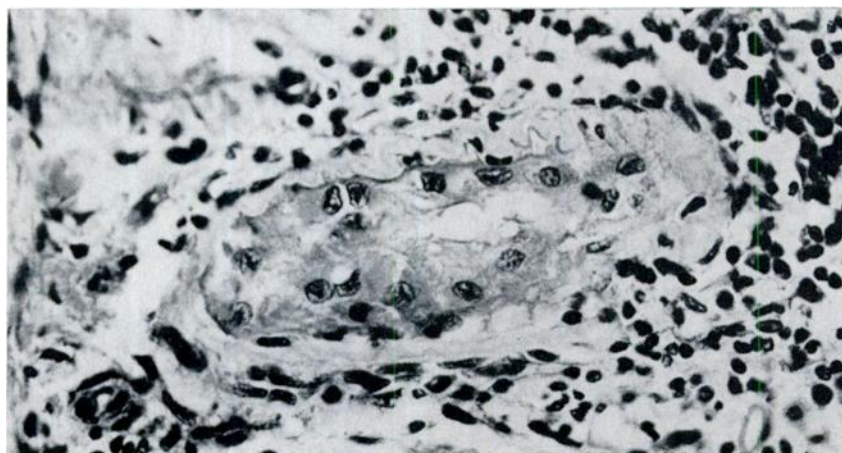


FIGURE 1. Seminiferous tubule with swollen basement membrane. Adjacent to the tubule are lympho-histiocytic cells. H. & E., 250 x.

DISCUSSION

The changes found in the testicle of this buffalo are similar to those described for *Brucella*-orchitis in the domestic bull. In cattle, necrotizing inflammation and suppurative abscessation can be found,³ sometimes with calcification.⁷ In protracted brucellosis, miliary tubercle-like granulomata develop, in which Langhans' giant cells may be present.⁶ Later, degeneration of the seminiferous tubules and fibrosis of the testicle occurs.² *Brucella* may be demonstrated histologically

only in acute cases.⁶ In both buffalos, the one shot in southern Tanzania¹¹ and in this case, only unilateral changes of the testicle were seen macroscopically. Unilateral *Brucella*-orchitis is also seen in cattle^{5,7,9,10,12} in which it may cause sterility,⁵ even if the other testicle does not show changes on histological examination.⁹

From the pathological picture described, the lesions seemed to have been chronic and might have caused sterility in the affected animal.

Acknowledgement

This paper is published by kind permission of the Director of Veterinary Services, Kenya.

LITERATURE CITED

1. ALTON, G. G. and L. M. JONES. 1967. *Laboratory Techniques in Brucellosis*. WHO Monograph Series No. 55, Geneva.
2. COHRS, P. 1967. In: *Textbook of the Special Pathological Anatomy of Domestic Animals*. Nieberle and Cohrs, ed. Pergamon Press, Oxford.
3. JACOB, K. 1964. Das brucelloese Granulom. *Path. vet.* 1: 41-63.
4. JACOB, K. 1968. Zur faerberischen Darstellung der Brucellen im Gewebeschnitt. *Berl. Muench. tierarztl. Wschr.* 81: 29-30.
5. JUBB, K. V. F. and P. C. KENNEDY. 1970. *Pathology of Domestic Animals*, Vol. 1. 2nd ed. Academic Press, New York and London.
6. KOENIG, H. 1971. Hoden und Nebenhoden. In: *Handbuch der speziellen pathologischen Anatomie der Haustiere*. Vol. 4 E. Joest, 3rd ed. Paul Parey, Berlin and Hamburg.
7. MARCIS, A. 1928. Ueber die durch Bang'sche Abortusbazillen verursachte Erkrankung der maennlichen Geschlechtsorgane. *Dtsch. tierarztl. Wschr.* 36: 67-72.
8. PALLASKE, G. 1960. *Pathologische Histologie*. Ed. Gustav Fischer, Jena.
9. RICHTER, J. 1932. Ueber die Sterilitaet bei Bullen. *Berl. tierarztl. Wschr.* 48: 49-54 and 65-70.
10. RICHTER, J. 1936. Sterilitaet maennlicher Tiere. *Berl. tierarztl. Wschr.* 52: 741-748 and 757-762.
11. STAAK, C., R. SACHS and C. M. GROOCKOCK. 1968. Bruzellose beim afrikanischen Bueffel (*syncerus caffer*) in Tanzania. *Vet. med. Nachr.* 68: 245-249.
12. WITTE, J. 1930. Beitrag zur Infektion des Bullen mit Bangschen Abortusbakterien. *Arch. Wiss. prakt. Tierheilk.* 61: 128-140.

(Received for publication 2 April 1973)