

## **STAPHYLOCOCCAL INFECTION AND TOXOPLASMOSIS IN A YOUNG HARBOR SEAL \***

Authors: PELT, R. W. Van, and DIETERICH, R. A.

Source: Journal of Wildlife Diseases, 9(3) : 258-261

Published By: Wildlife Disease Association

URL: <https://doi.org/10.7589/0090-3558-9.3.258>

---

The BioOne Digital Library (<https://bioone.org/>) provides worldwide distribution for more than 580 journals and eBooks from BioOne's community of over 150 nonprofit societies, research institutions, and university presses in the biological, ecological, and environmental sciences. The BioOne Digital Library encompasses the flagship aggregation BioOne Complete (<https://bioone.org/subscribe>), the BioOne Complete Archive (<https://bioone.org/archive>), and the BioOne eBooks program offerings ESA eBook Collection (<https://bioone.org/esa-ebooks>) and CSIRO Publishing BioSelect Collection (<https://bioone.org/csiro-ebooks>).

Your use of this PDF, the BioOne Digital Library, and all posted and associated content indicates your acceptance of BioOne's Terms of Use, available at [www.bioone.org/terms-of-use](http://www.bioone.org/terms-of-use).

Usage of BioOne Digital Library content is strictly limited to personal, educational, and non-commercial use. Commercial inquiries or rights and permissions requests should be directed to the individual publisher as copyright holder.

---

BioOne is an innovative nonprofit that sees sustainable scholarly publishing as an inherently collaborative enterprise connecting authors, nonprofit publishers, academic institutions, research libraries, and research funders in the common goal of maximizing access to critical research.

## STAPHYLOCOCCAL INFECTION AND TOXOPLASMOSIS IN A YOUNG HARBOR SEAL\*

R. W. Van PELT and R. A. DIETERICH, Institute of Arctic Biology, University of Alaska,  
Fairbanks, Alaska 99701, U.S.A.

**Abstract:** Generalized subcutaneous abscessation followed by acute systemic infection occurred in a young male harbor seal (*Phoca vitulina richardii*). Clinically, infection was manifested by malaise, progressive weight loss, labored respiration, intermittent vomition, and mucohemorrhagic diarrhea. A coagulase-positive *Staphylococcus aureus* was isolated from the subcutaneous abscesses, and specimens of lung, liver, small intestine, and kidney. Microscopically, cysts and trophozoites of *Toxoplasma gondii* were found in, or adjacent to, foci of necrosis present throughout the liver parenchyma.

### INTRODUCTION

Toxoplasmosis is ubiquitous in nature with protean manifestations.<sup>5</sup> The disease is caused by an obligate intracellular protozoan, *Toxoplasma gondii*.<sup>6</sup> Its prevalence in sea mammals is poorly documented.<sup>1</sup> *T. gondii* was incriminated as the cause of death in a 10-day-old California sea lion (*Zalophus californianus*) at the Philadelphia Zoological Garden in 1947.<sup>4</sup> The diagnosis was based on microscopic examination of specimens of heart, lung, liver, and abdominal lymph nodes. Tissues from 43 other sea lions that died spontaneously were found to be free of *Toxoplasma* cysts.

This report presents the clinical course, therapeutic regimen, and pathologic findings in a young harbor seal affected with a generalized staphylococcal infection complicated by toxoplasmosis.

### CASE REPORT

A newborn, male harbor seal was captured on June 16, 1971, at Cold Bay, Alaska. The seal was approximately 1 hour old and weighed 11.5 kg at time of capture. The animal was shipped by air

to Fairbanks, Alaska, and placed in an environmental chamber maintained at 13°C. Water in the holding tank was changed twice daily.

The seal was fed a mixture of sterilized cream<sup>1</sup> that contained 30% butterfat and a multi-vitamin preparation<sup>2</sup> by stomach tube. From day 1 to day 11 the seal received 405 ml of the mixture three times a day. At 11 days of age body weight had dropped to 10.1 kg, a loss of 1.4 kg from time of capture. At 12 days of age the animal caretaker observed numerous subcutaneous wheals (1.0 cm in diameter) over most of the body. After a secondary pustular dermatitis developed, the seal was administered intramuscularly 2 ml of a preparation composed of procaine penicillin G, dihydrostreptomycin sulfate, dexamethasone, chlorpheniramine maleate, sodium citrate, procaine hydrochloride, and lecithin with 20% tricalcium phosphate.<sup>3</sup> This preparation was administered daily for the next 4 days. At 13 days of age, three smelt were homogenized and added to the cream-multi-vitamin dietary preparation. From day 17 to time of death, 5 days later, vomition occurred at intervals throughout the day.

\* This study was supported by N.I.H. Grant No. GM-10402 and N.O.A.A. Grant No. 1-36109. The authors thank Karin Preston for assistance with histologic specimens.

<sup>1</sup> Avoset, Avoset Company, Oakland, Calif., U.S.A.

<sup>2</sup> Deca-Vi-Sol, Mead Johnson Laboratories, Evansville, Ind., U.S.A.

<sup>3</sup> Azimycin, Schering Corporation, Bloomfield, N.J., U.S.A.

On day 17, a subcutaneous mass approximately 4 cm in diameter developed on the right side of the abdomen. Sero-purulent material was aspirated from the mass and a swab of its contents yielded a coagulase-positive *Staphylococcus aureus* on bacteriologic cultures. At that time 0.5 ml. of a hematinic<sup>4</sup> was administered intramuscularly. A mild bilateral conjunctivitis developed and was treated by instillation of an ophthalmic preparation composed of prednisolone, neomycin sulfate, vitamin A, riboflavin, and benzocaine hydrochloride<sup>5</sup> three times daily. Instillation of the ophthalmic ointment was continued until time of death.

The seal became progressively weaker and on day 19 body weight had dropped to 9.5 kg. On day 20, 300 mg of chloramphenicol sodium succinate<sup>6</sup> was administered intramuscularly twice daily and continued for the next 2 days. Feeding by stomach tube elicited vomiting.

On day 21, the seal was dehydrated, had profuse diarrhea, labored respiration, continued vomiting, and was too weak to hold its head up. At this time, 2 mg of flumethasone suspension<sup>7</sup> and 500 mg of chloramphenicol sodium succinate were administered intramuscularly. A balanced electrolyte solution<sup>8</sup> and water were given by stomach tube in an attempt to combat the dehydration. Treatment was continued the next day, at which time respiration became more labored with frequent periods of protracted vomiting. The seal died early the morning of the 23rd day.

#### **PATHOLOGIC FINDINGS**

The leptomeninges of the cerebrum and cerebellum were moderately congested and edematous. All lobes of both lungs were hemorrhagic, with evidence of interlobular edema and areas of consolidation that affected mainly the right diaphragmatic lobe. The liver, kidneys,

bronchial and mesenteric lymph nodes were markedly congested and edematous. The myocardium was pale and somewhat flabby. There was an acute generalized gastroenteritis and the serosal surfaces of the small and large intestines were markedly hyperemic. The gallbladder was distended with bile and its wall was opaque. There was hemorrhagic splenomegaly. Two large purulent subcutaneously located abscesses were found at necropsy. One was located in the fatty tissue over the lumbosacral region and the other in the right paralumbar fossa.

Bacteriologic cultures of specimens of lung, liver, and kidney yielded a coagulase-positive *Staphylococcus aureus*, a *Pseudomonas* sp., and an alpha-hemolytic *Streptococcus* sp. A pure culture of *Staphylococcus aureus* was isolated from both abscesses. A *Proteus* sp. and *Staphylococcus aureus* were isolated from the contents of the small intestine. All of the organisms were sensitive to chloramphenicol sodium succinate.

Microscopic examination of tissues confirmed the presence of the congestion and edema noticed at time of necropsy. The thymus was atrophied and contained relatively large numbers of Hassell's corpuscles. Pathologic changes in the lungs were characterized by an acute generalized inflammatory reaction, interlobular edema, marked alveolar hemorrhage, presence of purulent material in the bronchi and bronchioles, and poorly defined areas of necrosis. Colonies of gram-positive cocci were noticed in areas of suppuration. Most of the lung was atelectatic or consolidated, with very little functional tissue remaining.

Hepatic blood vessels were markedly congested in conjunction with generalized congestive sinusoidal dilatation and irregular areas of liver cord atrophy. Foci of necrosis were present throughout the liver parenchyma. Present in and

<sup>4</sup> Liviron Fortified, Trico Pharmaceutical Company, San Francisco, Calif., U.S.A.

<sup>5</sup> Neocaine Anesthetic Ointment, Diamond Laboratories, Des Moines, Iowa, U.S.A.

<sup>6</sup> Chloromycetin Sodium Succinate, Parke, Davis, & Company, Detroit, Mich., U.S.A.

<sup>7</sup> Anaprime (flumethasone) Suspension Veterinary, Syntex Laboratories, Inc., Palo Alto, Calif. U.S.A.

<sup>8</sup> Dilusol Plus, Diamond Laboratories, Des Moines, Iowa, U.S.A.

adjacent to necrotic foci were numerous cysts identified as those of *T. gondii* (Fig. 1). These cysts were intracytoplasmic; however, a few loose aggregates of trophozoites were occasionally observed in foci of liver necrosis. The epithelium lining the wall of the gall bladder was hyperplastic and thrown into numerous folds.

The spleen was hemorrhagic and there was no evidence of reactivity in the germinal centers of the lymphocytic follicles.

The mucosa of the stomach, small intestine, and large intestine was markedly hyperemic. The terminal portions of the intestinal villi were necrotic. Hemorrhage had occurred into the lumen of the small intestine.

Renal blood vessels were dilated and filled with blood, and there was hemorrhage in the region of the medullary rays. The medulla of the adrenal glands was hemorrhagic.

Bronchial lymph nodes were necrotic. All other lymph nodes were congested, slightly edematous, and reflected little or no lymphocytic reactivity in the germinal centers. The medullary portions of these nodes had an epithelioid appear-

ance, as denoted by the accumulation of large numbers of macrophages with abundant foamy cytoplasm. The cytoplasm of many of the macrophages contained deposits of hemosiderin and phagocytized erythrocytes, while the cytoplasm of others was vacuolated.

#### DISCUSSION

Puncture wounds, lacerations, abrasions, and abscesses are common findings in recently captured pinnipeds.<sup>11</sup> Secondary infection of such lesions can be caused by *Staphylococcus aureus*, *Streptococcus* sp., *Pseudomonas* sp., *Aeromonas* sp., *Clostridium* sp. and *Proteus mirabilis*. Staphylococcal granulomas have been reported in the harp seal (*Pagophilus groenlandicus*).<sup>12</sup> In the young male harbor seal presented in this report, secondary Staphylococcal pustular dermatitis and granulomas developed after acute generalized urticaria. Attempts to control the spread of the infection with antibiotics were unsuccessful.

Toxoplasmosis can be contracted by susceptible carnivores by the ingestion of

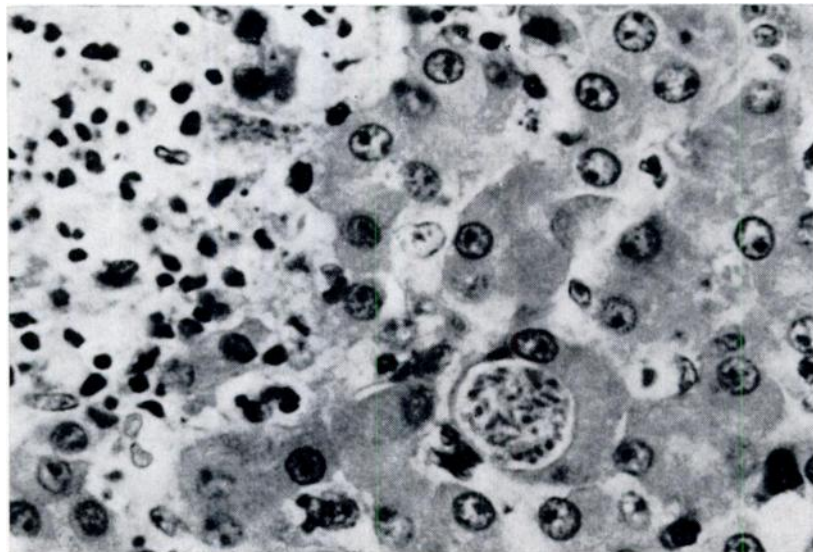


FIGURE 1. An intracytoplasmic cyst of *T. gondii* adjacent to an area of necrosis in the liver. H & E 675x.

meat or other tissues that contain the cysts of *T. gondii*.<sup>4,6</sup> However, the distribution of cysts may not be the same in all infected animals. Freezing or cooking of infected meat destroys the parasite. From day 13 to time of death, the young male harbor seal was fed animal tissue in the form of smelt that had been frozen for a prolonged period.

Ingestion of the feces of the domestic cat (*Felis catus*) that contain the sporulated oocysts of *Isospora bigemina* can result in disseminated toxoplasmosis.<sup>2</sup> The entire cycle which culminates in the shedding of oocysts in the feces occurs not only in the domestic cat but is reported to occur in the bobcat (*Lynx rufus*), mountain lion (*Felis concolor*), jaguarundi (*Felis jaguarundi*), and Asian leopard cat (*Felis bengalensis*).<sup>4,7</sup> Oocysts are remarkably resistant to environmen-

tal influences and can remain viable for prolonged periods, thus providing a means whereby noncarnivorous animals as well as carnivores can become infected.<sup>3</sup> The seal described in this report was never knowingly exposed to domestic or feral felines nor their fecal material.

In view of the present knowledge of toxoplasmosis, it would appear that the probable avenue of infection open to this seal was that of trans-placental passage of organisms from an infected dam.<sup>5,10</sup> The prevalence of toxoplasmosis among adult female harbor seals has not been determined. Proliferation of trophozoites and formation of cysts of *T. gondii* in this seal may have been exacerbated by the debilitating effects of systemic infection and by the administration of a corticosteroid preparation (dexamethasone).<sup>5,9</sup>

#### LITERATURE CITED

1. BEZOUKLADNIKOVA, N. A. 1970. Toxoplasmosis of animals not represented in the fauna of the USSR. In *Toxoplasmosis of Animals*. Edited by P. R. Fitzgerald. Translated by F. K. Plous. pp. 281-285. Univ. of Illinois, Urbana, Ill.
2. DUBEY, J. P., N. L. MILLER and J. K. FRENKEL. 1970. *Toxoplasma gondii* life cycles in cats. J. Amer. vet. med. Assoc. 157: 1767-1770.
3. DUBEY, J. P., N. L. MILLER and J. K. FRENKEL. 1970. The *Toxoplasma gondii* oocyst from cat feces. J. exp. Med. 132: 636-662.
4. FRENKEL, J. K. 1970. Pursuing toxoplasmosis. J. Infec. Dis. 122: 553-559.
5. JACOBS, L. 1970. Toxoplasmosis: Epidemiology and medical importance. J. Wildl. Dis. 6: 305-312.
6. KARLAN, M. S. and D. C. BAKER. 1972. Cervical lymphadenopathy secondary to toxoplasmosis. Laryngoscope. 82: 956-964.
7. MILLER, N. L., J. K. FRENKEL and J. P. DUBEY. 1972. Oral infections with toxoplasma cysts and oocysts in felines, other mammals, and in birds. J. Parasit. 58: 928-937.
8. RATCLIFFE, H. L. and C. B. WORTH. 1951. Toxoplasmosis of captive wild birds and mammals. Amer. J. Path. 27: 655-667.
9. ROBBINS, S. L. 1967. *Pathology*. 3rd edition, pp. 382-383. W. B. Saunders Co., Philadelphia, Pa.
10. SOULSBY, E. J. L. 1968. *Helminths, Arthropods, and Protozoa of Domestic Animals*. 6th edition, pp. 736-746. Bailliere, Tindall, and Cassell Ltd., London, England.
11. WALLACH, J. D. 1972. The management and care of pinnipeds. J. Zoo Anim. Med. 3: 45-72.
12. WILSON, T. M. and J. R. LONG. 1970. The harp seal, *Pagophilus groenlandicus* (Erxleben, 1777). XII. Staphylococcal granulomas (botryomycosis) in harp seals. J. Wildl. Dis. 6: 155-159.

(Received for publication 17 December 1972)